

Multiple non-malignant iodine uptake in a ^{131}I whole body scan of a patient with papillary thyroid carcinoma: Importance of SPECT/CT

Hamideh Abbasain¹, Farshad Emami², Farnaz Banezhad¹, Ramin Sadeghi¹

¹Nuclear Medicine Research Center, Mashhad University of Medical Science, Mashhad, Iran

²Nuclear Medicine and Molecular Imaging Department, Imam Reza International University, Mashhad, Iran

(Received 25 February 2019, Revised 27 April 2019, Accepted 30 April 2019)

ABSTRACT

After thyroidectomy in papillary thyroid carcinoma (PTC) patients, whole body radioiodine scan (WBIS) is necessary for localization of any abnormal radioiodine avid lesions. However false-positive radioiodine uptake in WBIS can be problematic. We report a 32 years old female patient with PTC. After thyroidectomy and radioiodine therapy WBIS was performed. In her post therapy WBIS, there were zones of radioiodine uptake in the chest, mediastinum, and pelvic regions. In SPECT/CT, we encountered simultaneous uptake of radioiodine in breast, thymus, adnexa and intrauterine device (IUD) site. SPECT/CT images could identify these potential false positive uptakes as benign accumulations of the tracer.

Key words: Papillary thyroid carcinoma; Whole body radioiodine scan; False-positive; SPECT/CT

Iran J Nucl Med 2020;28(1):39-42

Published: January, 2020

<http://irjnm.tums.ac.ir>

Corresponding author: Dr. Ramin Sadeghi, Nuclear Medicine Research Center, Mashhad University of Medical Science, Mashhad, Iran. E-mail: sadeghir@mums.ac.ir

INTRODUCTION

Total thyroidectomy and ¹³¹I therapy have well-known central roles in treatment of differentiated thyroid carcinoma (DTC). ¹³¹I has been used in the follow-up and management of DTC. Lymph nodes (LN) metastasis is the main region for the metastasis in patients with DTC. After the lung, bone and brain metastases, metastases to the other organs such as liver, breast, kidney are unusual [1, 2]. Identifying the metastatic sites has a significant influence on the management and prognostication of patients with DTC. ¹³¹I uptake by thyrocytes is based on sodium iodide symporter uptake (NIS). NIS is seen in some other tissues too. But most organs (for example liver) do not have NIS [1]. Single photon emission computed tomography/computed tomography (SPECT/CT) can simultaneously provide functional and anatomical information; therefore, SPECT/CT is useful for better localization of the sites of the radioiodine uptake in ¹³¹I whole body scan (WBIS) in DTC [2].

CASE PRESENTATION

A 32 years old female patient with history of PTC and total thyroidectomy with cervical lymph node dissection 2 years previously was referred to our department for whole body radioiodine scan post ¹³¹I treatment. The patient has received ¹³¹I treatment 3 times (150 mCi each time overall 450 mCi). The indication of the last ¹³¹I treatment was increase in serum thyroglobulin level. The whole body scan was performed 7 days after treatment with 150 mCi ¹³¹I using a large field of view gamma camera equipped with high energy collimator and ¹³¹I photopeak in a whole body mode (7cm/min). There were zones of tracer uptake in the mediastinum, anterior chest bilaterally, and pelvis (Figure 1).

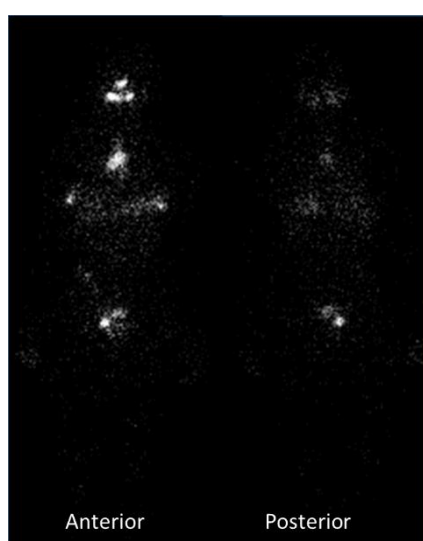


Fig 1. Whole body radioiodine scan showed zones of tracer uptake in the anterior aspects of the chest (bilaterally), mediastinum and pelvis.

Regarding the whole body image findings, SPECT/CT was performed.

In her WBIS there were zones of radioiodine uptake in the anterior aspect of the chest, mediastinum, and pelvis (Figure 1).

So SPECT/CT images from the chest, abdomen and pelvis were obtained (Figures 2, 3, 4 and 5).

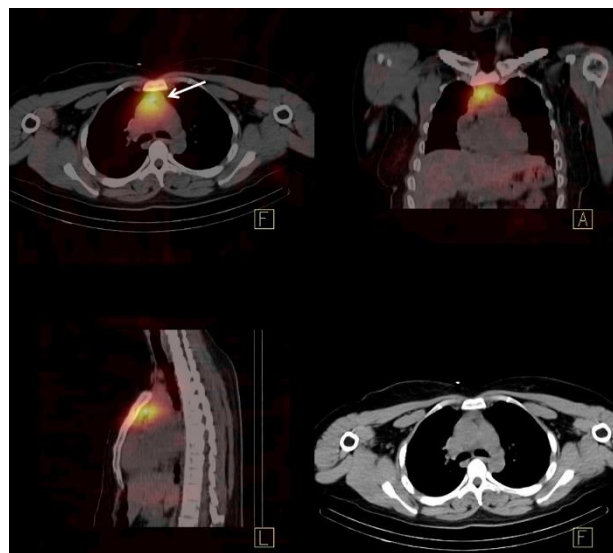


Fig 2. SPECT/CT of the chest showed radioiodine uptake in the anterior mediastinum compatible with thymus (arrow).

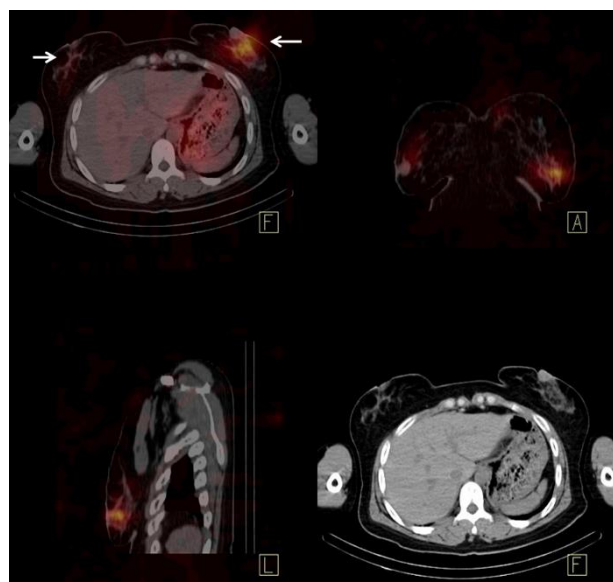


Fig 3. SPECT/CT of the chest also showed bilateral breast uptake (arrows).

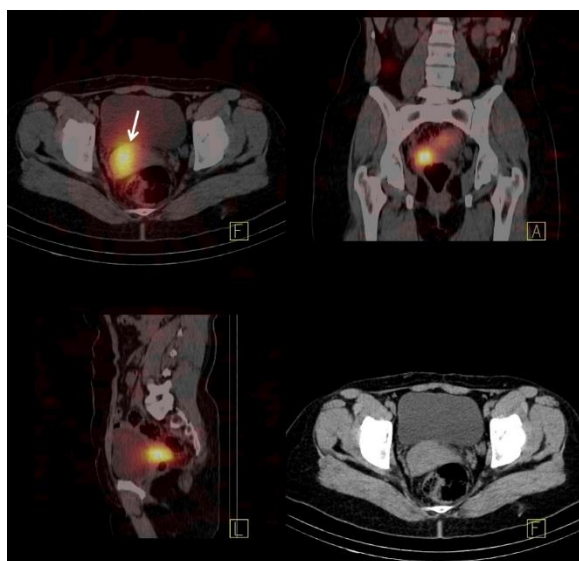


Fig 4. There was radioiodine uptake in the right adnexus (arrow) which was due to luteal body iodine uptake as the patient was in her mid-menstruation cycle.

SPECT/CT of the chest showed radioiodine uptake in the anterior mediastinum compatible with thymus (Figure 2). Figure 3 showed bilateral breast uptake. SPECT/CT images showed radioiodine uptake in the right adnexus (Figure 4, arrow) which was due to luteal body iodine uptake as the patient was in her mid-menstruation cycle.

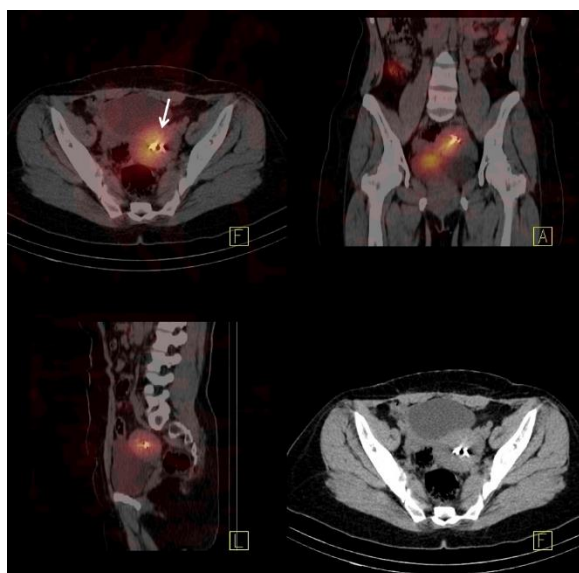


Fig 5. There was increased iodine uptake in the uterine around the intrauterine device (IUD) (arrow).

There was also increased iodine uptake in the uterine around the intrauterine device (IUD) (Figure 5).

DISCUSSION

In our patient, SPECT/CT showed the exact locations of abnormal radioiodine uptake and revealed their benign nature. This added value of SPECT/CT over whole body ¹³¹I scans is compatible with the previous studies in this regard [3, 4].

The locations of radioiodine uptake were breasts, thymus, adnexus and peri-IUD in the uterus. Several studies suggest that thymus may show radioiodine accumulation which can mimic mediastinal metastasis on whole body iodine scan. This is usually due to functional uptake of thymus secondary to sodium-iodide symporter expression [5-7].

Radioiodine accumulation in breast tissue can also happen. Primary breast malignancy, hyperprolactinemia, normal breast tissue and lactating breast are the most common reasons for breast iodine uptake [8]. Clinical & para clinical assessments in our patient didn't show any breast abnormality which denotes a benign breast uptake.

Adnexa are common sites of inflammation in females. Menstrual cycle, ovarian cysts or malignancies, uterine fibroid tissue and myoma are the most common contributors of false-positive findings in female adnexa and uterus [8-12]. In our patient, the cause of increased activity in the adnexus was luteal body radioiodine uptake in the mid menstruation cycle.

Foreign bodies (such as IUD) can also induce inflammatory response and may lead to false-positive iodine uptake [11, 13]. This was also the case in our patient as peri-IUD tissue showed avid iodine uptake.

Our case underscores the importance of SPECT/CT in localization of abnormal radioiodine uptake in WBIS. Adding a CT to SPECT has some advantage such as clarifying difficult presentations such as metastatic lesions to unexpected sites or tissues, revealing unexpected foci of pathologic activity in planar images.

Its disadvantages including additional imaging time and patient discomfort and claustrophobia. In our patient, four sites of benign radioiodine uptake were noted all in one patient which is very unusual in whole body iodine scan.

REFERENCES

1. Palaniswamy SS, Subramanyam P. Unusual sites of metastatic and benign ¹³¹I uptake in patients with differentiated thyroid carcinoma. *Indian J Endocrinol Metab.* 2018 Nov-Dec;22(6):740-750.
2. Song HJ, Xue YL, Xu YH, Qiu ZL, Luo QY. Rare metastases of differentiated thyroid carcinoma: pictorial review. *Endocr Relat Cancer.* 2011 Aug 30;18(5):R165-74.
3. Hassan FU, Mohan HK. Clinical Utility of SPECT/CT Imaging Post-Radioiodine Therapy: Does It Enhance

- Patient Management in Thyroid Cancer? *Eur Thyroid J*. 2015 Dec;4(4):239-45.
4. Agrawal K, Bhattacharya A, Mittal BR. Role of single photon emission computed tomography/computed tomography in diagnostic iodine-131 scintigraphy before initial radioiodine ablation in differentiated thyroid cancer. *Indian J Nucl Med*. 2015 Jul-Sep;30(3):221-6.
 5. Campenni A, Giovinazzo S, Tuccari G, Fogliani S, Ruggeri RM, Baldari S. Abnormal radioiodine uptake on post-therapy whole body scan and sodium/iodine symporter expression in a dermoid cyst of the ovary: report of a case and review of the literature. *Arch Endocrinol Metab*. 2015 Aug;59(4):351-4.
 6. Kayano D, Michigishi T, Ichianagi K, Inaki A, Kinuya S. I-131 uptake in a thymic cyst. *Clin Nucl Med*. 2010 Jun;35(6):438-9.
 7. Singh AK, Bodolan AA, Gilbert MP. A False Positive I-131 Metastatic Survey Caused by Radioactive Iodine Uptake by a Benign Thymic Cyst. *Case Rep Endocrinol*. 2017;2017:6469015.
 8. Chudgar AV, Shah JC. Pictorial review of false-positive results on radioiodine scintigrams of patients with differentiated thyroid cancer. *Radiographics*. 2017 Jan-Feb;37(1):298-315.
 9. Oh JR, Ahn BC. False-positive uptake on radioiodine whole-body scintigraphy: physiologic and pathologic variants unrelated to thyroid cancer. *Am J Nucl Med Mol Imaging*. 2012;2(3):362-85.
 10. Ranade R, Pawar S, Mahajan A, Basu S. Unusual False Positive Radioiodine Uptake on (131)I Whole Body Scintigraphy in Three Unrelated Organs with Different Pathologies in Patients of Differentiated Thyroid Carcinoma: A Case Series. *World J Nucl Med*. 2016 May-Aug;15(2):137-41.
 11. Garger YB, Winfeld M, Friedman K, Blum M. In thyroidectomized thyroid cancer patients, false-positive I-131 whole body scans are often caused by inflammation. *J Investig Med High Impact Case Rep*. 2016;4(1):2324709616633715.
 12. Hannoush ZC, Palacios JD, Kuker RA, Casula S. False Positive Findings on I-131 WBS and SPECT/CT in Patients with History of Thyroid Cancer: Case Series. *Case Rep Endocrinol*. 2017;2017:8568347.
 13. Deandreis D, Lumbroso J, Al Ghuzlan A, Baudin E, Schlumberger M, Leboulleux S. Abnormal pelvic uptake on post-therapeutic radioiodine (131I) whole-body scan. *Eur J Nucl Med Mol Imaging*. 2011 Oct;38(10):1957.