



ORIGINAL RESEARCH ARTICLE

Possible protective effect of *Zataria multiflora* Boiss. on salivary glands in patients with differentiated thyroid carcinoma treated with radioiodine: A randomized, double-blind, placebo-controlled clinical trial

Farinaz Farhoudi^{1,2,†}, Mohammad Ebrahim Zohalinezhad^{1,†}, Mohammad Mehdi Zarshenas³, Nahid Masoudi⁴, Ebrahim Fallahzadeh Abarghoeei¹, Mahdi Haghigatafshar⁴

¹Research Center for Traditional Medicine and History of Medicine, Department of Persian Medicine, School of Medicine, Shiraz University of Medical Sciences, Shiraz, Iran

²Student Research Committee, School of Medicine, Shiraz University of Medical Sciences, Shiraz, Iran

³Department of Phytopharmaceuticals (Traditional Pharmacy), Shiraz University of Medical Sciences, Shiraz, Iran

⁴Department of Nuclear Medicine, School of Medicine, Shiraz University of Medical Sciences, Shiraz, Iran

†These authors shared first authorship

ARTICLE INFO

Article History:

Received: 09 August 2023

Revised: 30 September 2023

Accepted: 02 October 2023

Published Online: 21 November 2023

Keyword:

Persian medicine

Radioiodine

Salivary gland scintigraphy

Thyroid cancer

Zataria multiflora Boiss

*Corresponding Author:

Dr. Mahdi Haghigatafshar

Address: Department of Nuclear Medicine,

School of Medicine, Shiraz University of

Medical Sciences, Shiraz, Iran

Email: afsharm@sums.ac.ir

ABSTRACT

Introduction: The standard treatment for differentiated thyroid carcinoma is post-surgical radioiodine ablation; however, salivary gland damage is prevalent. This study aimed to evaluate the efficacy of *Zataria multiflora* Boiss. (ZM) aerial part essential oil in protecting salivary glands from post-radioiodine therapy damage in differentiated thyroid cancer patients.

Methods: In this randomized clinical trial, 24 patients with differentiated thyroid cancer were randomly allocated to two groups: 11 patients in the ZM essential oil group and 13 in the placebo group. Patients in the intervention and placebo groups received 20 oral drops three times a day of ZM essential oil or placebo respectively, starting from one week before radioiodine therapy to 4 weeks afterward. Salivary gland function was assessed using scintigraphic parameters before and six months following radioiodine therapy.

Results: Follow-up scintigraphy demonstrated significant decrease in parotid UI in the placebo group ($P=0.032$) while significant increase in UI ($P=0.025$) and EF ($P=0.042$) of the parotid was observed in the ZM group. Comparing changes in functional indices of salivary glands between the two groups after six months revealed significantly better function in parotid UI ($P=0.005$) and parotid EF ($P=0.006$) in the ZM group. Substantial damage to parotid UI was significantly less in the ZM group ($P=0.044$).

Conclusion: Results of this study demonstrated that administration of ZM essential oil to patients with differentiated thyroid cancer may protect the salivary glands from radioiodine injury.

Use your device to scan and read the article online



How to cite this article: Farhoudi F, Zohalinezhad ME, Zarshenas MM, Masoudi N, Fallahzadeh Abarghoeei E, Haghigatafshar M. Possible protective effect of *Zataria multiflora* Boiss. on salivary glands in patients with differentiated thyroid carcinoma treated with radioiodine: A randomized, double-blind, placebo-controlled clinical trial. Iran J Nucl Med. 2024;32(1):16-25.



<https://doi.org/10.22034/IRJNM.2023.129359.1572>

INTRODUCTION

One of the most prevalent endocrine cancers is thyroid cancer, which is among the most common cancers in women globally. Histologically, this cancer has four types: papillary, follicular, medullary, and anaplastic [1]. Papillary and follicular types are differentiated types and account for more than 90% of thyroid cancers [2]. High-dose radioiodine (^{131}I) therapy is the standard complementary treatment for patients after thyroidectomy in differentiated types to ablate the thyroid remnant successfully [3]. Despite good prognosis of DTC, post radioiodine therapy damage to the salivary glands is reported to be about 25-60% [4-6].

Decreased salivation, in addition to making patients feel uncomfortable, causes disturbance in taste, speech problems, changes in eating habits, and a predisposition to tooth decay and opportunistic infections [7]. Decreased salivary gland function is not always associated with patients feeling dry mouth, but patients suffer from adverse consequences such as tooth decay [4].

Various strategies have been proposed for decreasing salivary glands damage, including pilocarpine administration, parotid gland massage, and the use of sour candies [8]. As the damaging effect of ^{131}I is related to the free radical formation [9] in the last decade, several studies have assessed the use of agents with free radical scavenging and antioxidant properties as radioprotective substances. There are articles on vitamins E, C, selenium, amiphostin, and several herbs [10-14]. Radioprotective materials, while protecting healthy cells from radiation, do not necessarily protect cancer cells from radiation and can even make cancer cells more susceptible to radiation damage [15, 16]. However, due to the side effects of some therapies and the lack of sufficient or controversial evidence in other methods, there is still no standard preventive measure to prevent the salivary gland damage following the administration of radioactive iodine [17].

Zataria multiflora Boiss. (ZM) with the common name, *Avishan-e-Shirazi* (*Shirazi thyme*), and the traditional name, *Saatar*, is a member of the Lamiaceae family, used as a popular spice [18]; which is native to Iran, Afghanistan, and Pakistan [19]. This plant has also been used in various forms for treating diseases of the brain, gastrointestinal tract, genitourinary system, and joints in Persian Medicine [20]. Along with these various applications, it was known to have an important characteristic that was "Teryaghiyat", i.e., the antidote property; therefore, it was

considered as a "Teryagh". Teryagh is defined as a medicine that has a fast and strong benefit to maintaining and strengthening the body against toxins or anything harmful to the body [21].

According to recent studies, this plant has analgesic, antispasmodic, antibacterial [22], and anti-inflammatory [23] properties. It can control the symptoms of irritable bowel syndrome [24] and induces cytotoxicity in some cancer cell lines [18]. It also inhibits angiogenesis in tumors [25]; reduces the severity of PMS symptoms [26]; has antioxidant properties [22, 24] and protective effects on intestinal ulcers [27]; is against drug-induced kidney [19], liver [28] injuries, and gamma radiation [29]; and improves symptoms and lung function in respiratory diseases. The most active ingredients of ZM essential oil are phenolic compounds: thymol and carvacrol [30, 31]. The antioxidant and radioprotective effect of thymol and carvacrol has been shown in various studies [32-34]. ZM essential oil therapeutic dose is much less than the lethal dose [35] in the same line with prior studies, all in favor of its safety for therapeutic usage [24, 36].

Based on the traditional usage of ZM as an antidote besides current evidence of its anti-inflammatory, antioxidant, and radioprotective properties, this study was implemented to assess the efficacy of ZM essential oil on post-RAI therapy salivary glands injury in differentiated thyroid carcinoma patients.

METHODS

Study plan

This study was designed as a parallel, single-center, double blind, placebo-controlled, randomized clinical trial and has been registered in the Iranian Registry of Clinical Trials (No: IRCT20140514017684N8). The study protocol was approved by the Ethics Committee of Shiraz University of Medical Sciences (IR.SUMS.MED.REC.1399.244). All participants provided signed informed consent.

Patient population

Twenty-four patients aged above 18 years, who had differentiated thyroid carcinoma, and were referred to our nuclear medicine center between December 2020 and September 2021 for post-surgical high-dose radioiodine therapy were randomly allocated to each of the study groups according to a random list. Patients with the following conditions were excluded: xerostomia; history of salivary gland dysfunction; salivary issues such as stone or tumor; history of prior head and neck radiotherapy; having diagnosed

rheumatological diseases such as Sjögren's disease; earlier administration of ^{131}I , use of drugs affecting the salivary gland function, such as antihistaminic agents, beta-blockers, atropine, benzodiazepines, tricyclic antidepressants, and antipsychotic drugs 14 days prior to the study; and history of hypersensitivity to ZM. According to the instruction of the manufacturer and a former study [24], patients in the intervention group and the control group received 20 drops of ZM and placebo solution respectively, three times a day from one week before ^{131}I therapy until four weeks following treatment.

ZM aerial part essential oil and preparation of placebo solutions

The 2% solution of ZM aerial part essential oil with the "Gastrolit" trademark with the batch number of 63004037 and the placebo solution were bought from Barij Essence Pharmaceutical Company. Gastrolit oral drops were standardized based on 4.4–7 mg thymol per ml. To increase odor matching, the dropper of the placebo solution was soaked in the essential oil and was dried by the company. Bottles were coded as A and B; hence, patients and the investigator who recorded scintigraphic parameters were not aware of the contents.

Salivary gland imaging

On the admission day for radioiodine ablative therapy, all patients underwent salivary gland scintigraphy (SGS). Each patient was in a hypothyroid state with serum thyroid stimulating hormone levels higher than 25 mIU/l. Patients were instructed to fast before salivary imaging. During SGS, the patients were in supine position with their necks hyperextended. Using a dual-head gamma camera (General Electric Infinia Hawkeye 4 scintillation dual-head gamma camera) equipped with a low-energy, high-resolution collimator, the images were acquired on a large field of view. 370MBq of [$^{99\text{m}}\text{Tc}$]Tc-pertechnetate was injected intravenously for each patient. Sequential dynamic images were taken at 2 min/frame on a 128_128 matrix with a zoom factor of 1.55 for 40 min, promptly after [$^{99\text{m}}\text{Tc}$]Tc-pertechnetate administration. The energy window was 20% around the 140 keV photopeak of $^{99\text{m}}\text{Tc}$. To stimulate the secretion of saliva, twenty minutes post-injection of the radiotracer, a syringe was used to administer 5ml of lemon juice (50% concentrated) into the patient's mouth.

Image interpretation

Circular ROI was drawn manually over every parotid and submandibular gland. Uniform

background regions were made in bilateral temporo-orbital regions for parotid glands and the bilateral supraclavicular regions for submandibular glands. Time–activity curves of [$^{99\text{m}}\text{Tc}$]Tc-pertechnetate were constructed using counts per minute, uptake, and washout. Concerning interpersonal variations bias during the time of constructing the regions of interest (ROI), documentation of scintigraphic parameters was done. Based on gained ROI counts and the resulting curves of time–activity, subsequent functional indices were applied for each salivary gland according to the following revised formulae as the outcome measures [37-39]:

(1) Uptake index (UI)

UI = (count of a salivary gland at the maximum uptake minute – count of the background of corresponding salivary gland at the maximum uptake minute)/count of the background of the salivary gland at the maximum uptake minute.

(2) Excretion fraction (EF)

EF = (count of a salivary gland at the maximum uptake minute – count of a salivary gland at the minimum uptake minute after lemon juice)/count of a salivary gland at the maximum uptake minute $\times 100\%$.

Follow up assessment

Six months after ^{131}I administration, 22 patients underwent the second SGS with the same condition as the first SGS. Each patient was in a hypothyroid state with serum thyroid stimulating hormone levels higher than 25 mIU/l. Considering the first SGS, the same scintigraphic parameters were calculated, and changes of functional parameters were finally calculated as follows: (1) change in UI (ΔUI): pretreatment UI minus post-radioiodine therapy UI; (2) change in EF (ΔEF): pretreatment EF minus post-radioiodine therapy EF. According to the mentioned formulae, a positive value for each marker indicates functional deterioration after ^{131}I treatment. Conversely, a negative change accounts for functional improvement. Significant (moderate or severe) damage was considered more than a 21% reduction in scintigraphic parameters according to prior studies [40].

Statistical Analysis

Quantitative variables between the two groups were compared using the Mann–Whitney U-test. Wilcoxon signed-rank test was applied to compare the two phases within the same group. To compare categorical variables between the two groups, Fisher's exact test was used. Significant P-values were considered as less than 0.05.

RESULTS

Study flow

During the six months of the study course, out of the 24 patients enrolled in the study, two failed to follow up; one deceased due to prostate

cancer, and the other refused the second salivary gland scintigraphy for personal reasons. Finally, data from 22 patients, composed of ten patients in the ZM group and twelve in the placebo group, were analyzed. Figure 1 demonstrates details of the consort chart.

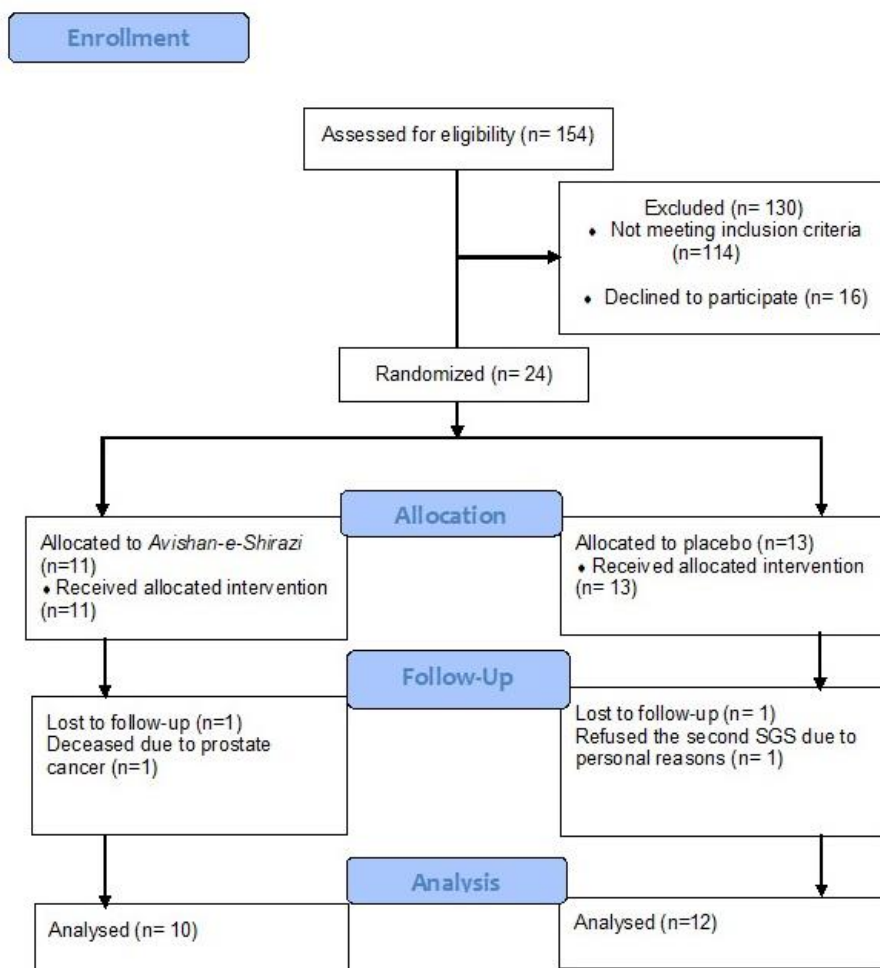


Figure 1. CONSORT flow diagram of the patients' enrollment and follow-up

Baseline

Demographic characteristics and ¹³¹I dose are shown in Table 1. There was no significant difference in age, sex, BMI, and ¹³¹I dose between the study groups (P > 0.05). Table 2

shows the baseline scintigraphic parameters of the patients, which showed no significant difference at baseline between the two groups (P > 0.05).

Table 1. Demographic characteristics and ¹³¹I dose in the ZM and placebo groups before the intervention

Baseline variables	ZM, n =10	Placebo, n=12	P value [†]
Gender [n (%)]			
Male	1 (10%)	1 (8.3%)	1.000
Female	9 (90%)	11 (91.7%)	
Age (years) (mean ± SD)	40±11.56	41.41±10.85	0.668
BMI (kg/m ²) (mean ± SD)	25.50±3.90	27.48±2.20	0.129
Administered I-131 activity (mCi) (mean ± SD)	160±21.08	150±10.66	0.239

[†] Mann–Whitney U-test for quantitative variables; Fisher's exact test for qualitative variables
BMI: body mass index

Table 2. Baseline variables in the ZM and placebo groups before the intervention

Type of salivary gland		Scintigraphic indices (mean±SD)		P value [†]
		ZM (mean ± SD), n =20 ^a	Placebo (mean ± SD), n =24 ^a	
Parotid gland	UI	1.93±0.69	2.35±0.76	0.150
	EF	40.50±18.58	47.16±16.99	0.168
Submandibular gland	UI	1.94±1.05	1.76±0.77	0.906
	EF	37.24±16.47	29.95±13.20	0.069

^aTotal number of similar glands[†]Mann–Whitney U-test

EF, excretion fraction; UI, uptake index

Scintigraphy parameters

Table 3 shows the scintigraphic parameters of the placebo group before and six months after radioiodine therapy. As noted, the UI of the parotid glands significantly decreased after RAI

therapy (P<0.05). As shown in Table 4, UI and EF of the parotid glands increased significantly after treatment with radioiodine in the ZM group (P<0.05).

Table 3. Scintigraphic variables before and after RAI therapy in the placebo group

Category of salivary gland		Scintigraphic indices (mean±SD)		P value [†]
		Prior to ¹³¹ I therapy (mean ± SD), n =24 ^a	Post ¹³¹ I therapy (mean ± SD), n =24 ^a	
Parotid gland	UI	2.35±0.76	1.82±0.61	0.032*
	EF	47.16± 16.99	39.08± 17.77	0.079
Submandibular gland	UI	1.76±0.77	2.22±3.52	0.123
	EF	29.95±13.20	28.25±14.40	0.738

^aTotal number of similar glands[†]Wilcoxon signed-rank test

*Significant difference

EF, excretion fraction; UI, uptake index

Table 4. Scintigraphic variables before and after radioiodine therapy in the ZM group

Category of salivary gland		Scintigraphic indices (mean±SD)		P value [†]
		Prior to ¹³¹ I therapy (mean ± SD), n =20 ^a	Post ¹³¹ I therapy (mean ± SD), n =20 ^a	
Parotid gland	UI	1.93± 0.69	2.14± 0.82	0.025*
	EF	40.50± 18.58	48.75± 16.72	0.042*
Submandibular gland	UI	1.94± 1.05	1.72±0.83	0.093
	EF	37.24±16.47	35.45±11.74	0.575

^aTotal number of similar glands[†] Wilcoxon signed-rank test

*Significant difference

EF: excretion fraction, UI: uptake index

Changes in functional scintigraphic parameters in the ZM and placebo groups after treatment are shown in Table 5. As demonstrated in this Table, changes in UI and EF of the parotid gland

showed significant differences between the two groups (P<0.05), indicating a better function of the parotid gland in the ZM group after radioiodine therapy.

Table 5. Comparison between ZM and placebo groups after treatment

Types of salivary gland	Changes of functional scintigraphic indices ^a	ZM group (mean ± SD), n =20 ^b	Placebo group (mean ± SD), n =24 ^b	P value [†]
Parotid gland	ΔUI	-0.21±0.49	0.53±1.08	0.005*
	ΔEF	-8.25±17.48	8.08±25.18	0.006*
Submandibular gland	ΔUI	0.22±0.48	-0.46±3.60	0.925
	ΔEF	1.79±20.88	1.70±13.25	0.540

^aFor all scintigraphic parameters, the changes (Δ) after ¹³¹I therapy corresponding to the values before therapy were calculated as pre-¹³¹I therapy minus post-¹³¹I therapy values^bTotal number of similar glands[†]Mann–Whitney U-test

*Significant difference

EF: excretion fraction, UI: uptake index

The total percentage of moderate and severe damage was significantly less in the UI of the

parotid gland of the ZM group in comparison with the placebo group: 2 out of 20 parotid

glands (10%) versus 9 out of 24 (37.5%) ($P < 0.05$). Figures 2 and 3 show the pre- and post-treatment salivary gland scintigraphies of a

patient in the ZM group. The scintigraphies of a patient in the placebo group are shown in Figures 4 and 5.

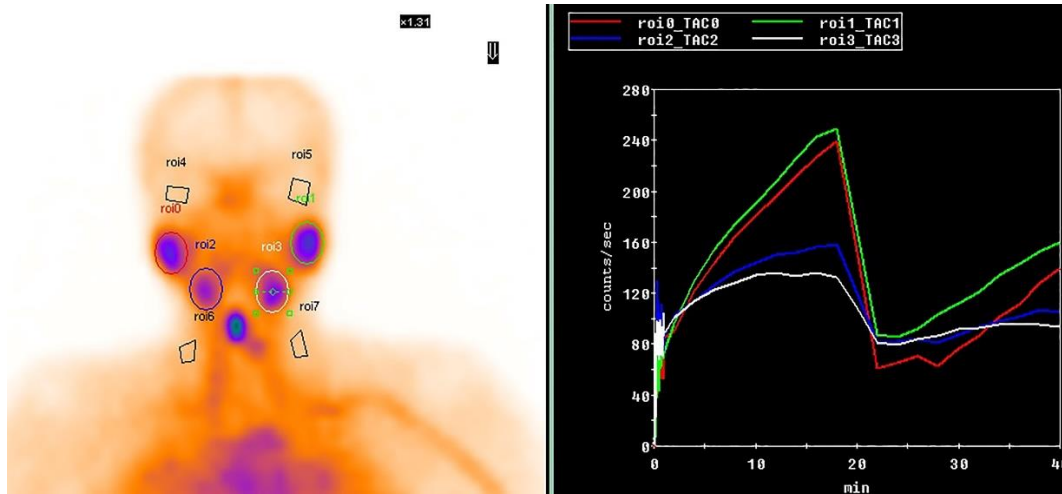


Figure 2. Uptake and excretion function of four major salivary glands in a patient from the Zataria multiflora Boiss group before the RAI therapy

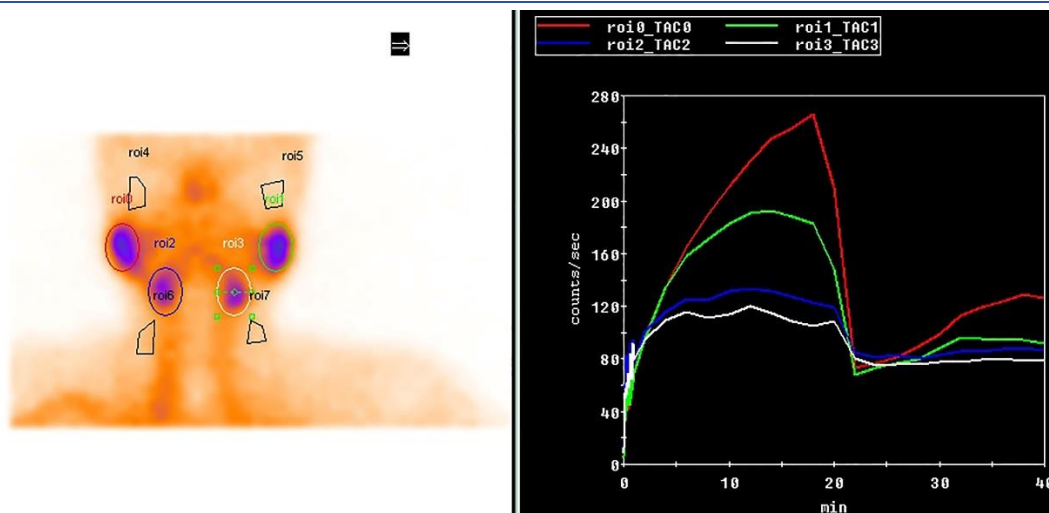


Figure 3. Uptake and excretion function of four major salivary glands in a patient from the Zataria multiflora Boiss group 6 months after the RAI therapy

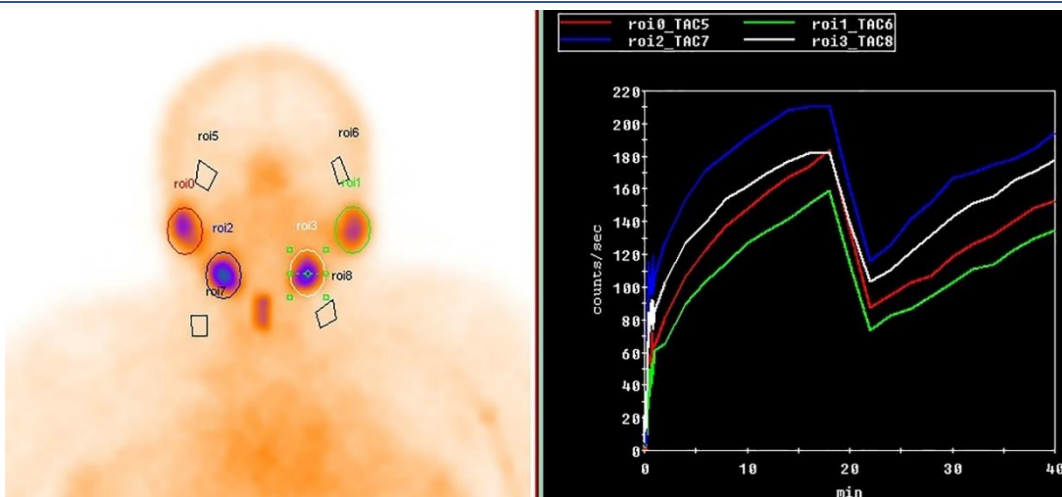


Figure 4. Uptake and excretion function of four major salivary glands in a patient from the placebo group before the RAI therapy

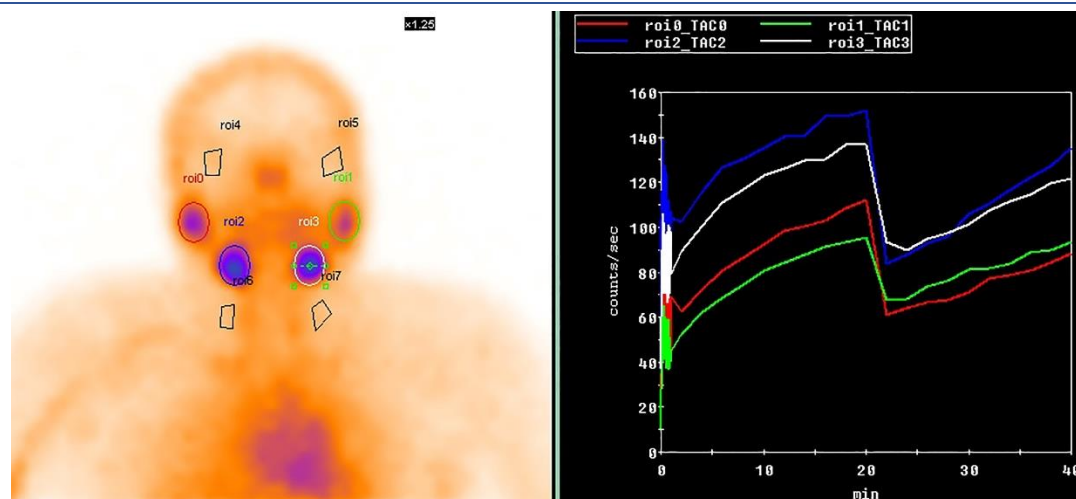


Figure 5. Uptake and excretion function of four major salivary glands in a patient from the placebo group 6 months after the RAI therapy

Adverse events

During the study course, one patient in the ZM group developed an aphthous lesion. Other patients did not report any adverse events.

DISCUSSION

The current study results showed that using ZM aerial parts essential oil 20 drops three times a day from one week before to 4 weeks after administration of ^{131}I might protect the salivary glands from radioactive iodine (RAI) therapy damage.

^{131}I is specifically taken up by the thyroid tissue, but it also actively accumulates in the acinar cells of the salivary glands by iodine substitution for chloride in the sodium-potassium-chloride (Na/K/Cl) cotransporter [41, 42]. The concentrated ^{131}I in the salivary glands is even up to 700 times than the plasma level [42]. This high concentration exposes the salivary glands to a harmful radiation dose [12], but the exact mechanism is unknown [43]. SGS has been used for about five decades. Along with its safety, it is also non-invasive, well tolerated, reproducible, and easily performed. Hence, it is the sole imaging technique for demonstrating the function of the salivary glands [44].

Changes in functional SGS parameters in the placebo group

In our study, after the radioiodine therapy, the uptake index of the parotid glands declined significantly in the placebo group. Which is in concordance with prior studies, showing that parotid glands are more susceptible to radioiodine than submandibular glands [40, 43, 45]. In Jeong et al. study on 213 DTC patients who underwent RAI ablation, by salivary

scintigraphic studies before and five years after the treatment; in 47.4% of the patients, the function of salivary glands decreased in the five years follow-up SGS. EF decreased, and moderate to severe decrease was more prevalent in the parotid in comparison with the submandibular gland (31.9% vs. 9.4% and 30.3% vs. 8.7%, respectively) [40].

Krčálová et al. showed that activities higher than 150 mCi significantly deteriorated the excretion of the parotid gland. In activities more than 250 mCi, the parotid uptake was also decreased. Submandibular glands were not affected even in higher RAI activities [46]. Conversely, Lv et al. showed that among 458 patients with DTC who received multiple RAI therapies with low to high-doses of ^{131}I (30-550 mCi) in each course, submandibular glands had more functional deterioration than parotid glands [47]. In another study among 36 patients who received 100 mCi ^{131}I , a significant decline in function was observed only in the left submandibular gland six months after RAI therapy [39]. According to the above-mentioned studies, it is controversial which salivary gland is more susceptible to radioiodine damage. Different hypotheses are proposed. One is that the parotid glands are more susceptible to radiation. The reason could be the fact that the main radiation damage is seen in acinar cells, and they are more prevalent in the parotid glands [43]. Another group, based on some animal and scarce human studies, proposes that radioiodine concentration in submandibular glands is higher than in parotid glands; therefore, submandibular glands are more susceptible to radiation damage [47]. Different results of these studies may be the

result of the difference in RAI doses, follow-up duration, SGS indices, and sample sizes.

Changes in functional SGS parameters in the ZM group

Given the functional parameters of the parotid and submandibular glands in the ZM group, a significant increase was shown in UI and EF of parotid glands after radioiodine therapy. Our study also showed that the function of salivary glands in the ZM group after the intervention was less affected by RAI therapy.

Among different strategies proposed for the prevention of post-RAI therapy salivary gland damage, using antioxidants has attracted the researchers' concern in recent decades [48]. Several studies have shown the antioxidant property of thymol and carvacrol as ZM essential oil main components [49]. An animal study that used thymol at a dose of 50 mg/Kg demonstrated the protective effect of thymol on post-radiotherapy salivary glands damage in rats according to SGS parameters [34]. Results of an animal study on 47 veterans exposed to sulfur mustard treated with ZM extract showed an increase in antioxidant biomarkers and a decrease in oxidant biomarkers [50].

The increase in SGS parameters following RAI ablation in our study has been demonstrated in other studies as well [47]. One of the illustrations of this compensatory mechanism is the proliferation of undamaged cells, which is shown to be enhanced by pretreatment with vitamin E and pilocarpine [12, 51].

Given that differentiated thyroid cancer has an excellent prognosis, it is essential preventing damage to the salivary gland to improve the patients' quality of life. ZM essential oil is a natural antioxidant with high lethal dose of its main ingredient, thymol. No serious adverse event has been reported regarding therapeutic doses of ZM products [24, 52]. In the current study, there was no report of severe side effects of ZM essential oil consumption that might be the result of the small sample size.

CONCLUSION

To the best of our knowledge, this was the first human study that assessed the radioprotective effect of ZM. In addition to the strengths of the present study such as prospective design, using a placebo against ZM, and double blinding the study, there were some inherent limitations. Small sample size, administration of one dose of ZM, and lack of assessment of related clinical symptoms that might present minor salivary

gland damage were among the most noticeable limitations. This study revealed that using ZM essential oil might protect the salivary glands from post-radioiodine injury in differentiated thyroid cancer patients. However, further human studies with the similar reference values and SGS indices, larger sample sizes, and follow-ups in different stage to evaluate the effects on acute and chronic damages, along with assessing clinical symptoms, are recommended.

Acknowledgment

This study has been part of a Ph.D thesis at the Research Center for Traditional Medicine and History of Medicine of Shiraz University of Medical Sciences. The Research Consultation Center, and the Center for Development of Clinical Research of Nemazee Hospital are acknowledged for their invaluable consultations. Our study was financially supported by Shiraz University of Medical Sciences (grant No. 20601).

REFERENCES

1. Farhood B, Geraily G, Alizadeh A. Incidence and mortality of various cancers in Iran and compare to other countries: a review article. *Iran J Public Health*. 2018 Mar;47(3):309-16.
2. Hollingsworth B, Senter L, Zhang X, Brock GN, Jarjour W, Nagy R, Brock P, Coombes KR, Kloos RT, Ringel MD, Sipos J, Lattimer I, Carrau R, Jhiang SM. Risk factors of 131I-induced salivary gland damage in thyroid cancer patients. *J Clin Endocrinol Metab*. 2016 Nov;101(11):4085-93.
3. Jung JH, Lee CH, Son SH, Jeong JH, Jeong SY, Lee SW, Lee J, Ahn BC. High prevalence of thyroid disease and role of salivary gland scintigraphy in patients with xerostomia. *Nucl Med Mol Imaging*. 2017 Jun;51(2):169-77.
4. Baudin C, Lussey-Lepoutre C, Bressand A, Buffet C, Menegaux F, Soret M, Broggio D, Bassinet C, Huet C, Armengol G, Leenhardt L. Salivary Dysfunctions and Consequences After Radioiodine Treatment for Thyroid Cancer: Protocol for a Self-Controlled Study (START Study). *JMIR Res Protoc*. 2022 Jul 22;11(7):e35565.
5. Moreddu E, Baumstarck-Barrau K, Gabriel S, Fakhry N, Sebag F, Mundler O, Chossegros C, Taïeb D. Incidence of salivary side effects after radioiodine treatment using a new specifically-designed questionnaire. *Br J Surg*. 2017 Jul 1;55(6):609-12.
6. Fard-Esfahani A, Fallahi B, Karimi M, Beiki D, Saghari M, Emami-Ardekani A, Fard-Esfahani P, Ansari M, Eftekhari M. Changes in salivary gland function following radioiodine therapy of thyroid diseases: A comparison of high-dose therapy for thyroid cancer and low-dose therapy for benign thyroid disease. *Iran J Nucl Med*. 2015;23(1):1-7.
7. Verburg FA, Hänscheid H, Luster M. Radioactive iodine (RAI) therapy for metastatic differentiated thyroid cancer. *Best Pract Res Clin Endocrinol Metab*. 2017 Jun 1;31(3):279-90.
8. Charalambous A. Seeking optimal management for radioactive iodine therapy-induced adverse effects. *Asia-Pac J Oncol Nurs*. 2017 Oct 1;4(4):319-22.

9. Alidadi S, Monfared AS, Amiri M, Zabih E, Assadollahi E, Gholami A, Moazezi Z, Abedian Z. The efficacy of melatonin against radiotoxicity of iodine-131 and its response to treatment in hyperthyroid patients: a randomized controlled trial. *Nucl Med Rev* 2022;25(1):31-6
10. Taheri A, Rostamzadeh A, Gharib A, Fatehi D. Radioprotective effects of Silymarin, a natural medical herb, in modulation and prevention of radiation induced damages. *Der Pharm Lett*. 2016;8(9):146-50.
11. Son H, Lee SM, Yoon RG, Lee H, Lee I, Kim S, Chung WY, Lee JW. Effect of selenium supplementation for protection of salivary glands from iodine-131 radiation damage in patients with differentiated thyroid cancer. *Hell J Nucl Med*. 2017;20(1):62-70.
12. Upadhyaya A, Zhou P, Meng Z, Wang P, Zhang G, Jia Q, Tan J, Li X, Hu T, Liu N, Wang S. Radioprotective effect of vitamin E on salivary glands after radioiodine therapy for differentiated thyroid cancer: a randomized-controlled trial. *Nucl Med Commun*. 2017 Nov 1;38(11):891-903.
13. Han EJ, Im ST, Ahn G, Lee SH. Radio-protective effects of Thymus quinquecostatus Celak extract in mice. *Appl Radiat Isot*. 2023 May 30:110881.
14. Safaei M, Jafarpour SM, Mohseni M, Salimian M, Akbari H, Karami F, Aliasgharzadeh A, Farhood B. Vitamins E and C prevent DNA double-strand breaks in peripheral lymphocytes exposed to radiations from Iodine-131. *Indian J Nucl Med*. 2018 Jan;33(1):20.
15. Maier P, Wenz F, Herskind C. Radioprotection of normal tissue cells. *Strahlenther Onkol*. 2014 Aug 1;190(8):745.
16. Klubo-Gwiedzinska J, Costello Jr J, Jensen K, Patel A, Van Nostrand D, Burman KD, Wartofsky L, Vasko V. Amifostine does not protect thyroid cancer cells in DNA damaging in vitro models. *Endocr Connect*. 2017 Oct;6(7):469.
17. Christou A, Papastavrou E, Merkouris A, Frangos S, Tamana P, Charalambous A. Clinical studies of nonpharmacological methods to minimize salivary gland damage after radioiodine therapy of differentiated thyroid carcinoma: systematic review. *Evid-based Complement Altern Med*. 2016 Oct;2016.
18. Ahani N, Sangtarash MH, Eskandani MA, Houshmand M. Zataria multiflora boiss. Essential oil induce apoptosis in two human colon cancer cell lines (HCT116 & SW48). *Iran J Public Health*. 2020 Apr;49(4):753.
19. Hajjhashemi S, Jafarian T, Ahmadi M, Rahbari A, Ghanbari F. Ameliorative effects of Zataria multiflora hydro-alcoholic extract on gentamicin induced nephrotoxicity in rats. *Drug Res*. 2018 Jul;68(07):387-94.
20. Shams MR, Rahimi R, Farjazmand F, editors. *Makhzanoladvieh*. Tehran; 2012.
21. Aghili-khorasani MH. *Kholase al hekma*. 1st ed. Tehran: Iranian Teb publisher; 2017.
22. Sharafati Chaleshtori R, Rafeian Kopaei M, Rokni N, Mortezaei S, Sharafati Chaleshtori A. Antioxidant activity of Zataria multiflora hydroalcoholic extract and its antibacterial effect on Staphylococcus aureus. *J Maz Univ Med*. 2012 Feb 10;21(1):88-94.
23. Aghamohammadi A, Moslemi D, Akbari J, Ghasemi A, Azadbakht M, Asgharpour A, Hosseinimehr SJ. The effectiveness of Zataria extract mouthwash for the management of radiation-induced oral mucositis in patients: A randomized placebo-controlled double-blind study. *Clin Oral Invest*. 2018 Jul;22:2263-72.
24. Mahboubi M. Therapeutic potential of Zataria multiflora boiss in treatment of irritable bowel syndrome (IBS). *J Diet Suppl*. 2019;16(1):119-28.
25. Norooznehad AH, Keshavarz M, Norooznehad F, Mansouri K. Inhibition of Angiogenesis: A Novel Effect of Zataria Multiflora. *Int J Hematol Oncol Stem Cell Res*. 2017 Apr 1;11(2):96-101.
26. Sodouri M, Masoudi Alavi N, Fathizadeh N, Taghizadeh M, Azarbad Z, Memarzadeh M. Effects of Zataria Multiflora, Shirazi thyme, on the Severity of Premenstrual Syndrome. *Nurs Midwifery Stud*. 2013 Dec;2(4):57-63.
27. Minaian M, Sajjadi SE, Amini K. Antiulcer effects of Zataria multiflora Boiss. on indomethacin-induced gastric ulcer in rats. *Avicenna J Phytomed*. 2018 Sep-Oct;8(5):408-15.
28. Mahmoodi M, Koohepyma F, Saki F, Maleksabet A, Zare MA. The protective effect of Zataria multiflora Boiss. hydroalcoholic extract on TNF- α production, oxidative stress, and insulin level in streptozotocin-induced diabetic rats. *Avicenna J Phytomed*. 2019 Jan-Feb;9(1):72-83.
29. Hosseinimehr SJ, Mahmoudzadeh A, Ahmadi A, Ashrafi SA, Shafaghati N, Hedayati N. The radioprotective effect of Zataria multiflora against genotoxicity induced by γ irradiation in human blood lymphocytes. *Cancer Biother Radiopharm*. 2011 Jun;26(3):325-9.
30. Fatemi F, Asri Y, Rasooli I, Alipoor ShD, Shaterloo M. Chemical composition and antioxidant properties of γ -irradiated Iranian Zataria multiflora extracts. *Pharm Biol*. 2012 Feb;50(2):232-8.
31. Sajed H, Sahebkar A, Iranshahi M. Zataria multiflora Boiss. (Shirazi thyme)--an ancient condiment with modern pharmaceutical uses. *J Ethnopharmacol*. 2013 Feb 13;145(3):686-98.
32. Hashemipour H, Kermanshahi H, Golian A, Veldkamp T. Effect of thymol and carvacrol feed supplementation on performance, antioxidant enzyme activities, fatty acid composition, digestive enzyme activities, and immune response in broiler chickens. *Poult Sci*. 2013 Aug;92(8):2059-69.
33. Arivalagan S, Thomas NS, Kuppusamy T, Namashivayam N. Radioprotective effect of carvacrol against X-Radiation-Induced cellular damage in cultured human peripheral blood lymphocytes. *J Environ Pathol Toxicol Oncol*. 2015;34(3):263-75.
34. Abedi SM, Yarmand F, Motallebnejad M, Seyedmajidi M, Moslemi D, Bijani A, Hosseinimehr SJ. Radioprotective effect of thymol against salivary glands dysfunction induced by ionizing radiation in rats. *Iran J Pharm Res*. 2016 Fall;15(4):861-6.
35. Majlessi N, Choopani S, Kamalinejad M, Azizi Z. Amelioration of amyloid β -induced cognitive deficits by Zataria multiflora Boiss. essential oil in a rat model of Alzheimer's disease. *CNS Neurosci Ther*. 2012 Apr;18(4):295-301.
36. Babaee N, Baradaran M, Mohamadi H, Nooribayat S. Therapeutic effects of Zataria Multiflora essential oil on recurrent oral aphthous lesion. *Dent Res J (Isfahan)*. 2015 Sep-Oct;12(5):456-60.
37. Klutmann S, Bohuslavizki KH, Kröger S, Bleckmann C, Brenner W, Mester J, Clausen M. Quantitative salivary gland scintigraphy. *J Nucl Med Technol*. 1999 Mar;27(1):20-6.
38. Fallahi B, Beiki D, Abedi SM, Saghari M, Fard-Esfahani A, Akhbari F, Mokarami B, Eftekhari M. Does vitamin E protect salivary glands from I-131 radiation damage in patients with thyroid cancer? *Nucl Med Commun*. 2013 Aug;34(8):777-86.
39. Upadhyaya A, Meng Z, Wang P, Zhang G, Jia Q, Tan J, Li X, Hu T, Liu N, Zhou P, Wang S, Liu X, Wang H, Zhang C, Zhao F, Yan Z. Effects of first radioiodine ablation on functions of salivary glands in patients with differentiated thyroid cancer. *Medicine (Baltimore)*. 2017 Jun;96(25):e7164.
40. Jeong SY, Kim HW, Lee SW, Ahn BC, Lee J. Salivary gland function 5 years after radioactive iodine ablation in

- patients with differentiated thyroid cancer: direct comparison of pre- and postablation scintigraphies and their relation to xerostomia symptoms. *Thyroid*. 2013 May;23(5):609-16.
41. Son H, Lee SM, Yoon RG, Lee H, Lee I, Kim S, Chung WY, Lee JW. Effect of selenium supplementation for protection of salivary glands from iodine-131 radiation damage in patients with differentiated thyroid cancer. *Hell J Nucl Med*. 2017 Jan-Apr;20(1):62-70.
 42. Riachy R, Ghazal N, Haidar MB, Elamine A, Nasrallah MP. Early Sialadenitis After Radioactive Iodine Therapy for Differentiated Thyroid Cancer: Prevalence and Predictors. *Int J Endocrinol*. 2020 Aug 4;2020:8649794.
 43. Tanwar KS, Rana N, Mittal BR, Bhattacharya A. Early Quantification of Salivary Gland Function after Radioiodine Therapy. *Indian J Nucl Med*. 2021 Jan-Mar;36(1):25-31.
 44. Afzelius P, Nielsen MY, Ewertsen C, Bloch KP. Imaging of the major salivary glands. *Clin Physiol Funct Imaging*. 2016 Jan;36(1):1-10.
 45. Kang JY, Jang SJ, Lee WW, Jang SJ, Lee YJ, Kim SE. Evaluation of Salivary Gland Dysfunction Using Salivary Gland Scintigraphy in Sjögren's Syndrome Patients and in Thyroid Cancer Patients after Radioactive Iodine Therapy. *Nucl Med Mol Imaging*. 2011 Sep;45(3):161-8.
 46. Krčálová E, Horáček J, Gabalec F, Žák P, Doležal J. Scintigraphic evaluation of salivary gland function in thyroid cancer patients after radioiodine remnant ablation. *Eur J Oral Sci*. 2020 Jun;128(3):204-10.
 47. Lv X, Yin L, Wu W, Li N, Zhang R, Li X, Jia Q, Tan J, Wang P, Zheng X, He X, Huang C, Li D, Wang Y, Meng Z. Quantitative Scintigraphy Evaluated the Relationship between 131I Therapy and Salivary Glands Function in DTC Patients: A Retrospective Analysis. *J Healthc Eng*. 2022 Apr 14;2022:7640405.
 48. Ma D, Yin X, Liu J, Fang Q, He Q, Xiong Y, Gong F. Different medications for preventing 131I-induced salivary gland damage in thyroid cancer patients: a network meta-analysis. *Chin Gen Pract*. 2021 Oct 20;24(30):3828.
 49. Khazdair MR, Ghorani V, Alavinezhad A, Boskabady MH. Pharmacological effects of *Zataria multiflora* Boiss L. and its constituents focus on their anti-inflammatory, antioxidant, and immunomodulatory effects. *Fundam Clin Pharmacol*. 2018 Feb;32(1):26-50.
 50. Khazdair MR, Rajabi O, Balali-Mood M, Beheshti F, Boskabady MH. The effect of *Zataria multiflora* on pulmonary function tests, hematological and oxidant/antioxidant parameters in sulfur mustard exposed veterans, a randomized doubled-blind clinical trial. *Environ Toxicol Pharmacol*. 2018 Mar;58:180-8.
 51. Burlage FR, Faber H, Kampinga HH, Langendijk JA, Vissink A, Coppes RP. Enhanced proliferation of acinar and progenitor cells by prophylactic pilocarpine treatment underlies the observed amelioration of radiation injury to parotid glands. *Radiother Oncol*. 2009 Feb;90(2):253-6.
 52. Zamani N, Shams M, Nimrouzi M, Zarshenas MM, Abolhasani Foroughi A, Fallahzadeh Abarghooei E, Fattahi MR. The effects of *Zataria multiflora* Boiss. (*Shirazi thyme*) on nonalcoholic fatty liver disease and insulin resistance: A randomized double-blind placebo-controlled clinical trial. *Complement Ther Med*. 2018 Dec;41:118-123