

Bochdalek hernia with intrathoracic kidney as one of its contents Incidentally identified by ^{99m}Tc -DTPA renogram

Shantanu Pande, Subramanyam Padma, Palaniswamy Shanmuga Sundaram

Department of Nuclear Medicine & PET/CT, Amrita Institute of Medical Sciences,
Cochin, Kerala, India

Case Report

(Received 19 December 2012, Revised 24 December 2012, Accepted 26 December 2012)

ABSTRACT

Congenital diaphragmatic hernia (CDH) is a rare anomaly with a reported incidence of 1 in 16,000 populations. It may be associated with herniation of stomach, intestinal loops, spleen, and kidney through a chest wall defect. We report a case of a 1 year old male child who presented with recurrent fever, occasional chills and rigor of 4 months duration. Left kidney was non visualised on ultrasound examination. Patient was referred for a ^{99m}Tc DTPA (Diethylenetriamine penta-acetic acid) renogram to look for the presence of an ectopic left kidney. An intrathoracic left kidney was identified that was normally functioning and PUJ (pelviureteric junction) non obstructed. A routine chest X-ray was performed to look for respiratory tract infection that showed bowel loops in left posterior thorax, raising a suspicion for CDH. The patient underwent thoracoscopic repair of CDH and the hernial contents were found to be left kidney, intestinal loops and spleen. Intrathoracic kidney is relatively rare and constitutes 5% of all ectopic kidneys and is invariably PUJ non obstructed.

Keywords: Diaphragmatic hernia; Intrathoracic kidney; Bowel in thorax; DTPA renogram

Iran J Nucl Med 2012;20(2):37-40

Corresponding author: Dr S. Padma, Department of Nuclear Medicine & PET/CT, Amrita Institute of Medical Sciences, Cochin-6802041, Kerala, India. E-mail: padmas@aims.amrita.edu

INTRODUCTION

Congenital diaphragmatic hernia (CDH) is a rare anomaly with a reported incidence of 1 in 16,000 populations, [1]. Its association with multiple congenital anomalies in various organs is well recognized. It may be associated with herniation of stomach, intestinal loops, spleen, and kidney due to a diaphragmatic defect, [2] It is a major surgical emergency in newborns as it may be lead to pulmonary hypoplasia, or may be related to persistent fetal circulation, and other coexisting congenital anomalies [3]. The key to survival lies in early diagnosis and treatment as the herniating contents prevent the normal development of lung parenchyma in antenatal and neonatal period. Thus the mortality in children with CDH with other associated anomalies has been reported to be 25-60% [3,4].

Nuclear medicine plays an important role in the identification of some of the contents of CDH like kidney and spleen which may present as an intrathoracic mass or can be used as part of evaluation for non visualization of kidney, spleen or stomach using organ specific tracers like DTPA, phytate or TcO_4 (Technetium pertechnetate) [5,6]. Diagnosis can be made by prenatal ultrasonogram examination (USG) but its accuracy can be limited by poor acoustic contrast between fetal lung, herniated viscera and position of fetus.

CASE HISTORY

Our patient is a one year old male child, first born of a non consanguineous marriage (full term normal delivery) who presented with recurrent fever, occasional chills and rigor since 4 months. There was no associated cough, dyspnoea, or seizures.

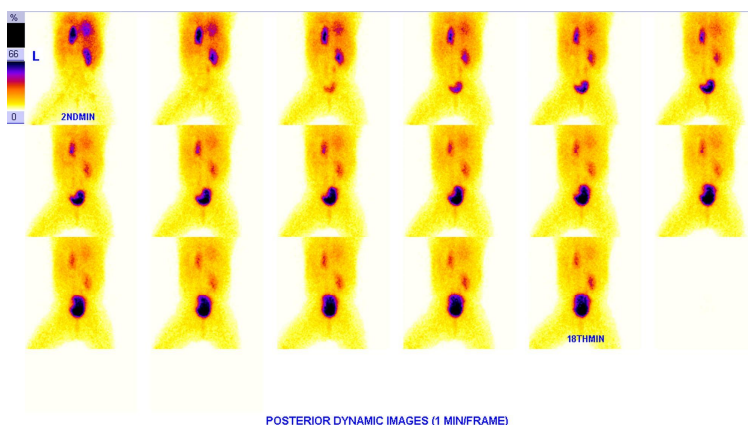


Fig 1. Posterior dynamic images of ^{99m}Tc DTPA (Diethylene Triamine Penta Acetic acid) renogram were acquired at 2 sec/frame for 60 sec followed by 15 sec/frame for 20 min. Left kidney was found to be ectopically placed in thorax beside the heart. Right kidney was normally placed, normally functioning with no evidence of pelviureteric junction obstruction.

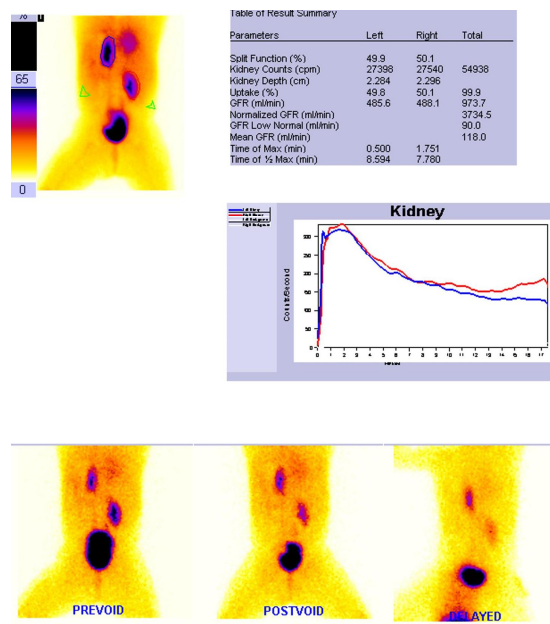


Fig 2. DTPA renogram shows bilaterally PUI non obstructed kidneys. Although the left kidney is intrathoracic in location it is posteriorly placed as evident from the images. Prevoid, post void and delayed images show no retention of tracer in pelvicalyceal system further confirming bilateral PUI non obstruction.

Patient has attained normal milestones. In view of the presentation a urinary tract infection was suspected. Clinical and routine urine microscopy examination was normal. Patient was subjected to an abdominal USG to rule out any intra abdominal cause of fever and also to further evaluate the kidneys as patient had

phimosis. USG reported normal right kidney with non visualization of left kidney. Child was then referred to us for a ^{99m}Tc-DTPA renogram to look for the presence of any ectopic or poorly functioning left kidney. Informed consent was obtained from parents for the study as normally done

for all routine investigations. An IV line was secured and oral sedation with Trichlofos at a dosage of 0.5-1 mg/kg body weight was administered. Once sedated, ^{99m}Tc-DTPA renogram was performed with 3 mCi of ^{99m}Tc-DTPA given intravenously under the gamma camera. Initial dynamic images (renal angiogram) were acquired at 2 sec/frame for 60 sec at 128 X 128 matrix, word mode followed by extraction phase images at the rate of 15 sec/frame for 20 min. Both anterior and posterior images were acquired using a dual head variable angle Gamma camera fitted with high resolution collimators. An ectopically placed, normally functioning Left kidney was seen in thorax just beside the heart on the left side. Right kidney was normally placed and normally functioning. Both the kidneys showed no evidence of any PUJ obstruction. (Fig. 1, 2). Simultaneously a Chest X-ray (PA view) was also performed. The classical findings as seen in Chest Xray in our patient were (i) visualization of herniated bowel loops in left hemithorax (ii) left hemidiaphragm was not seen separately (iii) tracheal and mediastinal shift was noted to the right (iv) lung fields were clear bilaterally (v) there was no associated pleural effusion (Fig. 3). Lateral view shows intestinal loops to be placed posteriorly in hemithorax thus confirming it as Bochdalek hernia.

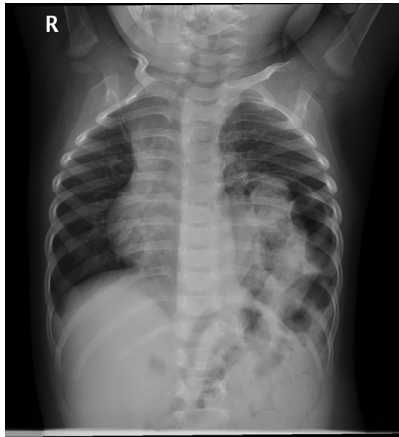


Fig 3. Chest X-ray PA view shows (i) herniated bowel loops in left hemithorax (ii) hemidiaphragm (left) is not separately seen (iii) trachea and mediastinum are shifted to the right (iv) lung fields are clear (v) no associated pleural effusion was seen.

DISCUSSION

CDH is classified into 3 types; posterolateral Bochdalek hernia (occurring in utero at approximately 6 weeks of gestation), anterior

Morgagni type of hernia, and hiatus hernia. Bochdalek hernias are congenital diaphragmatic defects arising due to failed closure of the pleuroperitoneal ducts during the 4th and 12th weeks of gestation, [7]. Bochdalek hernia, also called posterolateral diaphragmatic hernia, is the most common manifestation of CDH, accounting for more than 95% of cases. They tend to be unilateral but can be bilateral in 14% of cases, left sided hernias are five times more frequent than the right, probably because of earlier closure of the right pleuroperitoneal canal than the left. If the pleuroperitoneal canal remains open when the intestinal loops return to the abdomen from the umbilical cord during the 10th week, the abdominal viscera move freely into the thoracic cavity. If the pleuroperitoneal canal closes but fails to become muscularized, a hernia with a sac results, as is seen in 10% to 15% of patients with CDH, [8].

Diaphragmatic hernias were recognized as far back as the late 17th century. Vincent Alexander Bochdalek in 1848, [8] first described the non-fusion of the posterol-lateral foramina of the diaphragm. Majority of Bochdalek hernias are diagnosed acutely in neonates and infants with associated respiratory symptoms. Apart from pulmonary hypoplasia, these patients develop severe respiratory complications due to pulmonary hypertension.

Intrathoracic kidney is a very rare anomaly with reported incidence of 1 in 16,000 populations while CDH has a reported incidence of 1 in 2500 & 1 in 4000 live births, [9,10]. Intrathoracic kidney constitutes 5% of all ectopic kidneys. Kidneys when pass through a defect in the diaphragm into the thorax may get malrotated, or may have a unipolar deviation and may have a long ureter. They usually do not enter into the pleural cavity. Unlike pelvic kidneys, intrathoracic kidney is invariably PUJ non obstructed [11].

The diagnosis of CDH is usually confirmed by a plain chest radiograph that demonstrates loops of intestines in chest [12]. Historically, management of CDH was immediate surgery, but over a period of time it was realized that immediate surgery may not be needed and hence intubation, oxygenation and extracorporeal membrane oxygenation (ECMO) was introduced. Literature review shows liver, spleen and bowels to be involved in CDH, however rarely heart and liver have also been noted in the hernial contents. Quarless et al incidentally identified bochdalek hernia during ^{99m}Tc-SestaMIBI parathyroid imaging, [13]. In our patient, ^{99m}Tc-DTPA renogram first guided the pediatrician to look for CHD that was confirmed to be left sided bochdalek hernia by a simple chest X-ray. Thus judicious use of imaging modalities can help in averting morbidity in newborn

period by early identification of grave congenital anomalies as highlighted by this case.

REFERENCES

1. Angulo JC, Lopez JI, Vilanova JR, Flores N. Intrathoracic kidney and vertebral fusion: a model of combined misdevelopment. *J Urol.* 1992 May;147(5):1351-3.
2. Arafah M, Boqari DT, Alsaad KO. Left-sided congenital diaphragmatic hernia with multiple congenital cardiac anomalies, hernia sac, and microscopic hepatic heterotopia: a case report. *Patholog Res Int.* 2011 Mar 15;9:67107.
3. Sweed Y, Puri P. Congenital diaphragmatic hernia: influence of associated malformations on survival. *Arch Dis Child.* 1993 Jul;69(1 Spec No):68-70.
4. Ohta H, Kohno K, Kojima N, Ihara N, Ishigaki T, Todo G, Komibuchi T. A case of diaphragm hernia containing accessory spleen and great omentum detected by Tc-99m phytate scintigraphy. *Ann Nucl Med.* 1999 Oct;13(5):347-9.
5. Shah AD, Ajay S, Adalia M, Rathi A. Bochdalek hernia with intrathoracic kidney. *Lung India.* 2012 Oct;29(4):373-5.
6. Bláhová K., Šnajdauf J., Tůma S., Černý M., Jančíková B., Janda J. Intrathoracic kidney renal ectopy. *Čes-slov Pediat* 2001; (10): 590-3.
7. Kluth D, Keijzer R, Hertl M, Tibboel D. Embryology of congenital diaphragmatic hernia. *Semin Pediatr Surg.* 1996 Nov;5(4):224-33.
8. Salaçin S, Alper B, Cekin N, Gülmen MK. Bochdalek hernia in adulthood: a review and an autopsy case report. *J Forensic Sci.* 1994 Jul;39(4):1112-6.
9. Wenstrom KD, Weiner CP, Hanson JW. A five-year statewide experience with congenital diaphragmatic hernia. *Am J Obstet Gynecol.* 1991 Oct;165(4 Pt 1):838-42.
10. Langham MR Jr, Kays DW, Ledbetter DJ, Frentzen B, Sanford LL, Richards DS. Congenital diaphragmatic hernia. Epidemiology and outcome. *Clin Perinatol.* 1996 Dec;23(4):671-88.
11. Donat SM, Donat PE. Intrathoracic kidney: a case report with a review of the world literature. *J Urol.* 1988 Jul;140(1):131-3.
12. Haller JA Jr. Professor Bochdalek and his hernia: then and now. *Prog Pediatr Surg.* 1986;20:252-5.
13. Quarless SA, Wells CN. Bochdalek hernia, incidental finding on sestamibi parathyroid scan. *Clin Nucl Med.* 2005 Jun;30(6):436-9.