

## Evaluation of lacrimal drainage system by radionuclide dacryoscintigraphy in patients with epiphora

Sagili Chandrasekhara Reddy<sup>1,2</sup>, Ahmad Zakaria<sup>3</sup>, Venkata Muralikrishna Bhavaraju<sup>3</sup>

<sup>1</sup> Department of Ophthalmology, School of Medical Sciences, University Sains Malaysia, Kubang Kerian, Kelantan, Malaysia

<sup>2</sup> Department of Ophthalmology, Faculty of Medicine and Defence Health, National Defence University of Malaysia, Kem Sungai Besi, Kuala Lumpur, Malaysia

<sup>3</sup> Department of Nuclear Medicine, Radiotherapy and Oncology, School of Medical Sciences, University Sains Malaysia, Kubang Kerian, Kelantan, Malaysia

(Received 4 August 2015, Revised 6 November 2015, Accepted 8 November 2015)

### ABSTRACT

**Introduction:** This study was done to determine the site of obstruction in lacrimal drainage system in Asian patients suffering from epiphora and to determine the transit time taken for the tracer material to reach the lacrimal sac and the nasal cavity.

**Methods:** Dacryoscintigraphy was performed using radionuclide technetium-99m pertechnetate (<sup>99m</sup>Tc) in 34 patients suffering from unilateral or bilateral epiphora and in 3 cases of post-operative dacryocystorhinostomy. The site of obstruction was noted during the dynamic scintigraphy procedure. The time taken for the tracer material to reach the lacrimal sac in all the eyes and the nasal cavity in the eyes with patency of nasolacrimal duct was determined.

**Results:** Complete obstruction of nasolacrimal duct (NLD) was noted in all 22 unilateral cases. However, in 4 of the contralateral asymptomatic eyes in these patients complete obstruction of NLD was detected. Out of 12 bilateral cases, complete obstruction of NLD was noted in both eyes in 4 cases, and in one eye only in 8 cases. There was partial obstruction of NLD in the other eye in these 8 patients. The mean transit time taken for the tracer material to reach the lacrimal sac was 8 seconds (range 5 – 14 seconds) and to the nasal cavity was 6 minutes 20 seconds (range 2 minutes 16 seconds – 12 minutes).

**Conclusion:** This non-invasive procedure helps in the diagnosis of partial obstruction of NLD which can be missed by syringing procedure. The time taken for the tears to drain into the nasal cavity can also be measured in eyes with patent nasolacrimal duct by this procedure.

**Key words:** Technetium-99m; Epiphora; Dacryoscintigraphy; Nasolacrimal duct obstruction; Dacryocystorhinostomy

**Iran J Nucl Med 2016;24(2):99-106**

Published: July, 2016

<http://irjnm.tums.ac.ir>

**Corresponding author:** Dr. Sagili Chandrasekhara Reddy, Faculty of Medicine and Defence Health, National Defence University of Malaysia, Kem Sungai Besi, 57000 Kuala Lumpur, Malaysia. E-mail: [profscreddy@gmail.com](mailto:profscreddy@gmail.com)

## INTRODUCTION

Watering of eyes is one of the common eye problems seen by ophthalmologists in their daily practice. Patients with epiphora (pathological overflow of tears) will have partial or complete obstruction somewhere in the lacrimal drainage system (punctum, canaliculus, lacrimal sac, nasolacrimal duct). The assessment of the drainage system is done by slit lamp examination for punctum opening and by syringing the lacrimal sac to determine the level of obstruction. The documentation of nasolacrimal duct (NLD) obstruction can be done by contrast dacryocystography. The major disadvantages of syringing procedure and contrast dacryocystography are (1) they are invasive since the canaliculi are instrumented, (2) the result may be false positive by opening the partial obstruction in the NLD as the saline or contrast dye is injected manually by applying pressure during the procedure.

A non-invasive, functional and morphological documentation of tear flow through lacrimal passages was introduced by Rossomondo et al. using radionuclide technetium-99m pertechnetate ( $^{99m}\text{Tc}$ ) and gamma camera by observing the tear flow through lacrimal drainage system and taking series of images [1]. This procedure of imaging different parts of lacrimal drainage system has been described in the literature as microscintigraphy [2], nuclear dacryocystogram [3], lacrimal scintillography [4], nuclear lacrimal scan [5] and lacrimal dacryoscintigraphy [6] and radionuclide dacryoscintigraphy [7].

Cuthberston and Webber conducted a survey among ophthalmologists in Southwest England and reported that only 3% of respondents requested dacryoscintigraphy regularly and 84% rarely or never used it in evaluating epiphora in the absence of clinically obvious nasolacrimal duct obstruction; 13% used dacryocystography regularly [8]. This may probably be due to lack of availability/ facility of dacryoscintigraphy in that region. In a similar North American survey, Nagi and Meyer reported that 76% never used dacryoscintigraphy and only 1% used it often, while 55% of respondents never used dacryocystography and 45 used it often [9].

The literature search (Pubmed, Science direct and Google scholar) showed many reports from western countries, but only two from Asian countries [2, 10]. Therefore, this study was undertaken to determine (1) the site of obstruction in Asian patients suffering from epiphora using radionuclide ( $^{99m}\text{Tc}$ ) dacryoscintigraphy investigation and (2) to determine the transit time taken for tracer material to reach the lacrimal sac and the nasal cavity by visual interpretation of images in the asymptomatic eyes with patency of nasolacrimal duct.

## METHODS

### Study population

Thirty four patients attending the eye clinic of teaching hospital of a university medical school, with the complaint of unilateral or bilateral watering of eyes were included in this study. The patients with acute inflammatory diseases of the eye, canaliculitis, trichiasis, entropion, ectropion, lagophthalmos which result in watering of the eye were excluded from the study. The asymptomatic, unaffected eye of the patients with unilateral epiphora, undergoing this investigation was considered for measuring the time taken for tracer material to reach the lacrimal sac and the nasal cavity. This cross sectional prospective study was conducted over a period of two years. This study was approved by Ethics committee of the school of medicine/university teaching hospital.

All the patients underwent syringing of lacrimal sac procedure in the eye clinic on the day of first visit; then were subjected to dacryoscintigraphy at a later date when the appointment was given by nuclear medicine department. After explaining the purpose and procedure, an informed consent was taken from all the patients before the date was given for nuclear dacryoscintigraphy procedure.

Dacryocystorhinostomy was performed in one of the eyes in three patients with bilateral epiphora and postoperative dacryoscintigraphy was done after three weeks (after complete healing) in these three eyes to assess the patency of the opening made during surgery.

### Nuclear dacryoscintigraphy (NDS)

The procedure was performed on an outpatient basis in the nuclear medicine department. Technetium-99m was chosen because of its availability in nuclear medicine department, relatively low energy gamma (140 keV), short half-life (six hours), and lack of any particulate radiation which would increase the radiation dose to the eye [1]. The patient was seated comfortably on a chair in front of low energy high resolution collimator gamma camera (Toshiba GCA 901 A/HG, Tokyo, Japan), with chin and nose touching the gamma camera. The positions of right eye, left eye and nose were marked on the surface of camera for positioning the patient.

One drop of 100  $\mu\text{Ci}$ , (3.70 MBq) of  $^{99m}\text{Tc}$  radioactive tracer (calculated on Autolab 100 dose calibrator after diluting in sterile normal saline) was instilled into the lower fornix of the affected eye first and then into the lower fornix of the control eye, using insulin syringe without the needle. Immediately, the patient was positioned on the gamma camera. Patient was instructed to remain still

without moving the head and blink normally throughout the procedure to facilitate the lacrimal pump action.

Serial dynamic images of tear flow at 1 second x 16, at 20 seconds x 16 and at 30 seconds x 16 frames were taken during the procedure. A delayed frame of the procedure was taken every 1 minute for 5 minutes (whenever required) to confirm any partial obstruction of NLD. The pictures were stored in the computer and printed on x-ray plates for visual interpretation (reviewing the images in the x-ray plates and counting the time for the tracer to reach the lacrimal sac and nasal cavity in the series of images which was easy and accurate) of the results of the dacryoscintigraphy and the transit time taken for the  $^{99m}\text{Tc}$  to reach the lacrimal sac (TLS) and the nasal cavity (TNC).

### Measurement of transit times

*Transit time to lacrimal sac (TLS):* the time taken for tracer material to reach lacrimal sac in all the lacrimal systems investigated (up to the image showing first appearance of tracer material in the lacrimal sac) was measured in seconds, by reviewing the images in the x ray plates.

*Transit time to nasal cavity (TNC):* the time taken for tracer material to reach the nasal cavity in the lacrimal systems showing patency of nasolacrimal duct (up to the image showing first appearance of tracer material in the nasal cavity after exit from the nasolacrimal duct) was measured in seconds and converted into minutes and seconds, by reviewing the images in the x ray plates.

### Interpretation of images of NDS

*Patency of NLD* was diagnosed by visualisation of the radioactive tracer material filling up the lacrimal sac/ nasolacrimal duct and appearance of the tracer material in the nasal cavity.

*Complete obstruction of NLD* was diagnosed by visualisation of persistent pooling of the radioactive tracer material in the lacrimal sac/ nasolacrimal duct and absence of the tracer material in the nasal cavity.

*Partial obstruction of NLD* was diagnosed by visualisation of faint appearance of nasolacrimal duct with the appearance of radioactive tracer material in the nasal cavity in the last images of third series of the procedure.

## RESULTS

Nuclear dacryoscintigraphy was performed in 34 patients of epiphora; 22 (64.7%) patients complained of watering in one eye (unilateral) and 12 (35.3%) in both eyes (bilateral). Twenty eight patients (82.4%) were women and six (17.6%) were men. The mean age of the patients was 53.2 years with a range between 17 and 78 years. There were 23 Malays, 10 Chinese and one Indian patient in this study.

The site of obstruction in the drainage system was diagnosed by seeing the dynamic flow of the  $^{99m}\text{Tc}$  tracer material through the canaliculi, lacrimal sac, nasolacrimal duct into the nasal cavity and also by reviewing the images in the x ray plates. This is simpler to perform and can be reviewed again anytime by viewing all the images of the flow of tracer in the x-ray plates. There was no blockage of upper or lower canaliculus, or common canaliculus of either eye in any patient since the radioactive tracer material was seen in the lacrimal sac in all the lacrimal systems (68) investigated in this study.

Out of 68 lacrimal systems, complete obstruction of NLD was noted in 61.8%, partial obstruction of NLD in 11.8%; while patency of NLD was seen in 26.4% (Table 1). Complete obstruction of NLD was observed in 82.6% (38 out of 46) of symptomatic eyes, while the same was seen in 18.2% (4 out of 22) of asymptomatic eyes. The p value was found to be less than 0.001 using the Pearson's chi-square goodness-of-fit test. That means, p value is less than 0.05 which is significant level indicating that there is significant difference of having complete obstruction of NLD between symptomatic eyes and asymptomatic eyes. (Chi-square value (df) = 41.832 (1).

**Table 1:** The analysis of results of nuclear dacryoscintigraphy in 68 eyes.

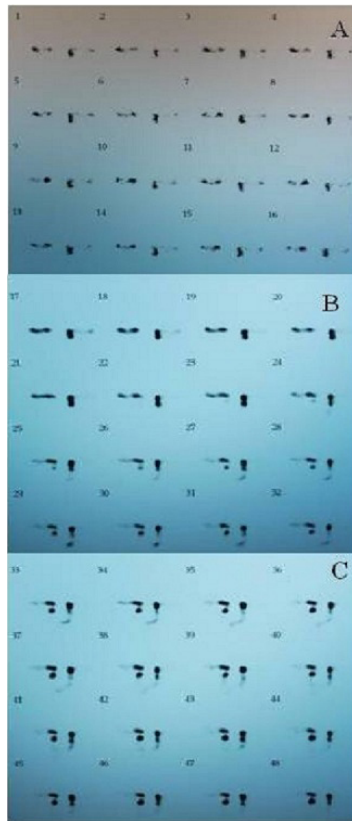
Eye involved	No. of eyes	No. with COND*	No. with POND*	No. with PND*
Unilateral (22 patients)				
Symptomatic	22	22 (100%)	--	--
Asymptomatic eyes	22	4 (18.2%)	--	18 (81.8%)
Bilateral (12 patients)				
Symptomatic eyes	24	16 (66.7%)	8 (33.3%)	--
	68	42 (61.8%)	8 (11.8%)	18 (26.4%)

\*COND: Complete obstruction of nasolacrimal duct; POND: Partial obstruction of nasolacrimal duct; PND: Patent nasolacrimal duct

The syringing procedure was done in all the symptomatic eyes (bilateral or unilateral) with epiphora and was positive for NLD obstruction in all the eyes. In asymptomatic eyes it was not done. However, 4 of these eyes showed complete obstruction of nasolacrimal duct in dacryoscintigraphy procedure.

Dacryocystorhinostomy was performed on one side in three patients with bilateral epiphora. Post-operative radionuclide dacryoscintigraphy was repeated in these patients after three weeks to see the patency of the ostium and drainage into the nasal cavity which showed success of the operation (evidence of faster flow of the tracer material into the nose) in all the three eyes.

The serial images of the procedure of nuclear dacryoscintigraphy at different time intervals are shown in Figure 1.



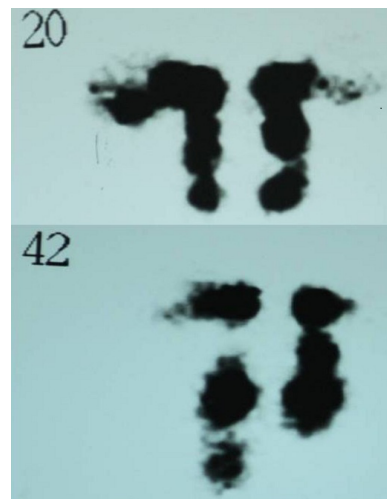
**Fig 1.** The serial images of dynamic nuclear dacryoscintigraphy of both eyes: (A) every 1 second x 16 frames ---  $^{99m}\text{Tc}$  tracer material entering into the lacrimal sac on the left side only; (B) every 20 seconds x 16 frames --- tracer material entering into the lacrimal sac on both sides and started draining into the nose on the left side; (C) every 30 seconds x 16 frames --- tracer material drained into the nose on left side indicating patency of nasolacrimal duct, but no drainage of tracer into the nose on right side indicating obstruction of nasolacrimal duct.

The images of obstruction of NLD on one side and patency of NLD on the other side are shown in Figure 2.



**Fig 2.**  $^{99m}\text{Tc}$  tracer material in the lacrimal sac and nasolacrimal duct on the right side in the frame 40 (8 minutes and 56 seconds) indicating obstruction of nasolacrimal duct. However, the tracer material is seen draining into the nose on the left side indicating patency of nasolacrimal duct.

The pooling of tracer material in NLD only without draining into the nasal cavity on one side (even in late image) and partial obstruction of NLD on the other side are shown in Figure 3.



**Fig 3.** (A)  $^{99m}\text{Tc}$  tracer material in the lacrimal sac and nasolacrimal duct on both sides in frame 20 (1 minute 36 seconds) in a case of bilateral epiphora; (B) in the late frame 42 (10 minutes 36 seconds), the tracer material is seen draining into the nose on the right side only indicating partial obstruction of nasolacrimal duct.

The readings (time taken for tracer material to reach lacrimal sac - TLS) of all 68 lacrimal systems were added and the mean transit time to reach the sac was calculated. The mean transit time was 8 seconds (range 5-14 seconds).

**Table 2:** The time taken by the tracer material Tc<sup>99m</sup> to reach the lacrimal sac of right eye (TLS-R) and left eye (TLS-L) in 68 eyes, and the time taken to reach the nasal cavity (TNC) in 18 eyes with patent nasolacrimal duct.

Patient number	TLS-R*	TLS-L*	TNC*
1	9 seconds	11 seconds	Right (12 minutes)
2	10 seconds	16 seconds	Right (8 minutes)
3	9 seconds	14 seconds	Right (6 minutes)
4	9 seconds	9 seconds	Left (12 minutes)
5	6 seconds	16 seconds	Right (3 minutes 16 seconds)
6	6 seconds	6 seconds	---
7	6 seconds	6 seconds	Left (3 minutes 16 seconds)
8	7 seconds	6 seconds	---
9	12 seconds	12 seconds	---
10	6 seconds	6 seconds	Right (9 minutes 16 seconds)
11	5 seconds	5 seconds	Left (6 minutes 36 seconds)
12	6 seconds	6 seconds	Left (5 minutes 36 seconds)
13	10 seconds	10 seconds	---
14	6 seconds	6 seconds	---
15	14 seconds	14 seconds	---
16	6 seconds	7 seconds	Right (7 minutes 36 seconds)
17	7 seconds	5 seconds	Left (6 minutes 36 seconds)
18	9 seconds	6 seconds	---
19	6 seconds	6 seconds	---
20	6 seconds	9 seconds	---
21	6 seconds	6 seconds	Left (3 minutes 36 seconds)
22	8 seconds	8 seconds	---
23	5 seconds	5 seconds	---
24	5 seconds	5 seconds	Right (2 minutes 16 seconds)
25	12 seconds	12 seconds	Right (7 minutes 36 seconds)
26	7 seconds	7 seconds	Left (11 minutes 36 seconds)
27	14 seconds	13 seconds	---
28	6 seconds	7 seconds	Right (11 minutes 36 seconds)
29	5 seconds	5 seconds	---
30	5 seconds	6 seconds	Left (4 minutes 16 seconds)
31	8 seconds	8 seconds	---
32	5 seconds	5 seconds	---
33	5 seconds	4 seconds	Right (3 minutes 56 seconds)
34	6 seconds	6 seconds	---

\*TLS-R: Time taken to reach lacrimal sac-right; TLS-L: Time taken to reach lacrimal sac- left; TNC: Time taken to reach the nasal cavity

Similarly, the readings (time taken for tracer material to reach the nasal cavity - TNC) of 18 contralateral, asymptomatic eyes with patent NLD were added and the mean transit time was calculated. The mean transit time for tracer to reach nasal cavity was 6 minutes 20 seconds (range 2 minutes 16 seconds - 12 minutes) (Table 2).

In postoperative cases, the pooling of the radioactive tracer material was seen in the nasal cavity in 116 seconds (1 minute 56 seconds) in one patient, in 136 seconds (2 minutes and 16 seconds) in second patient, and in 96 seconds (1 minute 36 seconds) in third patient. These cases are not included in the transit time to the nasal cavity because the ostium made during the operation is much larger and not same as the opening of nasolacrimal duct. The variation in time could probably be due to size of the bony ostium which was made during the operation in these cases.

### DISCUSSION

In nuclear dacryoscintigraphy (NDS), the drop of <sup>99m</sup>Tc instilled into the conjunctival sac spreads over

the globe of the eye by capillary action. The tears containing the tracer material flow through the canaliculi in a few seconds reaching the lacrimal sac and finally passing slowly through the nasolacrimal duct into the nasal cavity. The functional integrity of lacrimal drainage is assessed by visualizing the dynamic flow of the radioactive tracer material captured by the gamma camera on the computer screen. The transit time to lacrimal sac represents the evaluation of tear drainage from the conjunctival sac to the lacrimal sac, while the transit time to the nasal cavity represents the evaluation of the tear drainage from the lacrimal sac through the nasolacrimal duct to the inferior meatus of the nasal cavity [2, 11].

The advantages of NDS over contrast dacryocystography are (1) it is non-invasive and simple to perform, (2) it can be done easily in any age group, avoiding general anaesthesia in children, (3) the assessment of tear drainage is more physiological, (4) the exposure of radiation to the eye is minimal, (5) the dynamic studies are possible, (6) the follow up studies are easy to perform and comparison is accurate, (7) the suspected abnormal

side can be compared with the clinically normal side since both lacrimal passages can be imaged simultaneously during the procedure, and (8) there is no discomfort to the patient since this procedure does not require catheterization of canaliculi.

The disadvantages of NDS are (1) high cost gamma camera is essential to do this procedure, unlike skull x-ray table in the case of dacryocystography which is available in any hospital, (2) high cost of  $^{99m}\text{Tc}$  when compared to contrast iodine dye used in dacryocystography, (3) facility for diluting the radioactive tracer material to  $100\mu\text{Ci}$ , and (4) nuclear medicine department in the hospital.

Since the canaliculi are not instrumented in this procedure and the radioactive material is diluted in a sterile normal saline solution, the natural physiologic dynamics of the lacrimal drainage system are maintained. Neither short term nor long term complications following this procedure have been reported in the available literature except one case. Recently, Ayati et al. reported a case of  $^{99m}\text{Tc}$  uptake in thyroid gland due to systemic absorption of the tracer from the conjunctiva in one patient with bilateral obstruction of NLD and they recommended using tracers with large particle size to decrease mucosal absorption [12].

The radiation dose during dacryocystography has been estimated to be 3000 m rads as compared to 370 m rads when an anterior-posterior x-ray of the skull is obtained. In comparison, the absorbed radiation dose to the lens in the eye during the scintigraphy procedure is only 4- 14m rads/  $100\mu\text{Ci}$   $^{99m}\text{Tc}$  under normal physiological conditions. The radiation dose could increase to 40 m rads in the cases of lacrimal drainage obstruction [1, 13].

In a study of 103 lacrimal systems investigated for subtraction macrodacryocystography and 105 systems for lacrimal scintigraphy in patients of epiphora, Amanat et al. recommended that lacrimal scintigraphy should be performed first and if the site of obstruction is still uncertain, then only dacryocystography should be performed, in view of the significant radiation dose to the lens in macrodacryocystography [14].

In view of the above data, NDS is considered superior to dacryocystography. Moreover, a temporary block of lacrimal drainage system by mucus plug or other debris, block due to anomalous valve of Krause or valve of Taillefer in the nasolacrimal duct would go unnoticed by syringing or contrast dacryocystography. However, these types of anatomical blocks can often be detected by dacryoscintigraphy since it is a physiological test [3, 6].

Heyman et al. performed dacryoscintigraphy in 34 patients aged between 13 months and 20 years. Of the 74 lacrimal systems, the findings were in agreement with clinical observation in 63 (34 abnormal and 29 normal); in nine cases, the clinical management was altered after this investigation and in two case it was inconclusive [15].

In our study of 22 unilateral epiphora patients, there were 18 asymptomatic patients with patent NLD and in these eyes the transit time to the lacrimal sac and to the nasal cavity was calculated by visual interpretation of the images on the X ray plates. The mean transit time to the lacrimal sac was 8 seconds (range 5 -14 seconds) and mean transit time to the nasal cavity was 6 minutes 20 seconds (range 2 minutes 16 seconds – 12 minutes). Studies from the literature on asymptomatic individuals showed a great variation in the transit time to lacrimal sac and to nasal cavity and the values observed in our study are within the above range (Table 3).

There is lack of normative data for lacrimal scintigraphy with studies reporting up to 40% of asymptomatic individuals have abnormalities with variability in tracer times [17].

In the quantitative assessment of dacryoscintigraphic images in the evaluation of epiphora, Gholamrezaezhad et al. have taken the asymptomatic eyes in unilateral cases as controls [18]. Similarly, in our study we utilized the asymptomatic eyes in unilateral cases to measure the transit time to lacrimal sac and to nasal cavity in the eyes with patent nasolacrimal duct.

**Table 3:** The transit time to lacrimal sac and nose in asymptomatic individuals reported in the published literature.

Author	Transit time to lacrimal sac	Transit time to nasal cavity
Carlton et al [2]	mean 6s (4- 43s)	mean 43s (4- 423s) NLD
Chaudhury et al [3]	---	8-10 m
Hurwitz et al [4]	mean 5.2m (1-15m)	mean 1.1m (0.25- 3m)
Kadambi & Williams [7]	8-11s	---
Chavis et al [11]	mean 7.5s (6-18s)	30 s to unknown time
Brizel et al [16]	0-120s	1-15m (NLD)
Present Study	8s (5-14s)	6 m 20s (2m 16s)

s= seconds; m= minutes; figures in parenthesis indicate range; NLD= nasolacrimal duct

This wide variation of transit times may presumably be due to variation in the frequency and intensity of blinking, gravity, changes in the volume of tears produced, variations in the tear flow, resistance offered by several valves in the drainage system affecting the tear flow, other factors such as emotion, irritation of conjunctiva and volume of the radionuclide instilled [7, 19]. In both their studies, there was difficulty in quantitating the time taken for tracer material to reach the nose (which was inconsistent) because of the above possible factors. Whatever the variables are, one should visualize the radioactive material in the nasal cavity within 8-10 minutes. More than 10 minutes indicates delayed drainage [3]. The transit time through the distal part of the nasolacrimal duct and into the nasal cavity is extremely variable in normal individuals [2, 20].

In our study, there was no blockage of canaliculi or common canaliculus of either eye in any patient since the radioactive tracer material was seen in the lacrimal sac in all the lacrimal systems of patients. The probable reason could be the exclusion of patients with any inflammatory disease in the eye for this study, and the small number of patients in this study. In a study of 620 lacrimal systems of patients with epiphora, Amanat et al. [19] reported 39% of complete canalicular obstruction and 24% of partial canalicular obstruction.

Some patients have symptoms of epiphora and the lacrimal syringing test will show patency of NLD because the saline is pushed manually with pressure while performing the procedure and fluid comes into nasopharynx and then into throat. This is termed as "functional" obstruction. In such cases, dacryocystography will also show erroneous result of patency of NLD because it is similar to lacrimal syringing except radioactive dye is injected instead of saline. Since radionuclide dacryoscintigraphy is a more physiological test, it will show abnormal in patients with functional NLD obstruction in terms of delayed appearance of tracer material into the nose [3, 6]. This can be compared with the other side quickly because both sides are captured by the gamma camera simultaneously. Therefore, dacryoscintigraphy procedure appears to be superior in the diagnosis of partial stenosis or physiological delay in tears reaching lacrimal sac (lacrimal pump failure) cases.

Wearne et al. reported the Comparative results of dacryocystography and lacrimal scintigraphy in the diagnosis of functional nasolacrimal duct obstruction was in 32 patients (45 lacrimal systems). Abnormalities were detected with dacryocystography in 93% of systems and with lacrimal dacryoscintigraphy in 95% of systems. They concluded that a combination of the two techniques

gives the highest sensitivity with maximum anatomical and physiological information [21]. Al-Ghamidi and El-Saban performed lacrimal scintigraphy before dacryocystography and detected all the obstruction in 100% (76 out of 76) symptomatic eyes, while dacryocystography could detect obstruction in 72.4% (57 out of 76) in these eyes [22].

In the present study, complete obstruction of NLD was detected in 18.2% (4 out of 22) of contralateral asymptomatic eyes (lacrimal systems) in unilateral epiphora patients. However, the same observation was reported in 9.1% (2 out of 22) of asymptomatic eyes by Al-Ghamidi and El-Saban [22] and in 8% (21 out of 624) of asymptomatic eyes by Amanat et al. [23].

In our study, the postoperative (dacryocystorhinostomy) evaluation was done in three cases and the transit time to the nose was much faster than in asymptomatic eyes with patent NLD, indicating the sufficiently patent ostium in all the cases. Kadambi and Williams have reported that nuclear dacryoscintigraphy was found to be useful to evaluate the success of dacryocystorhinostomy and further help to plan surgery in cases that needed another surgery in patients with failed procedure [2]. Palaniswamy and Subramanyam performed technetium pertechnetate dacryoscintigraphy to evaluate the postoperative (dacryocystorhinostomy) epiphora and concluded that this simple and easy to perform procedure helps in detecting subclinical and partial lacrimal duct obstruction with good patient compliance [10].

### Limitations

The limitations of this study are that dacryocystography was not performed in these patient to compare the results of sensitivity between the two procedures in the diagnosis of site of obstruction in the lacrimal drainage system in patients with epiphora.

### CONCLUSION

The partial obstruction of nasolacrimal duct or physiological delay in tears reaching the sac (lacrimal pump failure) will demonstrate very late appearance of radioactive tracer in the nasal cavity. These can be diagnosed easily by this non-invasive procedure, which can be missed by syringing the lacrimal sac procedure. It is a useful tool to assess the postoperative success of dacryocystorhinostomy in these patients. The time taken for the tears to drain into the nasal cavity can also be measured in eyes with patent nasolacrimal duct by this procedure.

### Acknowledgements

The authors are thankful to the University Sains Malaysia authorities for the short term research grant (No. 331-0500-3089) and all the staff of the nuclear medicine department for their help in carrying out this work.

### REFERENCES

1. Rossomondo RM, Carlton WH, Trueblood JH, Thomas RP. A new method of evaluating lacrimal drainage. *Arch Ophthalmol.* 1972 Nov;88(5):523-5.
2. Carlton WH, Trueblood JH, Rossomondo RM. Clinical evaluation of microscintigraphy of the lacrimal drainage apparatus. *J Nucl Med.* 1973 Feb;14(2):89-92.
3. Chaudhuri RK, Saporoff GR, Dolan KD, Chaudhuri TK. A comparative study of contrast dacryocystogram and nuclear dacryocystogram. *J Nucl Med.* 1975 Jul;16(7):605-8.
4. Hurwitz JJ, Maisey MN, Welham RA. Quantitative lacrimal scintillography. I. Method and physiological application. *Br J Ophthalmol.* 1975 Jun;59(6):308-12.
5. Saporoff GR, Chaudhuri T, Chaudhuri T, Dolan KD, Christie JH. Nuclear lacrimal scan vs dacryoscintigraphy. *Trans Sect Ophthalmol Am Acad Ophthalmol Otolaryngol.* 1976 Jul-Aug;81(4 Pt 1):OP566-74.
6. von Denffer H, Dressler J, Pabst HW. Lacrimal dacryoscintigraphy. *Semin Nucl Med.* 1984 Jan;14(1):8-15.
7. Kadambi V, Williams BV. Functional integrity of lacrimal drainage apparatus by radionuclide dacryocystography. *Indian J Ophthalmol.* 1990 Jan-Mar;38(1):24-6.
8. Cuthbertson FM, Webber S. Assessment of functional nasolacrimal duct obstruction--a survey of ophthalmologists in the southwest. *Eye (Lond).* 2004 Jan;18(1):20-3 .
9. Nagi KS, Meyer DR. Utilization patterns for diagnostic imaging in the evaluation of epiphora due to lacrimal obstruction: a national survey. *Ophthal Plast Reconstr Surg.* 2010 May-Jun;26(3):168-71.
10. Palaniswamy SS, Subramanyam P. Dacryoscintigraphy: an effective tool in the evaluation of postoperative epiphora. *Nucl Med Commun.* 2012 Mar;33(3):262-7.
11. Chavis RM, Welham RA, Maisey MN. Quantitative lacrimal scintillography. *Arch Ophthalmol.* 1978 Nov;96(11):2066-8.
12. Ayati NK1, Malekshahi RG, Zakavi SR, Dabbagh Kakhki VR, Aryana K, Sadeghi R. Systemic absorption of Tc-99m-pertechnetate during dacryoscintigraphy: a note of caution. *Orbit.* 2010 Oct;29(5):269-70.
13. Robertson JS, Brown ML, Colvard DM. Radiation absorbed dose to the lens in dacryoscintigraphy with 99mTcO4-. *Radiology.* 1979 Dec;133(3 Pt 1):747-50.
14. Amanat LA, Wraight EP, Watson PG, Hawkins TD. Role of lacrimal scintigraphy and subtraction macrodacryocystography in the management of epiphora. *Br J Ophthalmol.* 1979 Jul;63(7):511-9 .
15. Heyman S, Katowitz JA, Smoger B. Dacryoscintigraphy in children. *Ophthalmic Surg.* 1985 Nov;16(11):703-9.
16. Brizel HE, Sheils WC, Brown M. The effects of radiotherapy on the nasolacrimal system as evaluated by dacryoscintigraphy. *Radiology.* 1975 Aug;116(02):373-81.
17. Sagili S, Selva D, Malhotra R. Lacrimal scintigraphy: "interpretation more art than science". *Orbit.* 2012 Apr;31(2):77-85.
18. Gholamrezanezhad A, Fard-Esfahani A, Sadeghi-Tari A, Mirpour S, Saghari M, Eftekhari M, Fallahi B, Beiki D, Poormoslemi A, Tarbiat A. Quantitative assessment of dacryoscintigraphic images in the evaluation of epiphora. *Orbit.* 2007 Dec;26(4):229-35.
19. Amanat LA, Hilditch TE, Kwok CS. Lacrimal scintigraphy. II. Its role in the diagnosis of epiphora. *Br J Ophthalmol.* 1983 Nov;67(11):720-8 .
20. Brown M, El Gammal TA, Luxenberg MN, Eubig C. The value, limitations, and applications of nuclear dacryocystography. *Semin Nucl Med.* 1981 Oct;11(4):250-7.
21. Wearne MJ, Pitts J, Frank J, Rose GE. Comparison of dacryocystography and lacrimal scintigraphy in the diagnosis of functional nasolacrimal duct obstruction. *Br J Ophthalmol.* 1999 Sep;83(9):1032-5.
22. Al-Ghamadi AA, El-Saban K. Clinical values of the lacrimal scintigraphy parameters in diagnosis of epiphora: comparison to dacryocystography. *Med J Cairo Univ.* 2011;79(2):13-22.
23. Amanat LA, Hilditch TE, Kwok CS. Lacrimal scintigraphy. III. Physiological aspects of lacrimal drainage. *Br J Ophthalmol.* 1983 Nov;67(11):729-32.