

## TESTICULAR SCINTIGRAPHY IN THE EVALUATION OF THE ACUTE SCROTUM

Daniel F Worsley, MD, Sydeny Heyman, MD, Lawrence E Holder, MD,  
and Abass Alavi, MD (Guest Editor)

Children Hospital of Philadelphia, Philadelphia, PA, USA

### ABSTRACT

Testicular scintigraphy has been well validated in the evaluation of patients with suspected testicular torsion and provides an accurate evaluation of testicular perfusion at the time of imaging. However, the presence of normal or increased perfusion to the testis does not definitively exclude the necessity for surgical intervention. A case of intermittent testicular torsion, with a review of testicular scintigraphy in the evaluation of the acute scrotum are presented.

Key words: spermatic cord torsion, radionuclide imaging; spermatic cord torsion, diagnosis; scrotal imaging; Technetium-99m pertechnetate; genitourinary tract abnormalities, radionuclide imaging

### CLINICAL HISTORY

A six-year-old boy with no previous medical problems developed sudden onset of left scrotal pain, associated with nausea and vomiting. He presented to the emergency room approximately 12 hours later in moderate distress. No other genitourinary symptoms were noted. In particular there was no history of dysuria, hematuria, frequency, discharge, previous scrotal pain or trauma. While waiting in the emergency room the left scrotal pain began to improve spontaneously. On physical examination the patient was afebrile with a resting heart rate of 104 beats per minute. Examination of the genitalia revealed a retracted and diffusely tender left testis. The right testis was also retracted but non-tender. Cremasteric reflexes were absent on both sides. The remainder of the physical examination was within normal limits. Laboratory evaluation including a complete

blood count and urinalysis were within normal limits. A testicular scan was ordered to evaluate the perfusion to the testes.

The testicular scan revealed nonspecific mild diffuse hyperemia of the left hemiscrotum, with no photon deficient areas to indicate absence of testicular perfusion at the time of imaging (Fig. 1a). Based on the clinical presentation and scintigraphic findings a tentative diagnosis of torsion of the appendix testis was made. However, a spontaneous detorsion could not be entirely excluded and the patient was discharged from the emergency room with a follow-up urology clinic appointment in one week. Over the next day the left scrotal pain continued to subside however, the pain recurred approximately 36 hours from the time of discharge. Unfortunately, medical attention was not sought until the following day. Testicular imaging at that time demonstrated a photopenic left testis with a hyperemic rim of activity compatible with mid

phase testicular torsion (Fig. 1b). At surgery a 720 degree torsion of the left testicle was identified. Initially the testis appeared dark and mottled. However, minimal improvement in the tissue color was noted following detorsion suggesting the possibility of a preserved blood supply. For this reason the testis was left in place and bilateral orchiopexies plus testicular biopsies were performed. On follow-up physical examination 6 months following the surgery the left testis was not palpable probably due to ischemic infarction.

### Pathological findings

On pathological examination the left testicular biopsy revealed infarcted tissue which was not suitable for morphometric studies. The germ cell count, maturation and leydig cell count of the right testicular biopsy was normal.

## DISCUSSION

This patient demonstrated a case of intermittent testicular torsion in which spontaneous detorsion occurred prior to testicular scintigraphy. The patient subsequently had a recurrent torsion of the testicle which ultimately resulted in infarction of the testis. In cases of spontaneous detorsion the testicular scan may appear normal or may demonstrate mild reactive hyperemia (1). However, the presence of normal or increased perfusion to the testis, which can be detected scintigraphically, does not definitively exclude the necessity for surgical intervention (2). Many patients with suspected intermittent torsion of the testicle and normal or increased scrotal perfusion will ultimately require surgery to prevent future occurrences. Testicular scintigraphy does however allow an evaluation of testicular perfusion at the time of imaging and provides information that the testis is not at immediate risk for infarction.

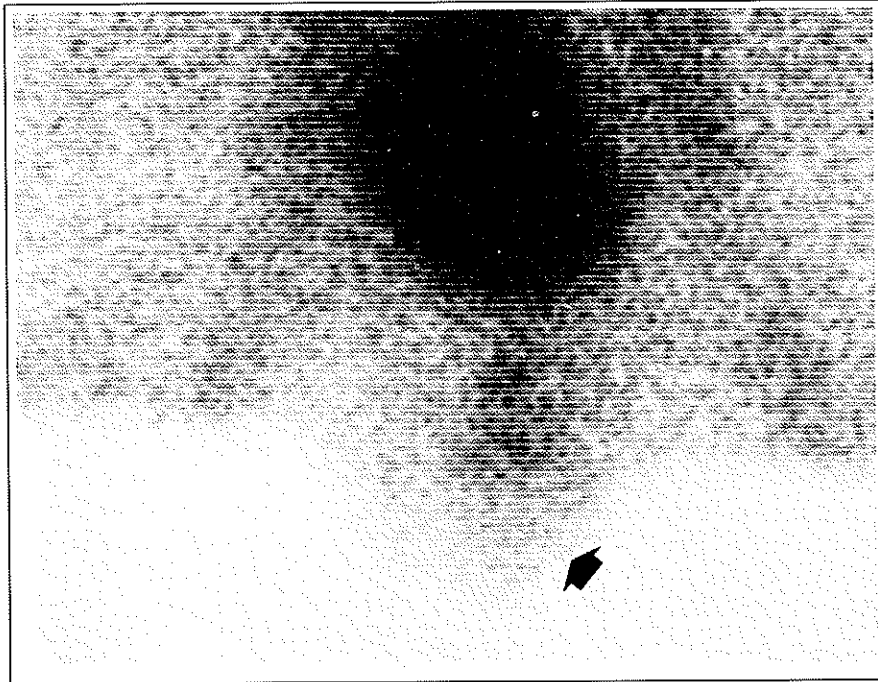
The spontaneous onset of acute hemiscrotal pain has long been recognized as a potential surgical emergency requiring prompt diagnosis and treatment. The most common causes of an acute hemiscrotum include: testicular torsion, epididymitis, epididymo-orchitis, torsion of an appendix testis and inflammation of spermatoceles, hydroceles and epididymal cysts (3). Since the viability of the involved testis is dependent on the duration of ischemia following torsion, the latter is considered a surgical emergency.

There are two distinct types of testicular torsion, neonatal or extravaginal intravaginal. Extravaginal torsion, which is the less common of the two, occurs as a result of twisting of the testis and tunica vaginalis occurring late in gestation or within the first few weeks of life. Clinically the affected hemiscrotum appears swollen, hard and nontender. Even when surgically explored on an urgent basis the scrotal contents are invariably found to be nonviable (4). Because of the certainty of the clinical diagnosis in most instances imaging studies, including testicular scintigraphy, has a very limited role in the management of extravaginal torsion. In contrast, intravaginal testicular torsion is a twisting of the testis around its vascular pedicle within the tunica vaginalis. In the normal testis the tunica vaginalis surrounds the testis except posteriorly where the testis attaches to the epididymis and scrotal wall. In patients who suffer intravaginal torsion the tunica vaginalis completely surrounds the testis and inserts high on the spermatic cord, thereby preventing posterior fixation of the testis (5,6). This "bell-clapper" anomaly predisposes the testis to rotate around the axis of the spermatic cord within the tunica vaginalis (7,8). While the bell clapper deformity is the most common anomaly predisposing to the testis to torsion, other anatomical factors such as long mesorchium have also been present.

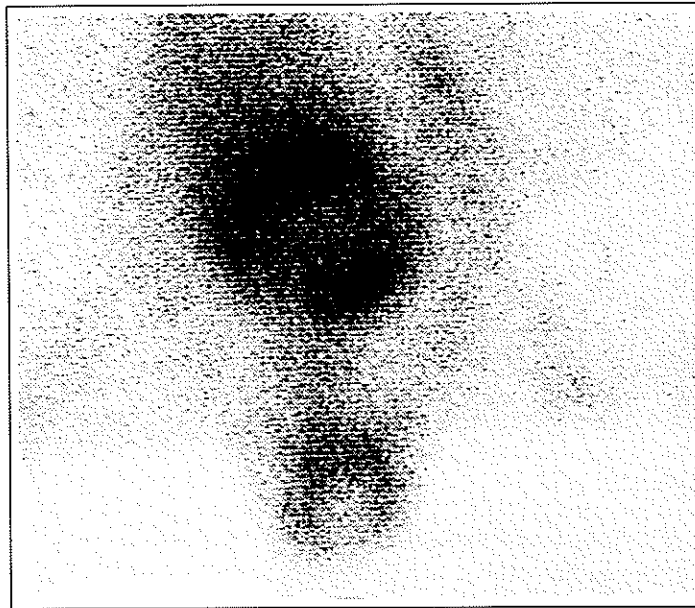
The prevalence of intravaginal testicular torsion has been estimated at one in every 4,000 males younger than 25 years and the majority of cases occur between the ages of 12 and 18 years (9). In selected patients the history, physical examination and laboratory investigations may be all that is required to decide whether surgical intervention is necessary. However, for as many as 50% of patients the diagnosis based on clinical findings and noncolor flow bedside doppler ultrasound examination are unreliable (10,11).

### Technique

Optimal utilization of testicular scintigraphy requires that the procedure must be available on an urgent basis. In addition, it is essential that every effort is made to obtain a technically acceptable study. The technique for performing testicular scintigraphy at the Children's Hospital of Philadelphia is described below. The patient is premedicated with 6 mg/kg of potassium perchlorate orally at least 10 minutes prior to injection. He is then positioned supine with his hips abducted under the gamma camera equipped with a parallel hole, all purpose collimator. The



**Figure 1a.** Anterior image from a 6-year-old boy demonstrating mild diffuse hyperemia of the left hemiscrotum indicating blood flow to the testis at the time of imaging. Based on the clinical presentation and scintigraphic appearance a tentative diagnosis of torsion of the appendix testis was made, however spontaneous detorsion could not be excluded.



**Figure 1b.** Anterior image of the scrotum obtained 3 days later demonstrating a photopenic left testis with surrounding hyperemia in the skin and dartos, compatible with late phase testicular torsion.

penis is taped onto the lower abdominal wall away from the region of interest. A gauze sling is used to support and position the scrotum so that it is immediately underneath the collimator and the median raphe is in the midline. Depending on the size of the region of interest, magnification factors of 2 to 3 times are usually employed in the acquisition parameters. Following intravenous injection of 740 MBq per 1.73 m<sup>2</sup> of Tc-99m pertechnetate dynamic acquisition is performed for 60 seconds at one second per frame onto a 64 by 64 image matrix. This is followed by a static image acquired for 500,000 counts into a 256 by 256 matrix. A second static image with a lead shield placed between the thigh and scrotum is then acquired in a similar fashion. An image with a line source or lead strip to mark the position of the raphe may be needed if the scrotum is displaced from the midline. A 100,000 count pinhole image is obtained in infants or when the testis is very small.

### Image interpretation

In the arterial phase of a normal study, activity is visualized within the iliac and femoral vessels which are clearly outlined, whereas activity associated with the normal, relatively minimal blood supply to the testis and scrotum is not usually demonstrated. In the static images scrotal activity appears homogenous with an intensity similar to that of the thigh. The characteristic scintigraphic appearances of testicular torsion have been described and depend on the time interval following the onset of symptoms (6). When perfusion to the testis is decreased as a result of acute testicular torsion (less than 6 hours following the onset of symptoms) the static images demonstrate decreased testicular activity in the affected side. Fig. 2 demonstrates a static image from a 16-year-old male who was awakened in the morning with sudden left testicular pain. The testicular scan obtained approximately 3 hours following the onset of symptoms reveals decreased activity in the region of the left testicle. At surgery bilateral bell-clapper anomalies and a 360 degree torsion of the left testicle were discovered and treated with bilateral orchiopexies. In mid-phase torsion (7-24 hours following the onset of symptoms) an area of decreased activity corresponding to the affected scrotum is again noted. In addition, reactive hyperemia in the dartos and skin are also present. Fig. 3 demonstrates an image from a 16-year-old male with an 18 hour history of left

testicular pain and swelling. The images demonstrate a photopenic area in the region of the left testis with reactive hyperemia in the surrounding skin and dartos. At surgery a 180 degree torsion of the left testicle was confirmed and subsequently salvaged. Fig. 4 presents a static image from a 15-year-old male who presented to the emergency room 36 hours following the onset of right testicular pain. The images demonstrate a well defined ring of increased activity in the skin and dartos surrounding an avascular testis. These findings are typical, although not specific of late phase (greater than 24 hours following the onset of symptom) torsion and at surgery an infarcted right testis was confirmed and removed. The scan findings in torsion of a testicular appendix may demonstrate normal or mildly increased activity in the affected hemiscrotum. Increased activity is usually noted superior to the testis and may be similar to that seen with focal epididymitis (Fig. 5). However, generalized increased activity within the scrotum associated with a photopenic defect corresponding to the appendix testis and generalized reduced perfusion to the testis have also been reported in cases of torsion of the testicular appendix (12,13).

Although, certain clinical and laboratory features are suggestive of epididymitis, it may not be possible to distinguish this entity from testicular torsion. Epididymitis is more common in adulthood, however adolescent and pre-pubertal boys, who have had no sexual contact, may also develop epididymitis (14,15). On testicular imaging epididymitis usually appears as a curvilinear area of increased activity lateral to the testis. If inflammation spreads to involve the testis (epididymo-orchitis) then the area of increased activity may also involve the testis (Fig. 6).

Testicular scintigraphy has been well validated as an examination which provides accurate information regarding testicular torsion. Lutzker and Zuckier have reviewed the results from studies published between 1983 and 1990 (1). The prevalence of testicular torsion in the studies reviewed was 19%. For technically adequate scans the sensitivity of testicular scintigraphy for detecting torsion was 96%, the corresponding specificity was 63% (1). False positive results have been reported in patients with epididymitis or when a scrotal mass (hydrocele or hernia) overlies the testis and causes attenuation of testicular activity (16,17). For this reason many urologists feel that testicular scintigraphy of the acute scrotum should be reserved for high risk




Figure 2. Anterior image from a 16-year-old man obtained 3 hours following the sudden onset of left testicular pain, reveals decreased perfusion in the region of the left testis compatible with acute testicular torsion.

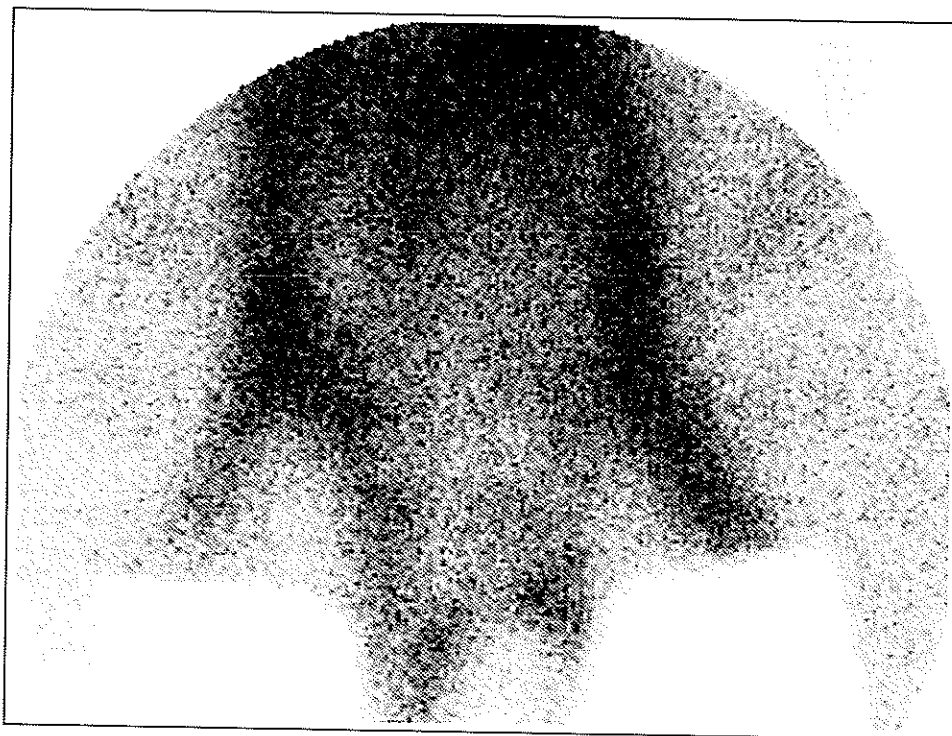


Figure 3. Anterior image from a 16-year-old man following an 18 hour history of acute left testicular pain and swelling, reveals a photopenic area in the region of the left testis and an incomplete rim of hyperemia in the surrounding skin and dartos, compatible with mid phase testicular torsion.

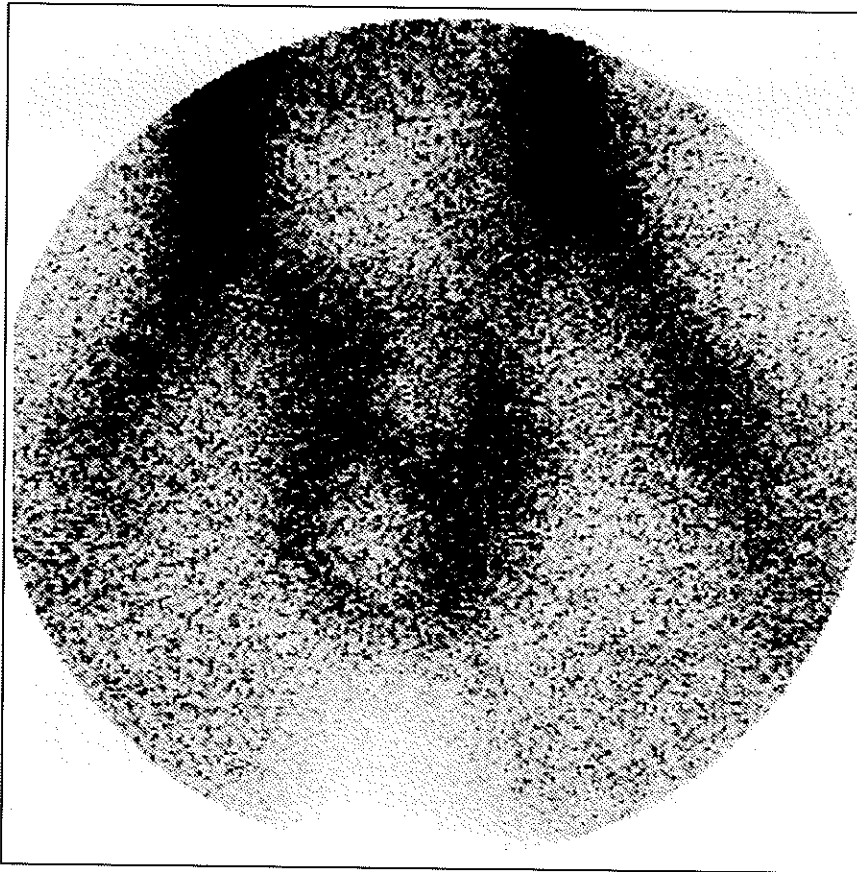


Figure 4. Anterior image from a 15-year-old man demonstrates a well defined rim of increased activity in the skin and dartos surrounding an avascular right testis compatible with late phase of testicular torsion.

groups with equivocal physical findings or in patients with unusual presentations (18).

Other modalities used to evaluate testicular perfusion include doppler ultrasound, color flow ultrasonography (CFUS) and magnetic resonance imaging (MRI). Older studies comparing doppler ultrasound and testicular scintigraphy demonstrated that the latter had a higher diagnostic accuracy for evaluating testicular perfusion (19,20). In animal studies with surgically created torsions of 90 to 720 degrees CFUS was superior to scintigraphy in detecting abnormal testicular perfusion (21). A more recent prospective clinical study, performed by experienced sonographers, demonstrated that CFUS was as accurate as scintigraphy in detecting testicular torsion (22). However, others have also suggested that CFUS should be used in conjunction with scintigraphy when evaluating testicular perfusion in prepubertal boys (23). The results obtained

with CFUS will depend largely on operator experience. An additional limitation of CFUS is the inability to obtain good acoustic coupling in patients with marked scrotal tenderness. Magnetic resonance imaging was able to accurately differentiate subacute torsion from epididymitis in a small series of patients (24). However, at the present time MRI evaluation of torsion is considered experimental and its routine clinical use is not recommended. Despite the emergence of newer modalities, testicular scintigraphy has maintained an important role in the management of patients with acute onset of hemiscrotal pain.

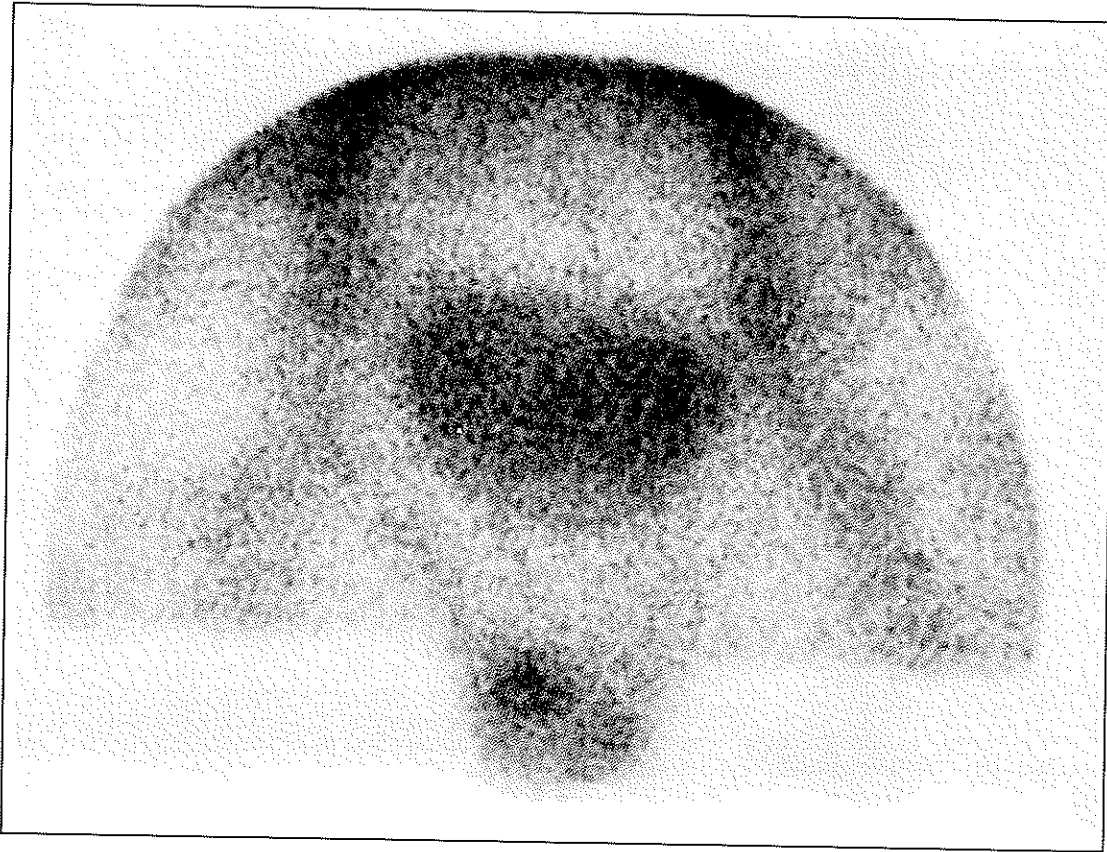


Figure 5. Anterior image from an 8-year-old boy demonstrates a focal area of increased activity superior to the right testis corresponding to a surgically confirmed torsion of the appendix testis.

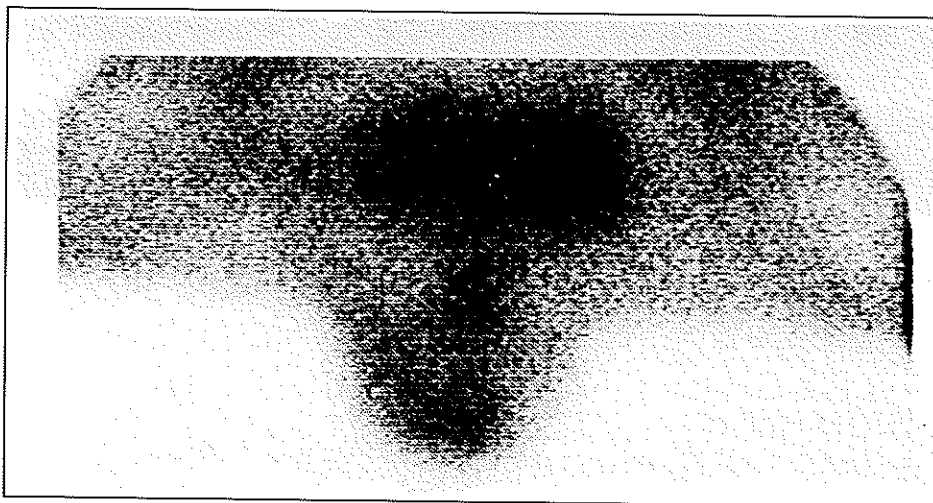


Figure 6. Anterior images from a 3-year-old boy with a 3 day history of gradually increasing right scrotal pain associated with elevated temperature and white blood cell count demonstrates increased activity in the region of the right epididymis and testis compatible with epididymo-orchitis.

*Address Correspondence to:* Daniel F Worsley, MD, Division of Nuclear Medicine, Hospital of the University of Philadelphia, 3400 Spruce Street, Philadelphia, PA 19104, USA.

## REFERENCES

1. Lutzker LG, Zuckier LS. Testicular imaging and other applications of radionuclide imaging of the genital tract. *Semin Nucl Med* 20(2): 159-188; 1990.
2. Lowry PA, Brown WD. Spontaneously reduced testicular torsion a pitfall in radionuclide scrotal imaging. *Urology* 33(2): 135-136; 1989.
3. Prater JM, Overdorf BS. Testicular torsion: a surgical emergency. *Am Fam Physician* 44: 834-840; 1991.
4. Brandt MT, Sheldon CA, Wacksman J, Matthews P. Prenatal testicular torsion: principles of management. *J Urol* 147: 670-672; 1992.
5. Chen DC, Holder LE, Melloul M. Radionuclide scrotal imaging further experience with 210 patients part 1: anatomy, pathophysiology and methods. *J Nucl Med* 24: 735-742; 1983.
6. Holder LE, Melloul M, Chen D. Current status of radionuclide scrotal imaging. *Semin Nucl Med* 11: 232-249; 1981.
7. Parker RM, Robinson JR. Anatomy and diagnosis of torsion of the testicle. *J Urol* 106: 243-247; 1971.
8. Holder LE, Martire JR, Holmes ER, et al. Testicular radionuclide angiography and scrotal imaging anatomy, scintigraphic interpretation and clinical indications. *Radiology* 125: 739-752; 1977.
9. Stanley J K. Acute and chronic scrotal swellings. In: JY Gillenwater, JT Grayhack, SS Howards, et al. eds. *Adult and pediatric urology*, 2nd ed.. St Louis: Mosby Year Book; 1991: 878.
10. Hayes BE. Doppler ultrasound failure in testicular torsion. *Ann Emerg Med* 13(12): 1103-1107; 1984.
11. Riely TW, Mosbaugh PG, Coles JL, Newman DM, VanHove ED. Use of radioisotope scan in the evaluation of intrascrotal lesions. *J Urol* 116(4): 472-475; 1976.
12. Lutzker LG, Novick I, Perez LA, et al. Radionuclide scrotal imaging. *Appl Radiol Nucl Med* 6: 187-195; 1977.
13. Chen DC, Holder LE, Melloul M. Radionuclide scrotal imaging further experience with 210 new patients Part 2: results and discussion. *J Nucl Med* 24: 841-853; 1983.
14. Gislason T, Noronha RFX, Gregory JG. Acute epididymitis in boys: A 5-year retrospective study. *J Urol* 124: 533-534; 1979.
15. Williams CB, Litvak AS, McRoberts JW. Epididymitis in infancy. *J Urol* 121: 125-126; 1978.
16. Rosenson AS, Ali A, Fordham EW, Chaviano A. A false-positive scan for testicular torsion and false-negative scan for epididymitis. *Clin Nucl Med* 15: 863-864; 1990.
17. Haynes BE, Bessen HA, Haynes VE. The diagnosis of testicular torsion. *JAMA* 249: 2522-2527; 1983.
18. Fenner MN, Roszhart DA, Texter JHJ. Testicular scanning: evaluating the acute scrotum in the clinical setting. *Urology* 38: 237-241; 1991.
19. Rodriguez DD, Rodriguez WC, Rivera JJ, Rodriguez S, Otero AA. Doppler ultrasound versus testicular scanning in the evaluation of the acute scrotum. *J Urol* 125: 343-346; 1981.
20. Chen DC, Holder LE, Kaplan GN. Correlation of radionuclide imaging and diagnostic ultrasound in scrotal diseases. *J Nucl Med* 27: 1774-1781; 1986.
21. Mevorach TA, Lerner RM, Greenspan BS, et al. Color Doppler ultrasound compared to a radionuclide scanning of spermatic cord torsion in a canine model. *J Urol* 145: 428-433; 1991.
22. Middleton WD, Siegel BA, Melson GL, Yates CK, Andriole GL. Acute scrotal disorders: Prospective comparison of color Doppler US and testicular scintigraphy. *Radiology* 177: 177-181; 1990.
23. Atkinson GO, Patrick LE, Ball TI, Stephenson CA, Broecker BH, Woodard JR. The normal and abnormal scrotum in children: evaluation with color doppler sonography. *AJR* 158: 613-617; 1992.
24. Trambert MA, Mattrey RF, Levine D, Berthoty DP. Subacute scrotal pain: evaluation of torsion versus epididymitis with MR imaging. *Radiology* 175: 53-56; 1990.