

Parotid metastasis as the first presentation of papillary thyroid carcinoma

Fatemeh Farahmandfar¹, Sara Shakeri¹, Emran Askari¹, Amir Hosein Jafarian²,
Shirin Taraz Jamshidi³, Susan Shafiei¹, Seyed Rasoul Zakavi¹

¹Nuclear Medicine Research Center, Mashhad University of Medical Sciences, Mashhad, Iran

²Department of Pathology, Faculty of Medicine, Mashhad University of Medical Sciences, Mashhad, Iran

³Cancer Research Center, Mashhad University of Medical Sciences, Mashhad, Iran

(Received 14 November 2019, Revised 16 May 2020, Accepted 31 May 2020)

ABSTRACT

Parotid metastasis originated from papillary thyroid carcinoma is extremely rare, especially as the first presentation of the disease. We present a 70-year-old man with a history of painless swelling in the right side of the neck. He was evaluated for parotid tumor and histopathologic examination revealed a poorly differentiated carcinoma in the parotid gland with suspicion of thyroid origin. The thyroid was examined and a small nodule was palpable in the right lobe of the thyroid that was found to be dedifferentiated papillary thyroid carcinoma upon total thyroidectomy. He received 5.5GBq of ¹³¹I and post-ablation whole body iodine scan showed thyroid remnant, cervical lymph node metastasis, lung and pericardial metastases and pleural effusion. He succumbed to his disease 8 months after diagnosis despite further treatments efforts including chemoradiation.

Key words: Dedifferentiated papillary thyroid carcinoma; Metastasis; Parotid involvement

[Iran J Nucl Med 2020;28\(2\):42-45](#)

Published: July, 2020

<http://irjnm.tums.ac.ir>

Corresponding author: Dr. Seyed Rasoul Zakavi, Nuclear Medicine Research Center, Mashhad University of Medical Sciences, Mashhad, Iran. E-mail: zakavir@mums.ac.ir

INTRODUCTION

Parotid gland tumors constitute 80% of salivary gland neoplasms [1]. Most of the parotid tumors are benign and only about 10% of them are malignant of which 20% are metastases from the other organs [2]. Majority of metastatic parotid tumors arise from the cutaneous tumors of the scalp, face, external ear, eyelids, or nose; and less commonly they come from lung, breast, kidney, colon or prostate cancer. Metastasis of papillary thyroid carcinoma (PTC) to the parotid gland is extremely rare [3]. PTC most commonly metastasize to lung and bone and rarely to breast, adrenal, pituitary, kidney, orbit, and brain [3]. Moreover, PTC is often asymptomatic and the first clinical presentation is usually a thyroid nodule [4]. We report a rare case of metastatic papillary thyroid carcinoma with the initial presentation of a parotid mass.

CASE PRESENTATION

We present a 70-year-old man with a recent history of progressive painless swelling on the right side of the neck. On physical examination, a palpable 4 × 4 cm firm mass was noted without tenderness and erythema over the right parotid gland. Cervical ultrasonography (US) showed a hypochoic mass with foci of calcification in the right parotid gland as well as multiple lymphadenopathies in the right side of the neck. CT examination revealed a large calcified lesion in the right side of the neck adjacent to the upper edge of the right submandibular gland with multiple bilateral non-homogenous cervical lymphadenopathies (Figure 1). Since the patient had the previous history of tuberculosis, initial workup was performed to rule out recurrence of tuberculosis which was negative. Fine needle aspiration biopsy from the parotid gland revealed invasive carcinoma. The patient underwent right superficial parotidectomy and lymph node dissection (LND). The histopathological finding was compatible with papillary thyroid carcinoma with poorly differentiated characteristics involving the right parotid gland and associated cervical lymphnodes (Figure 2). IHC examination showed positive TTF1 and positive Tg staining in the parotid gland. Physical examination revealed a palpable nodule in the right thyroid lobe and thyroid scintigraphy showed a hypo-functioning nodule in the right lobe. He underwent total thyroidectomy and cervical lymph node dissection. The histopathologic examination confirmed dedifferentiated papillary thyroid carcinoma with lymph node involvement (Figure 3). Considering high risk of recurrence, he was admitted and received 5.5GBq (150 mCi) of ¹³¹I. Post ablation whole body iodine scan (WBIS) showed postsurgical thyroid remnant, right cervical lymph node metastasis and a metastatic pulmonary nodule in the right middle lobe as well as a pericardial metastasis.

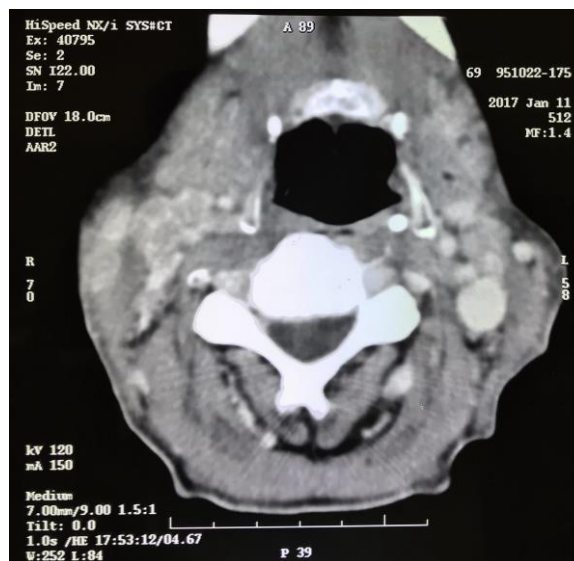

Fig 1. CT scan of the head and neck showed a large calcified lesion in the right parotid gland.

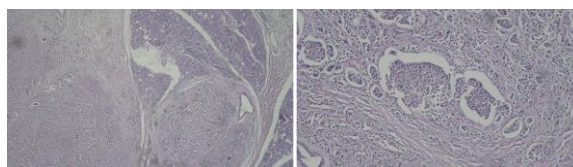


Fig 2. Histopathology of the parotid gland showed large pleomorphic and hyperchromatic cells in the desmoplastic stroma, which were compatible with poorly differentiated carcinoma.

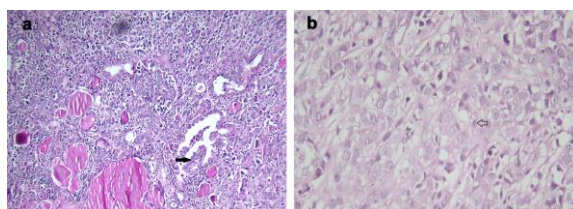


Fig 3. Histopathology findings from thyroid shows residual papillary (black arrow) and follicular structures of papillary thyroid carcinoma surrounded by dedifferentiated component (a). High power view of dedifferentiated carcinoma composed of solid sheets of highly atypical epithelioid cells (b). An atypical mitotic figure is seen in the center of the picture (open arrow) (Hematoxylin and Eosin staining×100).

Also pleural effusion was noted in the right lung without Iodine uptake (Figure 4). Because of disease progression, the oncologist preferred external radiotherapy of the neck followed by systemic chemotherapy. Despite all treatments, rapid deterioration occurred and the patient died 8 months after the first presentation of the disease.

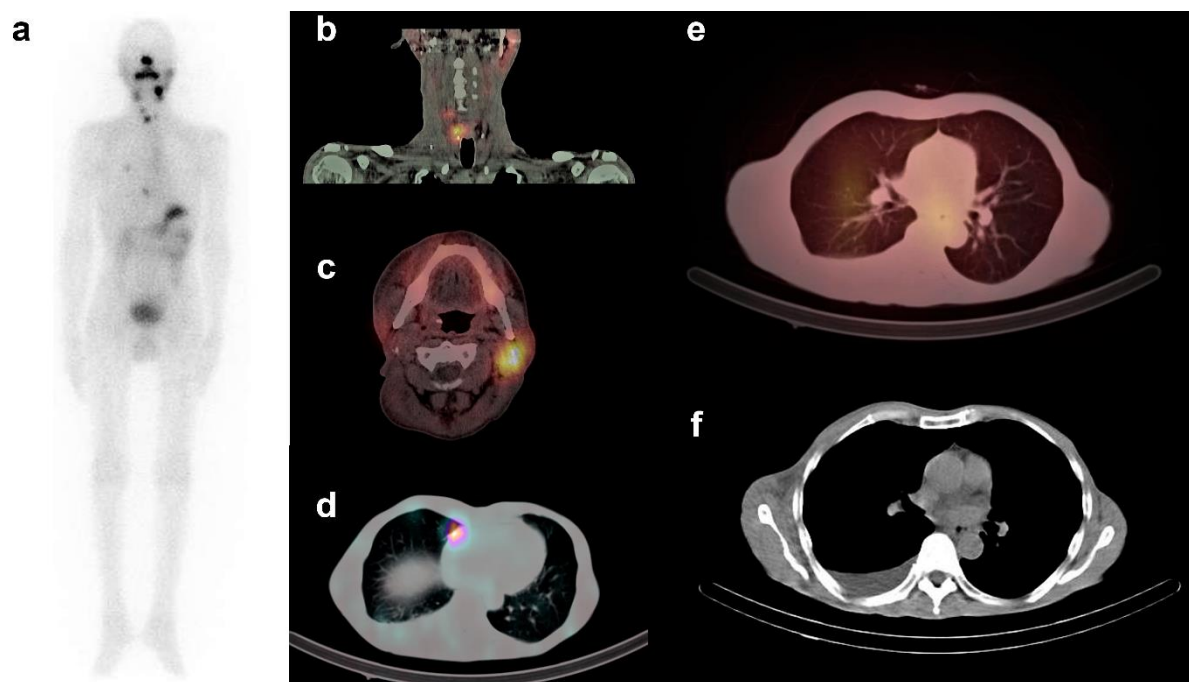


Fig 4. a. Whole body ^{131}I scan showed post-surgical thyroid remnant (PSTR) in the right thyroid lobe with right cervical, lung and pericardial metastasis. b. SPECT/CT confirmed PSTR and cervical lymphnode metastasis. c. Asymmetric iodine uptake in the left parotid gland is due to the previous right parotidectomy. d. Pericardial metastasis. e. Metastatic pulmonary nodule. f. Right sided pleural effusion.

DISCUSSION

Papillary thyroid carcinoma is the most common subtype of well differentiated thyroid cancer [5]. Occasionally transformation to dedifferentiated form of the disease happens over the time. Clinical characteristics of dedifferentiated papillary thyroid cancer include rapid growth, distant metastasis, tendency to recurrence and poor response to radioactive iodine therapy [6]. Although 10-year disease-specific survival of classic PTC is 85–92%, presence of distant metastasis reduce it to 10–40% [7]. Furthermore, poorly differentiated thyroid carcinoma has a 5-year overall survival of 65–85% [8].

Local and distant metastases of classic papillary thyroid carcinoma mainly occur in the regional lymph nodes, lung and bones with decreasing frequency in the mentioned order [3]. Parotid involvement in all pathologic subtypes of PTC is very rare [3, 9-14], especially as the first presentation of the disease and rarely reported in the literature [9, 15-17].

Although the planar WBIS imaging is the standard test for assessment of thyroid remnant and metastasis, SPECT/CT with ^{131}I which is the combination of functional and anatomical imaging provides valuable data about metabolic and morphological features of the disease. It could clarify equivocal findings on planar images and improve the test accuracy [18].

Wu et al. found 3 cases (0.019%) of parotid metastasis in a review of 15,780 cases of thyroid carcinoma in

their own department and performed a systematic search of literature and found that only 10 additional cases had been reported up to 2015. Interestingly only 8 of all 13 cases had papillary or follicular thyroid carcinoma with the remaining cases in patients with medullary thyroid carcinoma [2].

Among those with PTC and FTC, the age of the patients was between 30-78 years, including six women and two men. Four of these patients, had previous history of thyroid carcinoma and developed parotid metastasis 2-30 years later. Three patients had no history of thyroid disease and the first presentation was parotid swelling. In one patient, previous history was not reported. Four patients had right parotid involvement and four had left parotid mass. Most of them underwent surgery with or without radio-iodine therapy and one received chemo-radiation. Follow up data was reported in 4 patients; two had been stable disease without recurrence 1.5 and 2 years later; and two patients had developed lung and bone 5 months and 8 years later [2]. These findings indicate aggressive behavior of tumors with parotid metastasis.

The unique feature of our case report is that parotid mass was the first presentation of papillary thyroid carcinoma that is extremely rare and associated with lung and pericardial metastasis. After parotidectomy and total thyroidectomy, he underwent radio-iodine therapy followed by chemoradiation due to dedifferentiate and aggressive characteristics of the

tumor. Unfortunately, he succumbed to his disease 8 months after treatment.

CONCLUSION

Our case report suggests that parotid metastasis can be the first presentation of papillary thyroid carcinoma and considering the increasing incidence of thyroid carcinoma, thyroid examination should be kept in mind in the workup of patients with parotid mass. Metastasis to parotid gland from thyroid origin, seems to be an indication of aggressive disease with high frequency of lung and bone metastases and poor survival.

REFERENCES

- Venkatesh S, Srinivas T, Hariprasad S. Parotid gland tumors: 2-year prospective clinicopathological study. *Ann Maxillofac Surg*. 2019 Jan-Jun;9(1):103-109.
- Wu ZH, Ge MH, Cao J, Lan XB, Zhu XH, Huang YQ, Yu B. Parotid metastases from thyroid carcinomas. *Int J Clin Exp Pathol*. 2017 Oct 1;10(10):10467-10474.
- Kilic K, Sakat MS, Gozeler MS, Demirci E. Parotid gland involvement as an initial presentation of papillary thyroid carcinoma. *Int J Oral Maxillofac Surg*. 2017;46(8):965-7.
- Das R, Kumar M, Sharma J, Krishnatreya M, Chakraborty P, Katakai A. Papillary thyroid carcinoma presenting with mandibular metastasis: An unusual presentation. *Clin Cancer Invest J*. 2014;3(5):426-8.
- Shi X, Liu R, Basolo F, Giannini R, Shen X, Teng D, Guan H, Shan Z, Teng W1, Musholt TJ, Al-Kuraya K, Fugazzola L, Colombo C, Kebebew E, Jarzab B, Czarniecka A, Bendlova B, Sykorova V, Sobrinho-Simões M, Soares P, Shong YK, Kim TY, Cheng S, Asa SL, Viola D, Elisei R, Yip L, Mian C, Vianello F, Wang Y, Zhao S, Oler G, Cerutti JM, Puxeddu E, Qu S, Wei Q, Xu H, O'Neill CJ, Sywak MS, Clifton-Bligh R, Lam AK, Riesco-Eizaguirre G, Santisteban P, Yu H, Tallini G, Holt EH, Vasko V, Xing M. Differential clinicopathological risk and prognosis of major papillary thyroid cancer variants. *J Clin Endocrinol Metab*. 2016 Jan;101(1):264-74.
- Chen H, Luo D, Zhang L, Lin X, Luo Q, Yi H, Wang J, Yan X, Li B, Chen Y, Liu X, Zhang H, Liu S1, Qiu M, Yang D, Jiang N. Restoration of p53 using the novel MDM2-p53 antagonist APG115 suppresses dedifferentiated papillary thyroid cancer cells. *Oncotarget*. 2017 Jun 27;8(26):43008-43022.
- Papp S, Asa SL. When thyroid carcinoma goes bad: a morphological and molecular analysis. *Head Neck Pathol*. 2015;9(1):16-23.
- Ibrahimasic T, Ghossein R, Carlson DL, Nixon I, Palmer FL, Shaha AR, Patel SG, Tuttle RM, Shah JP, Ganly I. Outcomes in patients with poorly differentiated thyroid carcinoma. *J Clin Endocrinol Metab*. 2014 Apr;99(4):1245-52.
- Mathew PC, Balagopal PG, Thomas S, Sebastian P, Preethi TR. Parotid metastasis from carcinoma of the thyroid. *Int J Oral Maxillofac Surg*. 2007;36(10):965-6.
- Kini H, Pai RR, Kalpana S. Solitary parotid metastasis from columnar cell carcinoma of the thyroid: a diagnostic dilemma. *Diagn Cytopathol*. 2003;28(2):72-5.
- Gnepp D, Wenig B, Ellis G, Auclair P. Surgical pathology of the salivary glands. *Major Probl Pathol*. 1991;25:350-68.
- Thackray A. Tumors of the major salivary glands. *Atlas of tumor pathology*. Armed Forces Inst Pathol. 1974;10:14.
- Markitziu A, Fisher D, Marmary Y. Thyroid papillary carcinoma presenting as jaw and parotid gland metastases. *Int J Oral Maxillofac Surg*. 1986;15(5):648-53.
- Saikia B, Dey P, Saikia UN, Das A. Fine needle aspiration cytology of metastatic scalp nodules. *Acta cytologica*. 2001;45(4):537-41.
- Malhotra G, Nair N, Awasare S, Baghel NS. Metastatic parotid tumor: a rare presentation for papillary carcinoma of thyroid. *Clin Nucl Med*. 2007;32(6):488-90.
- Alzaraa A, Stone J, Williams G, Ahmed I, Quraishi M. Direct spread of thyroid follicular carcinoma to the parotid gland and the internal jugular vein: a case report. *J Med Case Rep*. 2008;2:297.
- Conway A, Wiernik A, Rawal A, Lam C, Mesa H. Occult primary medullary thyroid carcinoma presenting with pituitary and parotid metastases: case report and review of the literature. *Endocr Pathol*. 2012 Jun;23(2):115-22.
- Zilioli V, Peli A, Panarotto MB, Magri G, Alkraisheh A, Wiefels C, Rodella C, Giubbini R. Differentiated thyroid carcinoma: Incremental diagnostic value of I SPECT/CT over planar whole body scan after radioiodine therapy. *Endocrine*. 2017 Jun;56(3):551-559.