



ORIGINAL RESEARCH ARTICLE

The [⁶⁸Ga]Ga-DOTATATE and [¹⁸F]FDG PET-CT imaging characteristics of metastatic neuroendocrine tumors

Zehra Pinar Koç¹, Pinar Pelin Özcan¹, Vehbi Erçolak², Tuba Kara³

¹Nuclear Medicine Department, Faculty of Medicine, Mersin University, Mersin, Turkey

²Oncology Department, Faculty of Medicine, Mersin University, Mersin, Turkey

³Pathology Department, Faculty of Medicine, Mersin University, Mersin, Turkey

ARTICLE INFO

Article History:

Received: 06 September 2023

Revised: 20 December 2023

Accepted: 23 December 2023

Published Online: 16 March 2024

Keyword:

[⁶⁸Ga]Ga-DOTATATE
Neuroendocrine tumors
[¹⁸F]FDG

*Corresponding Author:

Dr. Zehra Pinar Koç,
Address: Nuclear Medicine Department,
Faculty of Medicine, Mersin University,
Mersin, Turkey
Email: zehrapinarkoc@gmail.com

ABSTRACT

Introduction: The [⁶⁸Ga]Ga-DOTA-conjugated somatostatin receptor imaging (SR) is becoming the standard imaging procedure in the management of the neuroendocrine tumors (NET). Meanwhile [¹⁸F]FDG PET-CT as an adjunctive tool provides useful information in the imaging of NETs. The aim of this study was to compare the diagnostic utility of these imaging methods as well as demonstrate uptake characteristics of NETs.

Methods: 41 patients (17 M, 21 F; mean: 57.1 years old) with the diagnosis of metastatic neuroendocrine tumors were included in the study. [¹⁸F]FDG PET-CT and/or [⁶⁸Ga]Ga-DOTATATE PET-CT imaging was performed in patients for initial staging, restaging, treatment response evaluation, lesion characterization or to find an unknown primary tumor. The results of the patients were compared with oncologic follow up results and/or pathology results.

Results: The size of the lesions were mean: 34 mm and the standardized uptake value in [¹⁸F]FDG PET/CT SUVmax(F) and SUV in [⁶⁸Ga]Ga-DOTATATE PET/CT SUVmax(G) of the lesions were mean: 10.6 and 32.4 respectively. According to the follow up results of the 23 patients with available initial and follow up imaging studies, the management of seven patients were changed (30%). Among the NET group grade 1-3 tumors SUVmax(F) and SUVmax(G) levels were not significantly different.

Conclusion: Diagnostic workup of metastatic NET's should include either or both of the [⁶⁸Ga] DOTATATE and [¹⁸F]FDG PET-CT imaging studies. Individualization of the imaging method of choice in every single patient would be an appropriate approach.

Use your device to scan and read the article online



How to cite this article: Koç ZP, Özcan PP, Erçolak V, Kara T. The [⁶⁸Ga]Ga-DOTATATE and [¹⁸F]FDG PET-CT imaging characteristics of metastatic neuroendocrine tumors. Iran J Nucl Med. 2024;32(2):118-123.



<https://doi.org/10.22034/IRJNM.2023.129379.1574>

INTRODUCTION

Neuroendocrine tumors may arise from different organs-systems in the body and has different pathologic expressions. The heterogeneity in the tumor is reflected by the different imaging characteristics by means of nuclear imaging modalities. The pathologic grades of the tumor (G1-3) do not necessarily reflect the functional status of the tumors. Additionally, the pathologic features of the primary tumor and metastatic focuses of the same NET might be different. The [⁶⁸Ga]Ga-DOTATATE and [¹⁸F]FDG PET/CT imaging characteristics of the NETs have been investigated previously by several studies [1-4]. These observations show that lower grade tumors accumulate higher [⁶⁸Ga]Ga-DOTATATE and lower [¹⁸F]FDG. Although [⁶⁸Ga]Ga-DOTATATE and its analogues are relatively newly introduced agents there is previous data about the - octreotide scan with different radiopharmaceutical forms. Peptide receptor imaging has been vastly studied by PET/CT in recent years because of the significant superiorities of the [⁶⁸Ga]Ga-DOTATATE imaging including better imaging characteristics and receptor affinity of the lesions. Despite the introduction of peptide receptor imaging by PET/CT [¹⁸F]FDG PET/CT preserves its significance as an imaging modality in NET's. Comparative studies suggest combination of these two modalities probably because of the conflicting results due to the different grade tumors and the metastatic lesions [2, 4]. This issue needs to be evaluated with specific series because imaging characteristic as well as prognostic and therapeutic approaches are completely different between metastatic and non-metastatic NETs. This study group consists of a relatively homogenous group with diagnosis of metastatic NET's and pathological findings. Additionally, we could also evaluate and discriminate special grade groups and analyze the results accordingly in the patients with both imaging study findings. The aim of this study was to analyze the [⁶⁸Ga]Ga-DOTATATE and [¹⁸F]FDG PET/CT imaging features of metastatic NETs, compare the results with pathological characteristics of the lesions and finally evaluate the potential effect of these findings on patient management.

METHODS

Patients

The patient group includes 41 patients (17 M, 21 F; mean: 57.1 years old) with diagnosis of metastatic NET's. The informed consents of the

patients were obtained for the imaging studies. All of the patients underwent diagnostic [⁶⁸Ga]Ga-DOTATATE imaging and [¹⁸F]FDG PET-CT was performed in the patients with suspicion of another primary tumor and/or insufficient [⁶⁸Ga]Ga-DOTATATE uptake. The study was conducted according to the Helsinki Declaration and the study was approved by the local ethic committee (Registration Number: 2019/152, Date: 3/4/2019).

PET-CT imaging

The radiolabeling was performed as previously described by Decristoforo et al. [5]. ⁶⁸Ge-⁶⁸Ga generator (Eckert & Zeigler Eurotope, Berlin, Germany) was used to prepare [⁶⁸Ga]Ga-DOTATATE. The patients were injected [⁶⁸Ga]Ga-DOTATATE at the dose of mean: 4.2 mCi and after a waiting period of mean: 52.9 hours the imaging was performed as a whole-body imaging procedure by the PET-CT imaging device (Siemens MCT).

The [¹⁸F]FDG PET-CT was performed after at least 4 hours fasting period and restriction of physical exercise for 24 hours before the study. The imaging was performed after injection of [¹⁸F]FDG via venous line after a waiting period for at least 1 hour by the same imaging device and same field of view.

The images were analyzed by two experienced Nuclear Medicine physicians retrospectively and the size and SUVmax level of the dominant lesion as well as SUVmax level of an additional metastatic lesion were recorded. The quantification of the lesions was performed from the most active part of the most metabolic active lesion.

The SUVmax levels of the dominant lesions (primary or metastatic the largest lesion in diameter) of the patients were compared using Paired Samples T test in both studies. In the patients with significant amount of activity accumulation in [⁶⁸Ga]Ga-DOTATATE in primary and/or metastatic sites were staged and followed by this modality (Figure 1). However, in patients with the suspicion of insufficient accumulation or a second primary tumor additional [¹⁸F]FDG PET-CT was performed.

The pathology results were retrospectively evaluated by an experienced pathology physician without the knowledge of initial and final outcome of the patients.

The numeric variables are compared with paired samples Students T test. P<0.05 considered significant.

RESULTS

The primary diagnosis, pathology results and SUVmax levels of the patients in imaging studies are summarized in Table 1. The oncologic follow up of the patients was obtained in 23 of the patients (one died after imaging and others were lost to follow up). Among these patients the patients' management changed in 7 (30%) as a

result of upstaging or downstaging leading to another chemotherapy-therapy protocol or different surgical plan (Figure 1).

The difference of the SUVmax levels of the tumors in [^{18}F]FDG and [^{68}Ga]Ga-DOTATATE imaging studies in different grade tumors was not significant (G1 mean: 9.5 vs 7.6; G2 mean: 10.7 vs 8.6 and G3 mean: 9.8 vs 17.3, respectively) ($p > 0.05$).

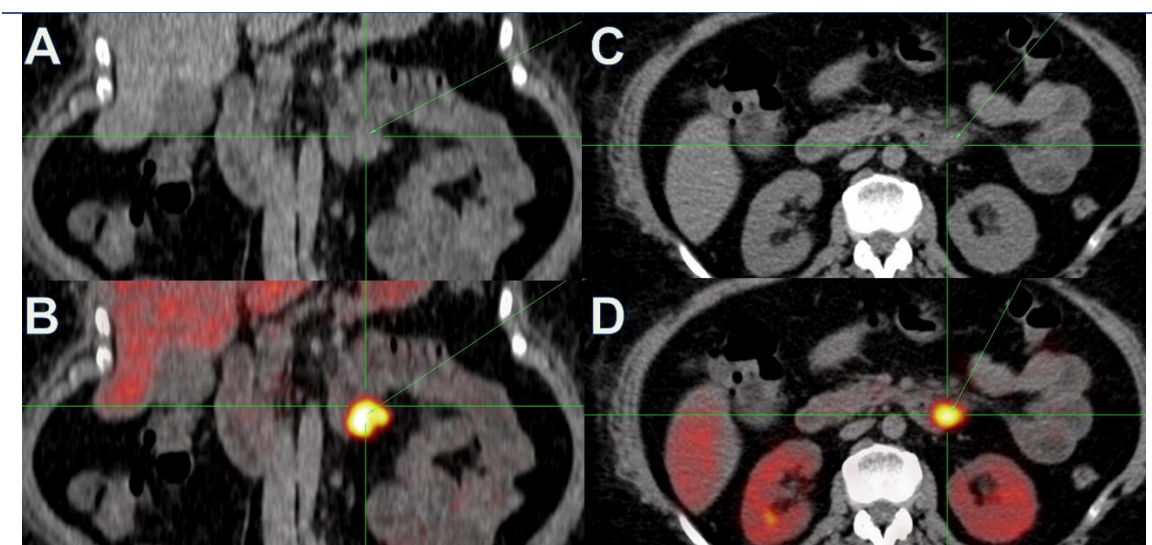


Figure 1. 54 years old female patient presented with primary unknown neuroendocrine tumor. The [^{68}Ga] DOTATATE PET/CT imaging revealed significant accumulation in the duodenum suggesting primary tumor with diagnosis of grade 1 neuroendocrine tumor (Ki-67:1%) on horizontal (A, B) and transaxial plane CT and fusion PET/CT images (C, D), respectively

DISCUSSION

According to the results of this study, it is an appropriate method to individualize the imaging algorithm in patients with NET's. The patients with metastatic NET's are a heterogeneous group including different kinds of primary tumors. It is not always possible to predict which diagnostic imaging ([^{68}Ga] labelled radionuclides or [^{18}F]FDG) would evaluate the patient precisely according to the previous studies [1-3]. Unfortunately, the NET's grade of the tumor might not help to select the imaging modality. The tumor biology in primary and metastatic lesions might be different and secondary tumors might be observed in some cases. Thus additional [^{18}F]FDG PET-CT in this series was required in several cases with suspicious findings in the initial [^{68}Ga]Ga-DOTATATE imaging. It might be the best approach to evaluate the tumor biology with both of the modalities at the time of first diagnosis and decide which procedure should be considered at the follow up. Since [^{68}Ga]Ga-DOTATATE imaging is a recent modality there are limited number of comparative studies. In order to provide a sufficient comparison, it might be better

compared according to the origin of the tumor (e.g. gastroenteropancreatic, lung etc.)

Previous studies about paraganglioma and pheochromocytoma revealed similar lesion detection rates and superior image quality by means of [^{68}Ga]Ga-DOTATATE compared to [^{18}F]FDG PET/CT thus was suggested as an additional imaging modality [1]. Another comparative study evaluated volumetric parameters as well as SUVmax levels in these two modalities in comparison with blood Chromogranin A (Cg-A) levels; which concluded that some of the metastatic lesion that has [^{18}F]FDG accumulation might not accumulate [^{68}Ga]Ga-DOTATATE [2]. Similarly, another study in patients with metastatic melanoma has shown that only 22% of the [^{18}F]FDG avid metastatic lesions could be demonstrated by means of [^{68}Ga]Ga-DOTATATE imaging [6]. Previous investigations demonstrated that up to 40% of the patients with carcinoid metastases of the liver might also have non-carcinoid tumor [7, 8]. However other comparative studies reveal higher diagnostic sensitivity in all grades of the NE tumors by [^{68}Ga]Ga-DOTATATE compared to [^{18}F]FDG PET/CT [9].

Table 1. Characteristics of the patients (pathology, imaging results and primary diagnosis)

Patients	Primary	Metastasis	SUV1	SUV2	Pathology	Ki-67	Mitosis
1	Mediastinum	Lung	15.9	12.1	Grade 3	80	>20
2	Larynx	Mediastinum	32.9	6.7	Grade 3	30	40
3	Stomach	Bone	2	20	Grade 2	10	0
4	Lung	Liver, Bone	13	8.9	Grade 1	10	1
5	Rectum	Liver, Bone	22.4	9.34	Grade 2	6	1
6	Lung	Lymph, Pleura	7	11.3	Carcinoid	<2	<2
7	Intestine	Lymph	-	6.6	Grade 2	6	1
8	Unknown	Liver, Bone	30.6	9.6	Grade 3	>55	/
9	Lung	Lymph	13	11.3	SCLC	90	/
10	Lung	Lymph, Bone	7.6	12.9	Carcinoid	<1	/
11	Lung	Lymph, Lung	5.6	4.4	SCLC	80	/
12	Intestine	Lymph	3.2	10.5	Grade 1	1	0
13	Liver	Liver	-	84.3	Grade 1	1	0
14	Pancreas	Liver, Adrenal	-	73	Grade 2	3-4	1-2
15	Stomach	Lung	14.7	15.8	Grade 3	70	/
16	Lung	Lymph, Lung	7.2	5.9	Carcinoid	<2	/
17	Intestine	Lymph		445	Grade 1	1	1
18	Lung	Lymph, Lung	7.4	17.5	Carcinoid	30	7
19	Lung	Lymph, Lung	4.4	5.6	SCLC	80	/
20	Intestine	Bone, Lung	8.6	10.7	Grade 2	4	2
21	Stomach	Liver, Lung	15.2	7.5	SCLC	80	/
22	Intestine	Lymph	6.6	9.1	Grade 1	2	1
23	Rectum	Lymph, Implant	-	8.8	Grade 1	1	0
24	Kidney	Bone	4.8	3.6	Grade 3	-	
25	Stomach	Bone	-	8.4	Grade 2	7	7
26	Stomach	Lymph	-	20.4	Grade 1	2	0
27	Lung	Lymph	7	9.7	Carcinoid	2	/
28	Intestine	Implant	-	25.8	Grade 1	-	-

SUV1: [¹⁸F]FDG SUVmax, SUV2: [⁶⁸Ga]Ga-DOTATATE SUVmax, SCLC: Small cell lung carcinoma, MTC: Medullary thyroid carcinoma

The distribution or accumulation of the [⁶⁸Ga]Ga-DOTATATE and [¹⁸F]FDG according to the grade of the NET's is another issue. The results of this study clearly indicated no significant difference between SUVmax levels of the NET's according to the different grades. Which is not in line with previous literature data.

[⁶⁸Ga]Ga-DOTATATE imaging modality take its place in the recent guidelines in the determination of the primary neuroendocrine tumors and their metastasis [10]. [¹⁸F]FDG PET/CT is recommended in poorly differentiated tumors without or with low [⁶⁸Ga]Ga-DOTATATE accumulation. The glucose metabolism increases, and somatostatin receptor expression

decreases with increasing grade [11, 12]. In another study about bronchial carcinoid tumors has shown that atypical carcinoids and higher grade tumors show less [⁶⁸Ga]Ga-DOTATATE uptake compared to the [¹⁸F]FDG uptake [3]. The same researchers also observed this finding in conjunction with Ki-67 index in Gastroenteropancreatic (GEP) NETs in another study [13]. The most important contribution of the [⁶⁸Ga]Ga-DOTATATE imaging is the impact on the patient's management according to the results of this study as well as previous studies. Previous studies highlighted the high ratio of the change in the patients' management in combination of both modalities which showed significantly higher sensitivity of [⁶⁸Ga]Ga-

DOTATATE over [¹⁸F]FDG (95% versus 37%) [4, 8–14].

Koukouraki et al. has also reported the higher percentage of patient's management change in their study group which was significantly affected by [⁶⁸Ga]Ga-DOTATATE imaging [15]. In a study including patients with unknown primary NETs, the detection rate of combination of both modalities was 60.78% and the sensitivity was 96.87% [16]. A recent study which includes the comparison of [⁶⁸Ga]Ga-DOTATATE and [¹⁸F]FDG PET/CT imaging in patients with low grade and high grade tumors reached the similar conclusion; there was not significant difference between the identification rate of these studies in different grade tumors as in our study [17]. These findings might contribute significantly important information about high grade NET's because as it is documented in that report and our study it would be possible to decide about the suitability of treatment in high grade tumors as well as low grade tumors by [¹⁷⁷Lu]Lu-DOTATATE. The study by You et al. was performed in different grade tumors but not necessarily metastatic unlike this study but consists of both imaging modalities and pathology findings [18]. Despite the knowledge of the NETs showing decreased somatostatin receptor expression in poorly differentiated tumors [19] recent findings of these studies about NETs might contribute new treatment options with radionuclide therapy as it is highly effective treatment according to recent important studies 'NETTER trial' [20]. Another important contribution is to select the patients with potential response to radionuclide treatments.

There are several common [⁶⁸Ga]Ga-DOTA-conjugated somatostatin receptor (SR) analogues with different receptor affinities for the SSTR 1-5 which are expressed in NETs. Previous comparative studies could not show significant advantage of these analogues over each other however superiority of [⁶⁸Ga]Ga-DOTATATE for bone metastasis and limitations in liver metastasis has been reported [21, 22].

The limitations of this analysis are the retrospective structure of this study and limited number of patients with both procedures. However, the study population consists of a specific group of patients who are metastatic and both imaging modalities were performed with additional pathology results. The tumoral heterogeneity of the study group is another limitation. The analysis of every single group should be considered in further studies.

CONCLUSION

[⁶⁸Ga]Ga-DOTATATE PET/CT in combination with [¹⁸F]FDG PET/CT should be the initial staging approach in the metastatic NET's which might show different uptake patterns. The follow up might be performed by the chosen modality; individualization of the imaging is suggested.

REFERENCES

1. Chang CA, Pattison DA, Tothill RW, Kong G, Akhurst TJ, Hicks RJ, Hofman MS. (68)Ga-DOTATATE and (18)F-FDG PET/CT in Paraganglioma and Pheochromocytoma: utility, patterns and heterogeneity. *Cancer Imaging*. 2016 Aug 17;16(1):22.
2. Abdulrezzak U, Kurt YK, Kula M, Tutus A. Combined imaging with 68Ga-DOTA-TATE and 18F-FDG PET/CT on the basis of volumetric parameters in neuroendocrine tumors. *Nucl Med Commun*. 2016 Aug;37(8): 874-81.
3. Kayani I, Conry BG, Groves AM, Win T, Dickson J, Caplin M, Bomanji JB. A comparison of 68Ga-DOTATATE and 18F-FDG PET/CT in pulmonary neuroendocrine tumors. *J Nucl Med*, 2009 Dec;50(12):1927-32.
4. Şimşek DH, Şanlı Y, Kuyumcu S, Başaran B, Mudun A. 68Ga-DOTATATE PET-CT imaging in carotid body paragangliomas. *Ann Nucl Med*. 2018 May;32(4):297-301.
5. Decristoforo C, Knopp R, von Guggenberg E, Rupprich M, Dreger T, Hess A, Virgolini I, Haubner R. A fully automated synthesis for the preparation of Ga-68 labelled peptides. *Nucl Med Commun*. 2007 Nov;28(11):870-5
6. Brogšitter C, Zöphel K, Wunderlich G, Kämmerer E, Stein A, Kotzerke J. Comparison between F-18 fluorodeoxyglucose and Ga-68 DOTATOC in metastasized melanoma. *Nucl Med Commun*. 2013 Jan;34(1): 47-9.
7. Desai K, Watkins J, Woodward N, Quigley AM, Toumpanakis C, Bomanji J, Caplin M. Use of molecular imaging to differentiate liver metastasis of colorectal cancer metastasis from neuroendocrine tumor origin. *J Clin Gastroenterol*. Jan 2011;45(1): e8-11.
8. Goodwin JD. Carcinoid tumors: an analysis of 2837 cases. *Cancer*. 1975;36: 560-9.
9. Kayani I, Bomanji JB, Groves A, Conway G, Gacinovic S, Win T, Dickson J, Caplin M, Eil PJ. Functional imaging of neuroendocrine tumors with combined PET/CT using 68Ga-DOTATATE (DOTA-DPhe1,Tyr3-octreotate) and 18F-FDG. *Cancer*. 2008 Jun;112(11):2447-55.
10. Subramaniam RM, Bradshaw ML, Lewis K, Pinho D, Shah C, Walker RC. ACR practice parameter for the performance of gallium-68 DOTATATE PET/CT for neuroendocrine tumors. *Clin Nucl Med*. Dec 2018;43(12): 899-908.
11. Oh S, Prasad V, Lee DS, Baum RP. Effect of Peptide Receptor Radionuclide Therapy on Somatostatin Receptor Status and Glucose Metabolism in Neuroendocrine Tumors: Intraindividual Comparison of Ga-68 DOTANOC PET/CT and F-18 FDG PET/CT. *Int J Mol Imaging*. 2011;2011:524130.
12. Adams S, Baum R, Rink T, Schumm-Dräger PM, Usadel KH, Hör G. Limited value of fluorine-18 fluorodeoxyglucose positron emission tomography for

- the imaging of neuroendocrine tumours. *Eur J Nucl Med.* 1998 Jan;25(1):79-83.
13. Kowalski J, Henze M, Schuhmacher J, Maecke HR, Hofmann M, Haberkorn U. Evaluation of positron emission tomography imaging using [⁶⁸Ga]-DOTA-DPhe1-Tyr3- octreotide in comparison to [¹¹¹In]-DTPAOC SPECT: first results in patients with neuroendocrine tumors. *Mol Imaging Biol.* Jan-Feb 2003;5(1):42-8.
 14. Naswa N, Sharma P, Gupta SK, Karunanithi S, Reddy RM, Patnecha M, Lata S, Kumar R, Malhotra A, Bal C. Dual tracer functional imaging of gastroenteropancreatic neuroendocrine tumors using ⁶⁸Ga-DOTA-NOC PET-CT and ¹⁸F-FDG PET-CT: competitive or complimentary? *Clin Nucl Med.* Jan 2014;39(1): e27-e34.
 15. Koukouraki S, Strauss LG, Georgoulas V, Eisenhut M, Haberkorn U, Dimitrakopoulou-Strauss A. Comparison of the pharmacokinetics of ⁶⁸Ga-DOTATOC and [¹⁸F]FDG in patients with metastatic neuroendocrine tumors scheduled for 90Y-DOTATOC therapy. *Eur J Nucl Med Mol Imaging.* 2006 Apr;33(4):1115-22.
 16. Panagiotidis E, Alshammari A, Michopoulou S, Skoura E, Naik K, Maragkoudakis E, Mohmaduvel M, Al-Harbi M, Belda M, Caplin ME, Toumpanakis C, Bomanji J. Comparison of the impact of ⁶⁸Ga-DOTATATE and ¹⁸F-FDG PET/CT on clinical management in patients with neuroendocrine tumors. *J Nucl Med.* Jan 2017;58(1):91-6.
 17. Sampathirao N, Basu S. MIB-1 index-stratified assessment of dual-tracer PET/CT with ⁶⁸Ga-DOTATATE and ¹⁸F-FDG and multimodality anatomic imaging in metastatic neuroendocrine tumors of unknown primary in a PRRT workup setting. *J Nucl Med Technol.* 2017 Mar;45(1):34-41.
 18. You H, Kandathil A, Beg M, De Blanche L, Kazmi S, Subramaniam RM. Ga-68 DOTATATE PET/CT and F-18 FDG PET/CT in the evaluation of low and intermediate versus high-grade neuroendocrine tumors. *Nucl Med Commun.* 2020 Oct;41(10):1060-5.
 19. Sanli Y, Garg I, Kandathil A, Kendi T, Zanetti MJB, Kuyumcu S, Subramaniam RM () Neuroendocrine tumor diagnosis and management: ⁶⁸Ga-DOTATATE PET/CT. *Am J Roentgeno.* 2018 Aug;211(2):227-67.
 20. Strosberg J, El-Haddad G, Wolin E, Hendifar A, Yao J, Chasen B, Mittra E, Kunz PL, Kulke MH, Jacene H, Bushnell D, O'Dorisio TM, Baum RP, Kulkarni HR, Caplin M, Lebtahi R, Hobday T, Delpassand E, Van Cutsem E, Benson A, Srirajaskanthan R, Pavel M, Mora J, Berlin J, Grande E, Reed N, Seregni E, Öberg K, Lopera Sierra M, Santoro P, Thevenet T, Erion JL, Ruzsniwski P, Kwekkeboom D, Krenning E; NETTER-1 Trial Investigators. Phase 3 Trial of ¹⁷⁷Lu-Dotatate for Midgut Neuroendocrine Tumors. *N Engl J Med.* 2017 Jan 12;376(2):125-35.
 21. Wild D, Bomanji JB, Benkert P, Maecke H, Ell PJ, Reubi JC, Caplin ME. Comparison of ⁶⁸Ga-DOTANOC and ⁶⁸Ga-DOTATATE PET/CT within patients with gastroenteropancreatic neuroendocrine tumors. *J Nucl Med.* 2013 Mar;54(3):364-72.
 22. Demirci E, Ocak M, Kabasakal L, Araman A, Ozsoy Y, Kanmaz B. Comparison of Ga-68 DOTA-TATE and Ga-68 DOTA-LAN PET/CT imaging in the same patient group with neuroendocrine tumours: preliminary results. *Nucl Med Commun.* 2013 Aug;34(8):727-32.