

Changes in salivary gland function following radioiodine therapy of thyroid diseases: A comparison of high-dose therapy for thyroid cancer and low-dose therapy for benign thyroid disease

Armaghan Fard-Esfahani¹, Babak Fallahi¹, Mohammad Karimi¹, Davood Beiki¹, Mohsen Saghari¹,
Alireza Emami-Ardekani¹, Pezhman Fard-Esfahani², Mojtaba Ansari³, Mohammad Eftekhari¹

¹Research Center for Nuclear Medicine, Tehran University of Medical Sciences, Tehran, Iran

²Biochemistry Department, Pasteur Institute of Iran, Tehran, Iran

³Nuclear Medicine Department, Imam Hossein Hospital, Shahid Beheshti University of Medical Sciences, Tehran, Iran

(Received 2 January 2014, Revised 10 June 2014, Accepted 17 June 2014)

ABSTRACT

Introduction: High-dose radioactive iodine therapy in differentiated thyroid cancer (DTC) may adversely affect the salivary gland function. This study is aimed to evaluate the effect of radioactive iodine (RAI) with dose of 100 mCi in DTC patients compared to lower doses of less than 30 mCi in hyperthyroid cases.

Methods: Fifty four patients (13 men and 41 women) age: 42.3±14.3 (21-71) years were enrolled in the study. Twenty seven hyperthyroid cases received less than 30 mCi of I-131 for the treatment, and 27 DTC patients were treated with 100 mCi of I-131. All patients underwent Tc-99m pertechnetate scintigraphy before and three months after radioiodine therapy. Salivary gland excretion fractions (EF) were compared between groups. A decrease of more than 5% in EF was considered significant.

Results: The total frequency of salivary dysfunction was 41.7%. In patients received a dosage of 100 mCi of I-131, this frequency was 49.1%, while with less than 30 mCi, it was 34.3% ($p<0.01$). The right parotid gland was affected more than the left following 100 mCi treatment. Risk ratio of salivary gland involvement in high-dose versus low-dose group was significant (risk ratio=1.04-1.98, CI (95%); $p=0.019$). However, there was no significant difference in symptom presentation, i.e. xerostomia between two groups.

Conclusion: RAI therapy may cause salivary gland dysfunction and this effect is more frequent in DTC patients with higher dose of 100 mCi compared to hyperthyroid cases with lower doses of less than 30 mCi.

Key words: Salivary gland; Radioactive iodine; Xerostomia

Iran J Nucl Med 2015;23(1):1-7

Published: December, 2014

<http://irjnm.tums.ac.ir>

Corresponding author: Dr. Babak Fallahi, Research Center for Nuclear Medicine, Dr. Shariati Hospital, Tehran University of Medical Sciences, Tehran, Iran. E-mail: bfallahi@sina.tums.ac.ir

INTRODUCTION

It is more than 50 years since radio-iodine-131 (I-131) has been used as a valuable treatment of thyroid diseases including hyperthyroidism and differentiated thyroid carcinomas (DTC) [1, 2].

Physiologic uptake of radioiodine occurs in thyroid, gastric mucosa, lactating breast, and salivary glands. Salivary glands can concentrate iodine 30-40 times over the blood [2]. Radiation damage to salivary glands is suggested and supported by several studies [3-10]. It is the most common complication of radioiodine therapy [11]. Radiation sialadenitis is presented with pain, tenderness, swelling, xerostomia and bitter taste [2, 7].

Pathophysiologically, radiation causes vascular and cellular changes in salivary gland which in turn result in fibrosis and infiltration by lymphocytes and inflammatory cells [12]. Dynamic scintigraphy of salivary glands with both qualitative and quantitative assessment of function has been known as a valuable tool for the evaluation of this complication [5, 13, 14]. This method is easy to perform, reproducible and well-tolerated by the patient [2, 15-20].

The effect of radioactive iodine (RAI) doses to produce this damage has been under discussion. The studies on thyroid cancer patients show more functional impairment with higher doses [5-7, 10, 21-23], however the effect of this complication with lower doses of I-131 used for hyperthyroidism has not been widely studied.

In this study we used salivary gland scintigraphy to assess the effect of radioiodine on salivary gland function in high dose of radioiodine used for the treatment of cancer as compared to low dose for hyperthyroid patients.

METHODS

Patients

A total of 54 patients (age range: 21-71 years, mean age: 42.3 ± 14.35) were included in this study, of whom 41 (79%) were female and 13 (24.1%) were male. The first group (27 patients) consisted of known hyperthyroid patients candidates to receive radioiodine in doses less than 30 mCi (low-dose group); and the second group (27 patients) were referred for the treatment with 100 mCi RAI for the ablation therapy of differentiated thyroid carcinoma (high-dose group). Radio-iodine whole body scan was not performed before RAI treatment.

Salivary gland scintigraphy was performed in all cases before treatment as a baseline study, and three months after treatment to evaluate the effect of radioiodine on these glands.

The patients with pregnancy, previous history of external-beam radiotherapy to the head and neck, history of known salivary gland abnormalities such as tumors, obstructions, inflammation, history of interfering medications (i.e. anticholinergic drugs) and those who were unwilling to participate in the study or did not cooperate in the follow up evaluations, were excluded from the study.

Image analysis and measurements

Patients were injected with 370 MBq (10 mCi) of Tc-99m pertechnetate while fasting and resting in supine position. Immediately afterwards salivary gland scintigraphy was performed in dynamic mode for 30 min (one frame/min acquisition) with a dual head-gamma camera (S.H. Genesys, ADAC, USA) in anterior and posterior views. Low energy all purpose (LEAP) collimator with 128×128 matrix was used. To stimulate salivary secretion, 5 ml of lime juice was administered orally at 15 min of the study. For image processing, a conjugated image was constructed, and regions of interest (ROI) were drawn for each of the four major salivary glands and also for background both on temporal bone for parotid glands and neck soft tissue for submandibular glands. Analysis of the dynamic study included time-activity curves (TAC) of four salivary glands (right and left parotid and right and left submandibular). Finally salivary excretion fractions (EF) of both groups were calculated before and three months after the treatment, by calculating the percentage of difference between maximum and minimum background-corrected counts divided by the maximum background-corrected counts for each gland. Salivary gland dysfunction was defined as 5% reduction of EF after the treatment with RAI (Figure 1).

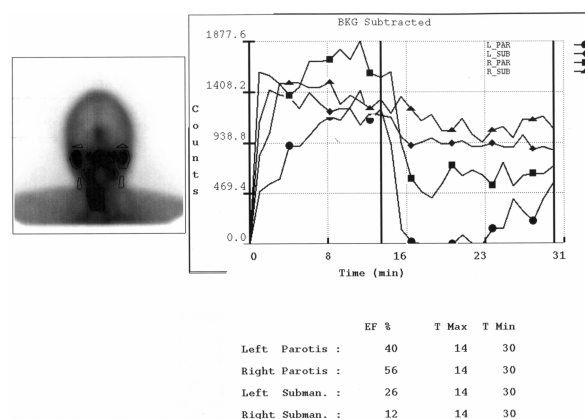


Fig 1. Quantitative scintigraphy of salivary glands in a patient treated with iodine-131.

Statistical analysis

Data analysis was performed using SPSS (v. 17) software. Mean EF of salivary glands was compared before and after the treatment by paired samples student's t-test. A 5% reduction of EF after the treatment with I-131, compared to pre-treatment stage, was considered significant and indicative of salivary gland malfunction. The relationship between EF and variables including gland type, sex, age and clinical symptoms was assessed by chi-square test. Risk ratio (RR) of salivary gland dysfunction in the high-dose group in relation to low-dose group was calculated and a 95% confidence interval (CI 95%) of this RR was reported. P value of less than 0.05 was considered significant for each analysis.

RESULTS

The female to male ratio was 21 to 6 (77.8% vs. 22.2%) in the low dose group and 20 to 7 (74.1% vs. 25.9%) in the high dose group ($p=0.750$). As well, the average age was not significantly different between low- and high-dose groups (41.5 ± 15.1 vs 43.1 ± 13.8 , respectively, $p=0.694$). All DTC patients

in high-dose group received 100 mCi. The average dose in low-dose group was 15.9 ± 5.6 mCi (10-29.9 mCi).

According to acquired data, symptoms including eye dryness (xerophthalmia) and mouth dryness (xerostomia) was not significantly different in two groups ($p=1.0$ and $p=0.54$, respectively). Hoarseness and shortness of breath have not been observed in any patients. In addition, EF as the main index of salivary gland function was not different between two groups (Table 1).

There is noticeable reduction of excretion in both groups and in each of the four salivary glands except for right submandibular gland (Table 2).

Salivary gland dysfunction occurred in 37 out of 108 glands (34.3%) treated with lower dose RAI (<30 mCi) whereas this effect was seen in 53 out of 108 glands (49.1%) in the high dose (30-100 mCi) group ($P<0.05$; Table 3).

The risk of salivary gland functional impairment is significantly more in patients received higher dose of RAI used for thyroid cancer than patients received lower dose for hyperthyroid state (Table 4).

Table 1: Comparison of excretion fraction of different salivary glands before treatment between two studied groups.

Salivary glands	Patient groups		Significance
	Hyperthyroid patients receiving <30 mCi	DTC patients receiving 30-100 mCi	
Right parotid	57.9 ± 19.2	49.8 ± 20.1	0.134
Left parotid	53.1 ± 16.9	47.4 ± 20.8	0.168
Right submandibular	33.5 ± 13.3	29.7 ± 13.2	0.289
Left submandibular	28.6 ± 12.5	28.4 ± 12.2	0.956

Table 2: Comparison of excretion fraction of all salivary glands before and after radioiodine treatment.

Salivary glands	Changes of (EF) before and after treatment in two groups		
	Before	After	P value
Right parotid	53.9 ± 19.9	50.2 ± 22.8	0.006
Left parotid	50.1 ± 19.1	46.6 ± 20.4	0.006
Right submandibular	31.6 ± 13.2	31.4 ± 15.5	0.087
Left submandibular	29.8 ± 16.8	26.0 ± 15.2	0.017

Table 3: Frequency of salivary gland dysfunction in two groups received <30 mCi for hyperthyroidism and 30-100 mCi for thyroid carcinoma.

Salivary Glands	Patient groups		
	<30 mCi	30-100 mCi	Total
Parotid glands (n=54 in each group)	15 (27.8%)	27 (50.0%)	42 (38.9%)
Submandibular glands (n=54 in each group)	22 (40.7%)	26 (48.1%)	48 (44.4%)
Total (n=108 in each group)	37 (34.3%)	53 (49.1%)	90 (41.7%)

Table 4: Risk ratio comparison of salivary gland disorders between two groups of high dose and low dose of RAI therapy.

Salivary Glands	Rate of disorder		Risk Ratio	95% Confidence Interval		P value
	30-100 mCi	<30 mCi		Lower	Upper	
Parotid	27 (50.0%)	15 (27.8%)	1.8	1.08	2.99	0.015
Submandibular	26 (48.1%)	22 (40.7%)	1.18	0.77	1.81	0.281
Total	52 (49.1%)	37 (34.3%)	1.43	1.04	1.98	0.019

DISCUSSION

Radioiodine therapy is an effective treatment for both hyperthyroidism and thyroid cancer. However, there are several complications to this therapy that need consideration in management of these patients [1, 2]. The complications that are of more importance with regard to patient survival are persistent bone marrow suppression and second primary cancers. Bone marrow failure is rare, if maximal safe dose is considered [24-26]. However, although the risk for second primary malignancies is small but it is significant [27-29]. Gonadal dysfunction is another noteworthy potential complication of RAI therapy which could be either transient or permanent in both males and females [30-33].

There are other late complications that, even though are not life threatening, can be quite troublesome and interfere with patients quality of life. These include sialadenitis with xerostomia, ageusia, lacrimal gland dysfunction, and thyroiditis [3-10, 34-37]. Ocular complications include xerophthalmia and epiphora which can be induced by nasolacrimal duct obstruction [35, 38-43]. Xerostomia and sialadenitis

are more common late complications [44]. These side effects which are the focus of this study are bothersome complications of radioiodine treatment which can reduce patients' wellness and in some cases seriously interfere with patients' quality of life due to persistent dry mouth and increased risk of dental caries [3-10, 35-37, 45]. Acute or chronic sialadenitis has been observed in 12-30% of patients receiving high dose I-131, with the time onset as short as two days to six months after the treatment, characterized by pain, tenderness, swelling, xerostomia, and bitter taste [2, 46, 47]. In view of the long survival period of patients with differentiated thyroid carcinomas attention should be drawn to this side effect.

The present study confirms that salivary gland dysfunction is a common complication with a total frequency of 41.7% in all studied patients. The proportional frequency of this complication was 34.3% in hyperthyroid patients received less than 30 mCi vs. 49.1% in DTC cases treated with higher doses of 30-100 mCi of RAI. In a previous study, using similar method, the frequency of salivary gland dysfunction in the patients treated with 100 mCi I-131 was 27.8% to 52.8% in different salivary glands, which correlates with our finding. In that study, the

rate of complication was even higher (57.1%-64.3%) in patients received 150 mCi [5]. However in Almeida et al study, there was no difference between doses higher or lower than 150 mCi in the functional ability of salivary glands [3]. Another study showed decreased excretory function of salivary glands in 22.7% of DTC patients who received RAI treatment, which is a lower rate, compared to our study [48]. However this rate was given by visual interpretation, while our study is a semiquantitative approach, in which assessment of lower degrees of functional impairment was possible. In Bohuslavizki et al study, although salivary gland stimulation with ascorbic acid was used during radioiodine therapy, a significant activity-related functional impairment of 14-90% was seen after 0.4-24 GBq of I-131 [13], which is comparable to our study. In a study by Malpani et al., the rate of damage to salivary glands after RAI for thyroid cancer was higher (72.7%) than our study (49.1%). However it should be noted that the higher I-131 dose received by patients in that study (Mean = 10.16 GBq) could explain this difference [10]. Abnormal salivary function was noted in 30% of patients after a dose up to 0.3 Ci, and in 60-80% after a dose of 0.5 to 1 Ci in another study, showing a cumulative risk of reduced function [49]. This adverse effect is related to the presence of Na⁺/I⁻ (NIS) in the salivary glands. NIS is the plasma membrane glycoprotein that mediates the active uptake of I⁻ to the thyroid for thyroid hormone biosynthesis. NIS also mediates I⁻ uptake in other tissues, such as salivary glands, gastric mucosa, and lactating (but not nonlactating) mammary gland, therefore causing function impairment due to beta emissions of therapeutic doses of radioiodine [50].

This complication, although less common following low-dose treatment of hyperthyroidism, is still remarkable in this group. Precautions to reduce this expected complication need serious application, even in patients treated with low dose of radioiodine. A lower dose of RAI can be used to reduce the probability of this disturbing complication. Prevention of the I-131 induced sialadenitis by parasympathomimetic drugs like pilocarpine is suggested. These sialogogue agents accelerate salivary flow and hence radioactive clearance from the salivary glands [51-53]. However, not all studies advocate the efficacy of this approach [54]. Amifostine is a more recent drug believed to be useful in the prevention of radiation damage through a cytoprotective effect [55-58]; yet, not supported by all authors [59, 60]. The concurrent application of physiologic sialogogues like candy and gum, adequate hydration, good oral hygiene and mouthwashes are the practical effective prevention methods [54, 55, 60-62]. Recently, a daily supplementation with 800 IU vitamin E for duration of 5 weeks (one week before to four weeks after RAI

therapy) has been introduced to potentially cause a significant protective effect against radiation-induced dysfunction in salivary glands following single high dose RAI therapy in patients with differentiated thyroid cancer [63].

The limitation of this study is that the two groups of patients were incongruent, as in low dose hyperthyroid patients, high RAI thyroid uptake may lead to less radioiodine uptake in salivary glands and consequently less expected risk of salivary dysfunction. On the other hand, the DTC patients do not receive doses less than 30 mCi and hyperthyroid cases not usually above 30 mCi, as a result selecting a homogenous group for the study was not potentially feasible.

CONCLUSION

The current study shows that RAI can reduce salivary gland function. This effect is more prominent in higher dose of 100 mCi used for thyroid carcinoma compared to lower doses of less than 30 mCi used for the treatment of hyperthyroidism. The difference of complications observed in these patients may not be only due to the RAI dose, but also to the nature of the underlying diseases leading to different RAI uptake in the salivary glands. However, the significant occurrence of this complication even after low dose of radioiodine administration signifies the importance of applying all necessary measures to reduce the potential complications as much as possible.

Acknowledgements

This study has been supported by Tehran University of Medical Sciences, grant number: 89-03-58-11200, Tehran, Iran. In addition, we would like to thank Ghazal Haddad for her in-depth effort in the preparation of this manuscript.

REFERENCES

1. Carpenter CCJ, Griggs RC, Loscalzo J. Cecil essentials of medicine, 5th ed. Philadelphia: WB Saunders; 2001. P. 555-63.
2. Silberstein EB . The treatment of thyroid malignant neoplasms. In: Henkin RE. nuclear Medicine. 2nd ed, Philadelphia: Mosby Elsevier; 2006. p. 1576-87.
3. Almeida JP, Sanabria AE, Lima EN, Kowalski LP. Late side effects of radioactive iodine on salivary gland function in patients with thyroid cancer. *Head Neck*. 2011 May;33(5):686-90.
4. Van Nostrand D. Sialoadenitis secondary to ¹³¹I therapy for well-differentiated thyroid cancer. *Oral Dis*. 2011 Mar;17(2):154-61.
5. Esfahani AF, Fallahi B, Olamaie R, Eftekhari M, Beiki D, Saghari M. Semi-quantitative assessment of salivary gland function in patients with differentiated thyroid

- carcinoma after radioiodine-131 treatment. *Hell J Nucl Med.* 2004 Sep-Dec;7(3):206-9.
6. Macioszek A, Baczyk M, Kopeć T, Sowiński J. Salivary gland damage after 131I therapy in patients with differentiated thyroid cancer. Preliminary report. *Endokrynol Pol.* 2008 Sep-Oct;59(5):403-10.
 7. Hyer S, Kong A, Pratt B, Harmer C. Salivary gland toxicity after radioiodine therapy for thyroid cancer. *Clin Oncol (R Coll Radiol).* 2007 Feb;19(1):83-6.
 8. Rosário PW, Maia FF, Barroso A, Padrão EL, Rezende L, Purisch S. Sialoadenitis following ablative therapy with high doses of radioiodine for treatment of differentiated thyroid cancer. *Arq Bras Endocrinol Metabol.* 2004 Apr;48(2):310-4.
 9. Alexander C, Bader JB, Schaefer A, Finke C, Kirsch CM. Intermediate and long-term side effects of high-dose radioiodine therapy for thyroid carcinoma. *J Nucl Med.* 1998 Sep;39(9):1551-4.
 10. Malpani BL, Samuel AM, Ray S. Quantification of salivary gland function in thyroid cancer patients treated with radioiodine. *Int J Radiat Oncol Biol Phys.* 1996 Jun 1;35(3):535-40.
 11. Kim JW, Han GS, Lee SH, Lee DY, Kim YM. Sialoendoscopic treatment for radioiodine induced sialadenitis. *Laryngoscope.* 2007 Jan;117(1):133-6.
 12. Shirazi P. Salivary glands. In: Henkin RE. *Nuclear Medicine.* New York: Mosby; 1996. P. 933-947.
 13. Bohuslavizki KH, Brenner W, Lassmann S, Tinnemeyer S, Kalina S, Clausen M, Henze E. Quantitative salivary gland scintigraphy—a recommended examination prior to and after radioiodine therapy. *Nuklearmedizin.* 1997 Apr;36(3):103-9.
 14. Mojsak MN, Rogowski F. Application scintigraphy in evaluation of salivary gland function. *Pol Merkur Lekarski.* 2010 Mar;28(165):214-9.
 15. Mishkin FS. Radionuclide salivary gland imaging. *Semin Nucl Med.* 1981 Oct;11(4):258-65.
 16. Loutfi I, Nair MK, Ebrahim AK. Salivary gland scintigraphy: the use of semiquantitative analysis for uptake and clearance. *J Nucl Med Technol.* 2003 Jun;31(2):81-5.
 17. Malpani BL, Samuel AM, Jaiswar RK. Salivary gland scintigraphy after radioiodine therapy. *Nucl Med Commun.* 1998 Feb;19(2):183-4. 1998 Feb;19(2):183-4.
 18. Pilbrow WJ, Brownless SM, Cawood JI, Dynes A, Hughes JD, Stockdale HR. Salivary gland scintigraphy—a suitable substitute for sialography? *Br J Radiol.* 1990 Mar;63(747):190-6.
 19. Schall GL, Di Chiro G. Clinical usefulness of salivary gland scanning. *Semin Nucl Med.* 1972 Jul;2(3):270-7.
 20. Sorsdahl OA, Williams CM, Bruno FP. Scintillation camera scanning of the salivary glands. *Radiology.* 1969 Jun;92(7):1477-80.
 21. Caglar M, Tuncel M, Alpar R. Scintigraphic evaluation of salivary gland dysfunction in patients with thyroid cancer after radioiodine treatment. *Clin Nucl Med.* 2002 Nov;27(11):767-71.
 22. Jentzen W, Schneider E, Freudenberg L, Eising EG, Görges R, Müller SP, Brandau W, Bockisch A. Relationship between cumulative radiation dose and salivary gland uptake associated with radioiodine therapy of thyroid cancer. *Nucl Med Commun.* 2006 Aug;27(8):669-76.
 23. Raza H, Khan AU, Hameed A, Khan A. Quantitative evaluation of salivary gland dysfunction after radioiodine therapy using salivary gland scintigraphy. *Nucl Med Commun.* 2006 Jun;27(6):495-9.
 24. Macey DJ, DeNardo SJ, DeNardo GL, DeNardo DA, Shen S. Estimation of radiation absorbed doses to the red marrow in radioimmunotherapy. *Clin Nucl Med.* 1995 Feb;20(2):117-25.
 25. Lassmann M, Reiners C, Luster M. Dosimetry and thyroid cancer: the individual dosage of radioiodine. *Endocr Relat Cancer.* 2010 Jun 3;17(3):R161-72.
 26. Lee JJ, Chung JK, Kim SE, Kang WJ, Park do J, Lee DS, Cho BY, Lee MC. Maximal safe dose of I-131 after failure of standard fixed dose therapy in patients with differentiated thyroid carcinoma. *Ann Nucl Med.* 2008 Nov;22(9):727-34.
 27. Rubino C, de Vathaire F, Dottorini ME, Hall P, Schwartz C, Couette JE, Dondon MG, Abbas MT, Langlois C, Schlumberger M. Second primary malignancies in thyroid cancer patients. *Br J Cancer.* 2003 Nov 3;89(9):1638-44.
 28. Brown AP, Chen J, Hitchcock YJ, Szabo A, Shrieve DC, Tward JD. The risk of second primary malignancies up to three decades after the treatment of differentiated thyroid cancer. *J Clin Endocrinol Metab.* 2008 Feb;93(2):504-15.
 29. Fallahi B, Adabi K, Majidi M, Fard-Esfahani A, Heshmat R, Larijani B, Haghpanah V. Incidence of second primary malignancies during a long-term surveillance of patients with differentiated thyroid carcinoma in relation to radioiodine treatment. *Clin Nucl Med.* 2011 Apr;36(4):277-82.
 30. Esfahani AF, Eftekhari M, Zenooz N, Saghari M. Gonadal function in patients with differentiated thyroid cancer treated with (131)I. *Hell J Nucl Med.* 2004 Jan-Apr;7(1):52-5.
 31. Fard-Esfahani A, Hadifar M, Fallahi B, Beiki D, Eftekhari M, Saghari M, Takavar A. Radioiodine treatment complications to the mother and child in patients with differentiated thyroid carcinoma. *Hell J Nucl Med.* 2009 Jan-Apr;12(1):37-40.
 32. Hall P, Holm LE, Lundell G, Bjelkengren G, Larsson LG, Lindberg S, Tennvall J, Wicklund H, Boice JD Jr. Cancer risks in thyroid cancer patients. *Br J Cancer.* 1991 Jul;64(1):159-63.
 33. Sarkar SD, Beierwaltes WH, Gill SP, Cowley BJ. Subsequent fertility and birth histories of children and adolescents treated with 131I for thyroid cancer. *J Nucl Med.* 1976 Jun;17(6):460-4.
 34. Lee SL. Complications of radioactive iodine treatment of thyroid carcinoma. *J Natl Compr Canc Netw.* 2010 Nov;8(11):1277-86; quiz 1287.
 35. Fard-Esfahani A, Mirshekarpour H, Fallahi B, Eftekhari M, Saghari M, Beiki D, Ansari-Gilani K, Takavar A. The effect of high-dose radioiodine treatment on lacrimal gland function in patients with differentiated thyroid carcinoma. *Clin Nucl Med.* 2007 Sep;32(9):696-9.
 36. Solans R, Bosch JA, Galofré P, Porta F, Roselló J, Selva-O'Callagan A, Vilardell M. Salivary and lacrimal gland dysfunction (sicca syndrome) after radioiodine therapy. *J Nucl Med.* 2001 May;42(5):738-43.

37. Fard-Esfahani A, Farzanefar S, Fallahi B, Beiki D, Saghari M, Emami-Ardekani A, Majdi M, Eftekhari M. Nasolacrimal duct obstruction as a complication of iodine-131 therapy in patients with thyroid cancer. *Nucl Med Commun.* 2012 Oct;33(10):1077-80.
38. Gholamrezaezhad A, Fard-Esfahani A, Sadeghi-Tari A, Mirpour S, Saghari M, Eftekhari M, Fallahi B, Beiki D, Poormoslemi A, Tarbiat A. Quantitative assessment of dacryoscintigraphic images in the evaluation of epiphora. *Orbit.* 2007 Dec;26(4):229-35.
39. Burns JA, Morgenstern KE, Cahill KV, Foster JA, Jhiang SM, Kloos RT. Nasolacrimal obstruction secondary to I(131) therapy. *Ophthal Plast Reconstr Surg.* 2004 Mar;20(2):126-9.
40. Zettinig G, Hanselmayer G, Fueger BJ, Hofmann A, Pirich C, Nepp J, Dudczak R. Long-term impairment of the lacrimal glands after radioiodine therapy: a cross-sectional study. *Eur J Nucl Med Mol Imaging.* 2002 Nov;29(11):1428-32.
41. Shepler TR, Sherman SI, Faustina MM, Busaidy NL, Ahmadi MA, Esmaeli B. Nasolacrimal duct obstruction associated with radioactive iodine therapy for thyroid carcinoma. *Ophthal Plast Reconstr Surg.* 2003 Nov;19(6):479-81.
42. Kloos RT, Duvuuri V, Jhiang SM, Cahill KV, Foster JA, Burns JA. Nasolacrimal drainage system obstruction from radioactive iodine therapy for thyroid carcinoma. *J Clin Endocrinol Metab.* 2002 Dec;87(12):5817-20.
43. Fard-Esfahani A, Gholamrezaezhad A, Mirpour S, Tari AS, Saghari M, Beiki D, Sichani BF, Eftekhari M. Assessment of the accuracy of lacrimal scintigraphy based on a prospective analysis of patients' symptomatology. *Orbit.* 2008;27(4):237-41.
44. Van Nostrand D. The benefits and risks of I-131 therapy in patients with well-differentiated thyroid cancer. *Thyroid.* 2009 Dec;19(12):1381-91.
45. Walter MA, Turtzsch CP, Schindler C, Minnig P, Müller-Brand J, Müller B. J Nucl Med. The dental safety profile of high-dose radioiodine therapy for thyroid cancer: long-term results of a longitudinal cohort study. *J Nucl Med.* 2007 Oct;48(10):1620-5.
46. Allweiss P, Braunstein GD, Katz A, Waxman A. Sialadenitis following I-131 therapy for thyroid carcinoma: concise communication. *J Nucl Med.* 1984 Jul;25(7):755-8.
47. Maxon HR 3rd, Smith HS. Radioiodine-131 in the diagnosis and treatment of metastatic well differentiated thyroid cancer. *Endocrinol Metab Clin North Am.* 1990 Sep;19(3):685-718.
48. An YS, Yoon JK, Lee SJ, Song HS, Yoon SH, Jo KS. Symptomatic late-onset sialadenitis after radioiodine therapy in thyroid cancer. *Ann Nucl Med.* 2013 May;27(4):386-91.
49. Albrecht HH, Creutzig H. Salivary gland scintigraphy after radio-iodine therapy. Functional scintigraphy of the salivary gland after high dose radio-iodine therapy. *Rofo.* 1976 Dec;125(6):546-51.
50. Dadachova E, Carrasco N. The Na/I symporter (NIS): imaging and therapeutic applications. *Semin Nucl Med.* 2004 Jan;34(1):23-31.
51. Aframian DJ, Helcer M, Livni D, Markitziu A. Pilocarpine for the treatment of salivary glands' impairment caused by radioiodine therapy for thyroid cancer. *Oral Dis.* 2006 May;12(3):297-300.
52. Almeida JP, Kowalski LP. Pilocarpine used to treat xerostomia in patients submitted to radioactive iodine therapy: a pilot study. *Braz J Otorhinolaryngol.* 2010 Sep-Oct;76(5):659-62.
53. Fard-Esfahani A, Modarress Mosalla MM, Haddad P, Eftekhari M, Saghari M. Quantitative assessment of salivary gland function by radioisotopic scanning in a randomized trial of Pilocarpine for prevention of radiation induced Xerostomia. *Iran J Nucl Med.* 2001;9(1):11-20.
54. Silberstein EB. J Nucl Med. Reducing the incidence of 131I-induced sialadenitis: the role of pilocarpine. *J Nucl Med.* 2008 Apr;49(4):546-9.
55. Mandel SJ, Mandel L. Radioactive iodine and the salivary glands. *Thyroid.* 2003 Mar;13(3):265-71.
56. Mendoza A, Shaffer B, Karakla D, Mason ME, Elkins D, Goffman TE. Quality of life with well-differentiated thyroid cancer: treatment toxicities and their reduction. *Thyroid.* 2004 Feb;14(2):133-40.
57. Kutta H, Kampen U, Sagowski C, Brenner W, Bohuslavizki KH, Paulsen F. Amifostine is a potent radioprotector of salivary glands in radioiodine therapy. Structural and ultrastructural findings. *Strahlenther Onkol.* 2005 Apr;181(4):237-45.
58. Bohuslavizki KH, Klutmann S, Brenner W, Kröger S, Buchert R, Bleckmann C, Mester J, Henze E, Clausen M. Radioprotection of salivary glands by amifostine in high-dose radioiodine treatment. Results of a double-blinded, placebo-controlled study in patients with differentiated thyroid cancer. *Strahlenther Onkol.* 1999 Nov;175 Suppl 4:6-12.
59. Kim SJ, Choi HY, Kim IJ, Kim YK, Jun S, Nam HY, Kim JS. Limited cytoprotective effects of amifostine in high-dose radioactive iodine 131-treated well-differentiated thyroid cancer patients: analysis of quantitative salivary scan. *Thyroid.* 2008 Mar;18(3):325-31.
60. Ma C, Xie J, Jiang Z, Wang G, Zuo S. Does amifostine have radioprotective effects on salivary glands in high-dose radioactive iodine-treated differentiated thyroid cancer. *Eur J Nucl Med Mol Imaging.* 2010 Aug;37(9):1778-85.
61. Nakada K, Ishibashi T, Takei T, Hirata K, Shinohara K, Katoh S, Zhao S, Tamaki N, Noguchi Y, Noguchi S. Does lemon candy decrease salivary gland damage after radioiodine therapy for thyroid cancer? *J Nucl Med.* 2005 Feb;46(2):261-6.
62. Van Nostrand D, Bandaru V, Chennupati S, Wexler J, Kulkarni K, Atkins F, Mete M, Gadwale G. Radiopharmacokinetics of radioiodine in the parotid glands after the administration of lemon juice. *Thyroid.* 2010 Oct;20(10):1113-9.
63. Fallahi B, Beiki D, Abedi SM, Saghari M, Fard-Esfahani A, Akhzari F, Mokarami B, Eftekhari M. Does vitamin E protect salivary glands from I-131 radiation damage in patients with thyroid cancer? *Nucl Med Commun.* 2013 Aug;34(8):777-86.