

Diagnostic dilemma of ectopic pelvic kidney in planar skeletal and renal cortical scintigraphy resolved by SPECT/CT

Tarun Kumar Jain¹, Rajender Kumar Basher¹,
Bhagwant Rai Mittal¹, Anish Bhattacharya¹, Santosh K. Singh²

¹Department of Nuclear Medicine and PET and ²Department of Urology,
Post Graduate Institute of Medical Education and Research, Chandigarh, India

(Received 17 June 2015, Revised 17 August 2015, Accepted 20 August 2015)

ABSTRACT

We present a 55-year old male patient who was subjected to whole body skeletal scintigraphy for metastatic work up of urinary bladder cancer. Whole body ^{99m}Tc-methylene diphosphonate (MDP) skeletal scintigraphy was performed. That revealed no skeletal metastasis in the entire body skeleton and normally visualized left kidney with empty right renal fossa. Additionally tracer activity collected in pelvic region giving impression of ectopically placed kidney. To rule out ectopic pelvic kidney ^{99m}Tc-DMSA (Di-mercaptosuccinic acid) renal cortical imaging was performed. The cortical scintigraphy revealed bean shape tracer activity in pelvis simulating kidney, in addition to normal left kidney. However faint tracer activity is also localized in the right renal fossa. To differentiate malfunctioning kidney, gall bladder or intestinal tracer activity Single photon emission tomography/computed tomography (SPECT/CT) was acquired and images revealed abnormal tracer collection in pelvis was a localized urinary tracer activity in bladder and right kidney was small with impaired function.

Key words: Bladder cancer; Skeletal scintigraphy; Renal cortical scintigraphy; Ectopic pelvic kidney; SPECT/CT

Iran J Nucl Med 2016;24(1):69-71

Published: January, 2016

<http://irjnm.tums.ac.ir>

Corresponding author: Dr. Rajender Kumar Basher, MD, Assistant Professor, Department of Nuclear Medicine and PET, Post Graduate Institute of Medical Education and Research, Chandigarh-160012, India. E-mail: drrajender2010@gmail.com

CASE REPORT

A 55-year old male patient with bladder carcinoma was subjected to ^{99m}Tc -methylene diphosphonate (MDP) skeletal scintigraphy to assess skeletal metastasis before surgery. On history and examination, patient had difficulty in micturation since 2 months however history of pain was absent. After three hours of intravenous injection of 740 MBq of ^{99m}Tc -MDP, whole body bone scan was acquired, that revealed physiological tracer distribution in whole skeleton with normally located left kidney (Figure 1).

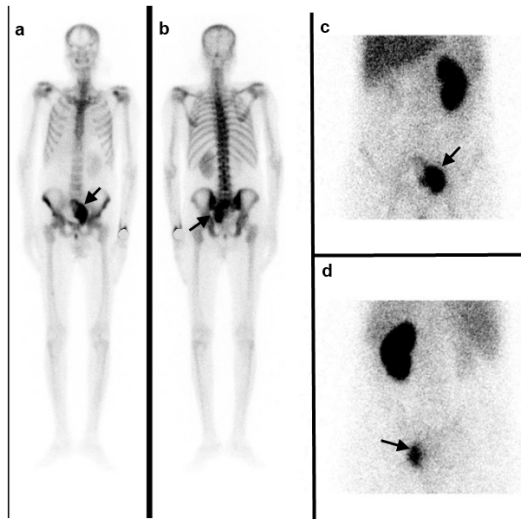


Fig 1. ^{99m}Tc -MDP skeletal scintigraphy images anterior and posterior (a, b) show physiological tracer uptake in whole skeleton. Left kidney is localized in normal location while nonvisualization of tracer activity in right renal fossa. In addition to this, pelvic tracer activity (arrow) was also noticed giving impression of ectopic pelvic kidney. For confirmation of pelvic kidney, ^{99m}Tc -DMSA renal cortical scintigraphy was acquired. In anterior and posterior (c, d) projections, shows normally located left kidney with additional tracer activity in pelvis simulating ectopic kidney (arrow).

Right renal fossa was seemed to be empty with additional tracer activity in the pelvis, which was giving appearance of ectopic pelvic kidney. To rule out pelvic kidney, after three hours intravenous injection of 185 MBq of ^{99m}Tc -DMSA (Dimercaptosuccinic acid) and bladder catheterization, renal cortical scintigraphic images were acquired, which revealed normally located left kidney with additional tracer activity in pelvis simulating ectopic kidney. However faint tracer activity was also noticed in right renal fossa. To differentiate tracer activity in right renal fossa as malfunctioning kidney, gall bladder or intestinal tracer activity, SPECT/CT images were acquired (Figure 2). The images revealed normally located both kidneys with severely impaired functioning right kidney however function of left kidney was normal. The abnormal tracer collection in pelvis was a localized urinary tracer activity in bladder which was pushed laterally, due to intra-luminal right side bladder mass. The bladder mass was histological proven as transitional cell carcinoma. The chronically obstructed vesicoureteric junction due to bladder mass was a possible reason for impaired functioning small sized right kidney.

DISCUSSION

^{99m}Tc -MDP skeletal scintigraphy is commonly used for detection of altered skeleton metabolism [1]. ^{99m}Tc -MDP is predominantly excreted by the kidney with have half life of three to four minutes in normal renal function [2, 3]. So visualization of normal functioning kidneys is a routine phenomenon. In our case left kidney was visualized in normal position while right renal fossa was empty and pelvic tracer activity gave impression of ectopic pelvic kidney.

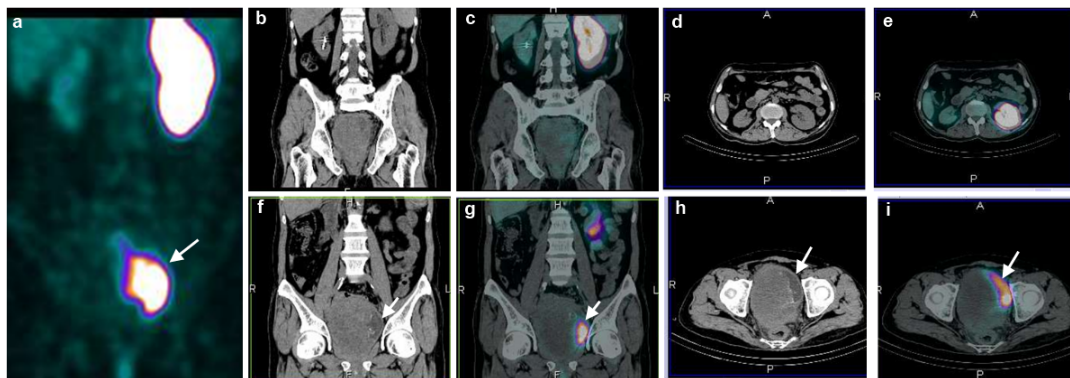


Fig 2. SPECT/CT and CT images (a) maximum intensity projection, (b, c, d, e) sagittal and (f, g, h, i) coronal images revealed normally located both kidneys. Right kidney was small sized and showing impaired cortical tracer uptake while left kidney was normal. Localized tracer activity in pelvis (arrow) was urinary activity in bladder which was pushed laterally, due to intra-luminal right side bladder mass.

To rule out ectopically positioned kidney, renal cortical scintigraphy is commonly used [4, 5]. ^{99m}Tc -DMSA showing pre-dominantly cortical localization and only slows urinary excretion. Slow concentration permits better definition of renal structure [6, 7]. To differentiate the pelvic tracer activity is due to bladder or ectopic kidney, post voiding or post bladder catheterization images should also be acquired. However in our case, DMSA images were acquired after bladder catheterization. Extrarenal excretion of DMSA by hepatic route and around 2% of injected activity remain in intestine at 24 hours [7, 8]. Extrarenal excretion also increased when renal function is hampered [7]. In our case we thought visualized tracer activity in intestine could be gall bladder or localized intestinal activity. To evaluate this SPECT/CT was acquired that revealed tracer activity in pelvic region was a localized urinary collection in bladder and tracer activity in right renal fossa was due to small impaired right kidney. SPECT-CT imaging was not performed in the first place during bone scintigraphy after finding abnormal pelvic activity in planar images. Bone scintigraphy with SPECT-CT (FOV covering abdominal and pelvic regions) could also lead to the same findings of atrophic right kidney and urinary activity deviated by bladder mass, hence obviating the need for additional renal scan in this case of "Known" Bladder Tumor.

CONCLUSION

DMSA is a good imaging modality to evaluate functional renal parenchyma and provide better information about outline of renal parenchyma, however in suspected cases as occurred in our case collaboration of radiological imaging should be done. This case emphasizes planar skeletal scan, renal cortical scan and SPECT-CT imaging are better linked together and need the careful evaluation of the planar image findings before arriving at the final conclusion.

REFERENCES

1. Wong KK, Piert M. Dynamic bone imaging with ^{99m}Tc -labeled diphosphonates and ^{18}F -NaF: mechanisms and applications. *J Nucl Med.* 2013 Apr;54(4):590-9.
2. Moore AE, Blake GM, Fogelman I. Quantitative measurements of bone remodeling using ^{99m}Tc -methylene diphosphonate bone scans and blood sampling. *J Nucl Med.* 2008 Mar;49(3):375-82.
3. Blake GM, Siddique M, Frost ML, Moore AE, Fogelman I. Radionuclide studies of bone metabolism: do bone uptake and bone plasma clearance provide equivalent measurements of bone turnover? *Bone.* 2011 Sep;49(3):537-42.
4. Yee CA, Lee HB, Blaufox MD. Tc-^{99m} DMSA renal uptake: influence of biochemical and physiologic factors. *J Nucl Med.* 1981 Dec;22(12):1054-8.
5. Ritchie G, Wilkinson AG, Prescott RJ. Comparison of differential renal function using technetium- 99m mercaptoacetyl triglycine (MAG3) and technetium- 99m dimercaptosuccinic acid (DMSA) renography in a paediatric population. *Pediatr Radiol.* 2008 Aug;38(8):857-62.
6. Weyer K, Nielsen R, Petersen SV, Christensen EI, Rehling M, Birn H. Renal uptake of ^{99m}Tc -dimercaptosuccinic acid is dependent on normal proximal tubule receptor-mediated endocytosis. *J Nucl Med.* 2013 Jan;54(1):159-65.
7. Müller-Surr R, Prigent A. Radiopharmaceuticals: their intrarenal handling and localization. In: Ell PJ, Gambhir SS. *Nuclear Medicine in clinical diagnosis and treatment.* 3rd ed. Edinburgh: Churchill Livingstone; 2005. P. 1501-15.
8. Arora G, Damle NA, Tripathi M, Bal C, Kumar P. Vicarious visualization of gall bladder on Tc-^{99m} ethylene dicysteine renal dynamic study. *Indian J Nucl Med.* 2012 Oct;27(4):257-8.