

## Diagnostic uncertainty of isolated skull lesion in prostate cancer: Role of SPECT/CT

Tarun Kumar Jain, Rohit Kumar Phulsunga, Ashwani Sood,  
Anish Bhattacharya, Bhagwant Rai Mittal

Department of Nuclear Medicine and PET,  
Post Graduate Institute of Medical Education and Research, Chandigarh, India

(Received 25 August 2015, Revised 21 October 2015, Accepted 21 October 2015)

### ABSTRACT

Skeletal involvement is the second most common site of metastases after lymph nodal metastases in patients with prostate cancer. The skeletal metastases from prostate cancer are osteoblastic in nature and show increased tracer avidity on the bone scan. Focal tracer avid lesion in skeleton especially in skull requires the careful examination by further investigation. The patients with skull metastases are commonly asymptomatic at presentation, but some may have the mass lesion effect. The occurrence of solitary skull metastatic lesion is rare and the metastasis in the existing tracer uptake should be ruled out with the help of high resolution or hybrid imaging modality. We present a known case of prostate cancer who presented with pain in the right temporal region and highlight the utility of the single photon emission computed tomography/computed tomography (SPECT/CT) imaging in localization and characterization of the isolated focal tracer uptake in the skull region found in bone scan.

**Key words:** Prostate cancer; Mastoiditis; Skull metastasis; Skeletal scintigraphy; SPECT/CT

**Iran J Nucl Med** 2016;24(1):72-75

Published: January, 2016

<http://irjnm.tums.ac.ir>

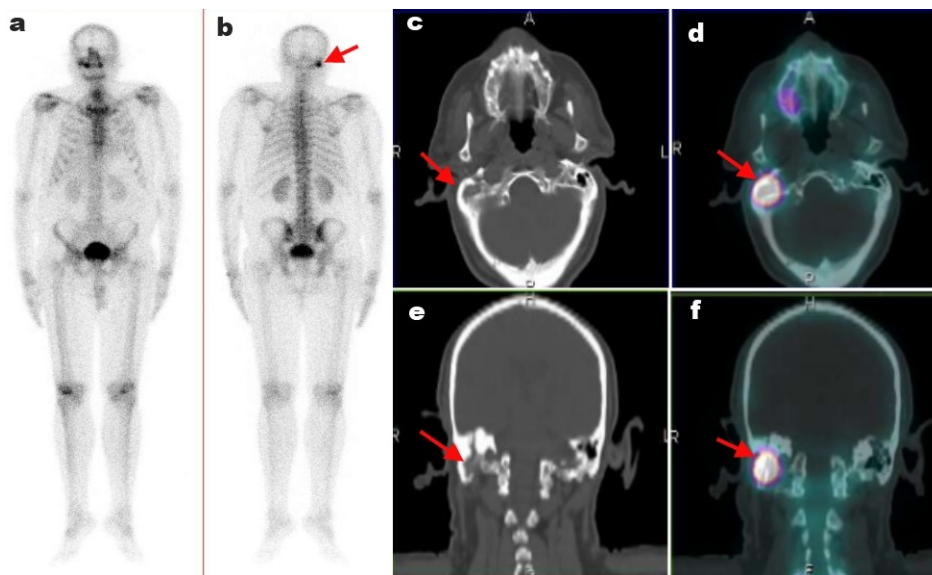
**Corresponding author:** Dr. Ashwani Sood, Department of Nuclear Medicine and PET, Post Graduate Institute of Medical Education and Research, Chandigarh-160012, India. E-mail: [sood99@yahoo.com](mailto:sood99@yahoo.com)

## INTRODUCTION

Skeleton is the second common site for distant metastases in patients with prostate cancer after lymph nodes. Different anatomical as well as functional imaging modalities have been used for detection and characterization of metastatic sites. Among them, skeletal scintigraphy (SS) has been widely used as initial modality for assessment of bony metastasis. It provides the image of whole-body skeletal system [1]. SS has shown the high sensitive in detection of bony metastasis though its specificity is poor. The low specificity is due to increased MDP tracer uptake in conditions with altered bone metabolism like trauma and inflammation in addition to metastases [2]. Skull bone metastases are not common in prostatic cancer patients and solitary lesion is rarer. Skull bones are flat bone and prone for traumatic lesions. Hence proper characterization of isolated skull lesions seen on SS is absolute necessary. Single-photon emission computed tomography/ computed tomography (SPECT/CT) provides combined anatomical and functional imaging details and accurately localizes the tracer activity compared to skeletal scintigraphy [3]. The accurate solitary skull lesion characterization is essential. The aim of the present case report is to highlight the additional role of SPECT/CT in solitary skull tracer uptake during planar bone scintigraphy which avoided the upstaging of the disease and resulted in the correct management.

## CASE REPORT

We present a 69-year-old male patient with prostate cancer, referred for bone scan to rule out skeletal metastasis. The history and examination of the patient was non-contributory and his PSA level was within normal limit (4.0ng/ml). He underwent bilateral orchidectomy without any chemotherapy and hormonal treatment six months prior to his bone scan. After 3 hours of intravenous injection of 740 MBq of Tc-99m methylene diphosphonate (MDP), whole body bone scan was acquired in anterior and posterior views that revealed a solitary focus of increased radiotracer uptake in right temporal bone with no other abnormal tracer uptake noted in the rest of the skeletal system (Figure 1 a and b). To rule out the contamination at the site of tracer uptake, the repeat scan after cleaning of that region, showed no change in the finding. The hybrid SPECT/CT images of skull were acquired for the characterization of the solitary tracer uptake in bone scan as the presence of solitary skeletal metastasis in the patient of prostate cancer would change the staging and further management. Hybrid SPECT/CT images showed focal increased tracer uptake in the mastoid part of right temporal bone with soft tissue in mastoid cavity, minimal sclerosis and loss of mastoid air cells, likely due to mastoiditis (Figure 1 c, d, e and f). The careful history evaluation revealed that the patient had the chronic suppurative otitis media of right ear for which he was medically treated. The further clinical follow-up of the patient revealed the resolution of symptoms.



**Fig 1.** A 69-year old male patient with prostate carcinoma. Tc99m-MDP planar skeletal scintigraphy, anterior (a) and posterior (b) views: show abnormal focal increased tracer uptake in right temporal bone. SPECT/CT of the skull performed to rule out metastasis. Axial and coronal computed tomography (CT) (c,e) and SPECT/CT (d,f) images show increased tracer uptake in the mastoid part of right temporal bone, corresponding CT images show soft tissue in mastoid cavity, minimal sclerosis and loss of mastoid air cells (arrow: right mastoid bone) In this case, SPECT/CT skull characterized the planar scintigraphy indeterminate lesion as benign in nature.

**Table 1:** SPECT/CT vs. planar scintigraphy for characterization of isolated skull lesions.

| Review of literatures    |   |  |   |
|--------------------------|---|--|---|
| Sharma P et al [3]       | 32 cancer patients with 36 isolated skull lesions                             | -                                      | SPECT/CT was better than planar bone scintigraphy and SPECT alone for correctly characterizing isolated skull lesions.                      |
| McLoughlin LC et al [11] | 54 prostate cancer patients with skeleton metastases at 13 areas (2 in skull) | Median PSA:13.9 (range: 4.2- 215ng/ml) | SPECT/CT improved diagnostic accuracy of PBS in detecting skeletal metastasis.  |
| Gayed IW et al [12]      | 19 cancer patients with 19 isolated skull lesions                             | -                                      | SPECT/CT could help identify benign versus metastatic solitary skull lesions in most of the patients with high sensitivity and specificity. |
| Horger M et al [13]      | 104 lesions in 47 cancer patients   | -                                      | Transmission Emission Tomography (TET) improved accuracy of bone scintigraphy by correctly classifying equivocal lesions.                   |
| Present case             | 1 lesion in skull   | PSA: 4ng/ml                            | SPECT/CT helped in lesion characterization.   |

## DISCUSSION

Bone metastases in skull and skull base are less frequent in prostate cancer patients with the incidence of 8% and 1.7% respectively [4, 5]. The metastases to the skull commonly arise from cancer of breast followed by lung, melanoma and prostate. The sclerotic metastases are commonly found in prostate and breast, and show increased MDP tracer uptake on the bone scan [6]. Majority of the patients are asymptomatic, though some may have the mass effect on adjacent structures and that may lead to severe disability due to compression of dural sinuses, cranial nerves and brain parenchyma [7]. The diagnosis of the metastatic disease should be established at the earliest as the limited metastatic disease has shown the better results than the widespread disease [8]. It has been shown that negative PSA does not exclude the presence of brain metastasis [9, 10]. The planar bone scintigraphy is not an accurate imaging modality for characterization of solitary skull lesion. Planar bone scintigraphy has shown the poor specificity than SPECT/CT for isolated skull lesion as shown in Table 1 [3, 11-13]. Hybrid SPECT/CT combines both the functional information of SPECT and anatomical information of CT, with a higher specificity of approximately 92% [3]. Solitary lesions present in the brain or skull require aggressive investigation in the prostate cancer patients due to their rarity and the other probable causes with similar presentation. The prognosis and management of other conditions differ substantially from metastatic bone disease secondary to prostate cancer. Chronic mastoiditis is common inflammatory disease that shows tracer avidity due to inflammation and reactive bone changes.

## CONCLUSION

This case report shows the importance of careful evaluation of skull lesions especially solitary in nature by SPECT/CT before arriving at the conclusion.

## REFERENCES

1. Hamaoka T, Madewell JE, Podoloff DA, Hortobagyi GN, Ueno NT. Bone imaging in metastatic breast cancer. *J Clin Oncol.* 2004 Jul 15;22(14):2942-53.
2. Rybak LD, Rosenthal DI. Radiological imaging for the diagnosis of bone metastases. *Q J Nucl Med.* 2001 Mar;45(1):53-64.
3. Sharma P, Jain TK, Reddy RM, Faizi NA, Bal C, Malhotra A, Kumar R. Comparison of single photon emission computed tomography-computed tomography, computed tomography, single photon emission computed tomography and planar scintigraphy for characterization of isolated skull lesions seen on bone scintigraphy in cancer patients. *Indian J Nucl Med.* 2014 Jan;29(1):22-9.
4. Bubendorf L, Schöpfer A, Wagner U, Sauter G, Moch H, Willi N, Gasser TC, Mihatsch MJ. Metastatic patterns of prostate cancer: an autopsy study of 1,589 patients. *Hum Pathol.* 2000 May;31(5):578-83.
5. Long MA, Husband JE. Features of unusual metastases from prostate cancer. *Br J Radiol.* 1999 Oct;72(862):933-41.
6. Gnanasegaran G, Cook G, Adamson K, Fogelman I. Patterns, variants, artifacts, and pitfalls in conventional radionuclide bone imaging and SPECT/CT. *Semin Nucl Med.* 2009 Nov;39(6):380-95.
7. Rotta FT, Romano JG. Skull base metastases causing acute bilateral hypoglossal nerve palsy. *J Neurol Sci.* 1997 May 1;148(1):127-9.
8. Stark AM, Eichmann T, Mehdorn HM. Skull metastases: clinical features, differential diagnosis, and

- review of the literature. *Surg Neurol.* 2003 Sep;60(3):219-25; discussion 225-6.
9. Ferverza FC, Wolanskyj AP, Eklund HE, Richardson RL. Brain metastasis: an unusual complication from prostatic adenocarcinoma. *Mayo Clin Proc.* 2000 Jan;75(1):79-82.
  10. Salvati M, Frati A, Russo N, Brogna C, Piccirilli M, D'Andrea G, Occhiogrosso G, Pichierri A, Caroli E. Brain metastasis from prostate cancer. Report of 13 cases and critical analysis of the literature. *J Exp Clin Cancer Res.* 2005 Jun;24(2):203-7.
  11. McLoughlin LC, O'Kelly F, O'Brien C, Sheikh M, Feeney J, Torreggiani W, Thornhill JA. The improved accuracy of planar bone scintigraphy by adding single photon emission computed tomography (SPECT-CT) to detect skeletal metastases from prostate cancer. *Ir J Med Sci.* 2014 Nov 14. [Epub ahead of print].
  12. Gayed IW, Kim EE, Awad J, Joseph U, Wan D, John S. The value of fused SPECT/CT in the evaluation of solitary skull lesion. *Clin Nucl Med.* 2011 Jul;36(7):538-41.
  13. Horger M, Eschmann SM, Pfannenbergs C, Vonthein R, Besenfelder H, Claussen CD, Bares R. Evaluation of combined transmission and emission tomography for classification of skeletal lesions. *AJR Am J Roentgenol.* 2004 Sep;183(3):655-61.