

Results of the radioguided surgeries among the patients with pathological nipple discharge

Ahmet Dag¹, Mustafa Berkesoglu¹, Fulya Kasirga Celik²,
Mehmet Ozgur Turkmenoglu¹, Ferah Tuncel³, Zehra Pinar Koc⁴

¹Department of General Surgery, Mersin University, Faculty of Medicine, Mersin, Turkey

²Department of General Surgery, Bulanik State Hospital, Mus, Turkey

³Department of Pathology, Mersin University, Faculty of Medicine, Mersin, Turkey

⁴Department of Nuclear Medicine, Mersin University, Faculty of Medicine, Mersin, Turkey

(Received 23 October 2020, Revised 9 February 2021, Accepted 15 February 2021)

ABSTRACT

Introduction: Nipple discharge is the third most common complaint of the breast diseases following the breast mass and the breast pain. The majority of the lesions causing pathological nipple discharge (PND) consist of non-palpable breast lesions (NPBLs). When non-operative diagnostic tools are inadequate to distinguish the diagnosis, the pathological duct should be removed to obtain definitive diagnosis. In this study, we aimed to present the results of radioguided surgery for NPBLs in patients with PND.

Methods: Patients with PND who underwent radioguided occult lesion localization (ROLL) and excision in our tertiary care referral center were included in this study. Patients were evaluated in detail for age, gender, clinical data, radiological data, marking procedure, surgical results, pathological results, complication rates, local recurrence rates and follow-up period.

Results: A total of 66 patients (98.5%) were able to successfully localize the lesion with ROLL. Lesions were marked with ultrasonography (USG) in 81.8% patients (n=54), while the rate of marking with mammography (MMG) was 18.2% (n=12). The mean time duration of preoperative marking was 14±4.3 minutes. The mean operation time was determined as 35 ± 12 minutes. Malignancy was detected in 19.7% of the patients (n=13). Surgical margin negativity was achieved in 92.3% (n=12) of patients with malignancy. No local recurrence was detected during the follow-up period (median 62(12-116) months).

Conclusion: In our study, it has been shown that radioguided occult lesion localization and excision can be easily performed technically for non-palpable breast lesions in patients with pathological nipple discharge and provides sufficient safe surgical margins with acceptable cosmetic results.

Key words: Breast; Nipple discharge; Radionuclide; Surgery

Iran J Nucl Med 2021;29(2):52-57

Published: July, 2021

<http://irjnm.tums.ac.ir>

Corresponding author: Dr. Mustafa Berkesoglu, Department of General Surgery, Faculty of Medicine, Mersin University, Mersin, Turkey. E-mail: berkesoglu@yahoo.com

INTRODUCTION

Nipple discharge is the third most common complaint of the breast diseases following the breast mass and the breast pain, and it constitutes 5-10% of the admissions [1-3]. Although the cause of nipple discharge is often benign pathologies, about 20-28% of the cases may be associated with breast cancer. Pathological nipple discharge (PND) is defined as spontaneous and unilateral discharge from a single ductus, and it mostly has serous, seroanguinous or bloody appearance [1, 3, 4]. During accurate evaluation of the patients with PND; the patients are initially evaluated with anamnesis and physical examination. Further investigations are obtained with radiological methods such as ultrasonography (USG), mammography (MMG), magnetic resonance imaging (MRI), ductography and ductoscopy [2, 5]. MMG and USG are the standard imaging methods that are used in the evaluation for eligible patients presenting with breast complaints. However, standard imaging methods may be inadequate to distinguish the diagnosis. MRI is a radiological method with high sensitivity and specificity that is used in patients whose breast lesions cannot be detected by the standard diagnostic methods [5]. The use of galactography and ductoscopy is limited; they are available only in a few centers.

The primary tools for the diagnosis of non-palpable breast lesions (NPBLs) are image-guided fine needle aspiration biopsy (FNAB), tru-cut biopsy and vacuum-assisted biopsy (VAB) [6]. However, it is difficult to perform these biopsies for intraductal pathologies. Additionally, cytological examination of the nipple discharge usually remains inconclusive. Therefore, it may be necessary to excise the central part of the retroareolar region or the involved ductus in order to diagnose the high cancer risk lesions in patients with PND. Blind surgery without marking for NPBLs is never recommended. It is very important to be able to localize and remove the involved ductus for intraductal pathologies, and to perform a more limited surgery in order to obtain good cosmetic results. In this context, minimally invasive methods such as ductoscopy-guided isolated canal excision can be used in a limited number of centers [7]. However, such

minimal invasive methods have been shown to be ineffective in cases with malignancy.

Wire-guided localization (WGL), skin marking, injection of blue dye or carbon, intraoperative ultrasound techniques, and more recently and commonly used radioguided occult lesion localization (ROLL) methods are the methods for localization of NPBLs [8-10]. In many centers, the most preferred method for the localization of such lesions is WGL. However, there are considerably technical difficulties in WGL, such as localization problems in patients with dense breasts. Additionally, the possibility of wire displacement, the patient's discomfort and the presence of complications related to the procedure, such as pneumothorax, are factors that adversely affect the choice of WGL [8, 9, 11]. Another problem in the WGL procedure is that intraductal pathologies are usually close to the nipple and the wire causes patient discomfort. Alternatively, the ROLL technique described in 1997 is frequently used. We are working together with nuclear medicine and radiology and our center is dealing with highly voluminous breast cancer and breast diseases. In this context, we have been using the ROLL technique for the excision of NPBLs for 15 years.

In this study, we aimed to present the results of radioguided surgery for NPBLs in patients with PND.

METHODS

This retrospective study was approved by the Human Ethics Committee of the Mersin University (protocol number: 2020/518). Patients with PND who underwent ROLL and excision for the NPBLs in Mersin University, General Surgery Department between January 1, 2009 and January 1, 2019 were included in this study. Since data of 102 patients with NPBLs and PND were investigated, patients with proven malignancy (n=5), patients with cytology of nipple discharge demonstrating atypical and malignant cells (n=5), patients with insufficient data (n=3), patients with non-operative follow-up (n=22) were excluded from the study. Of 67 surgical patients were included in this study (Figure 1).

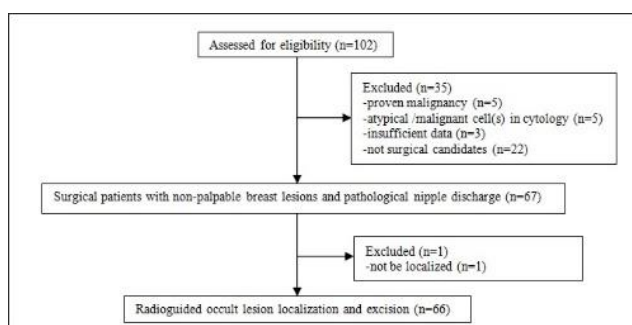


Fig 1. Study flowchart

Table 1: Diagnostic imaging results of the patients, n=66.

BIRADS category	USG (n=66)	MRI (n=66)	MMG (n=47)
0	14	1	9
1	2	2	3
2	4	2	6
3	4	5	7
4	40	45	19
5	2	11	3

(BIRADS: Breast Imaging Reporting and Data System, USG: Ultrasonography, MRI: Magnetic resonance imaging, MMG: Mammography)

Serous, seroanginous or bloody discharge from the single ductus spontaneously and unilaterally were considered as PND. The patients were evaluated in terms of presence of endocrine disease (blood prolactin level and TSH level), drug usage status and presence of comorbidity. All patients with PND were evaluated by breast USG and MRI as diagnostic tools. Radiological breast assessment with MMG was performed in patients over 40 years of age. Radiologic reports of the patients were classified according to the Breast Imaging Reporting and Data System (BIRADS) category (Table 1). Routine cytological examination from nipple discharge was performed. Patients with endocrine disease and iatrogenic causes related to nipple discharge were excluded from the study. As a result of the evaluation, trucut biopsy was performed for patients with suspected malignancy (BIRADS 4 or 5).

Radionuclide-labeled colloid (Tc-99m Nanocolloid, at a maximum dose of 1 mCi) was prepared by Nuclear Medicine Department. The radionuclide was injected intratumorally one hour before the surgical excision. USG-guided radionuclide agent injection was performed. After lesions detected by USG were localized with a linear transducer, the Tc-99m pertechnetate-labeled nanocolloid was injected into the lesion which was verified by USG imaging just after the injection, peritumoral deposition was observed in all patients. Similarly, the lesions detected in MMG were marked by the radiologist using the stereotactic marking tools attached to the mammography device. After the localization of the lesion, colloid substance prepared by a nuclear medicine technician was injected into the lesion.

Breast conserving surgery (BCS) was performed by the same surgeon (AD) under general anesthesia. Before the anesthesia induction the highest activity area on the breast was found with the gamma probe (Europrobe, Eurorad, Sevres, FRANCE), and the skin marking was applied for breast lesion. The point with the most signal was defined as hot spot. The skin and subcutaneous tissue were incised through an incision parallel to the areola on this area. During dissection, the area with the loudest audio signal and numerical signal on the breast lesion was determined using a gamma probe. Counting was confirmed as a hot spot

and this point was marked with suture as anterior surface of the specimen. The excision was completed by removing the marked area based on the audio signal and numerical signal of the gamma probe. It was confirmed that the marked area was completely removed by checking the surgical space with a gamma probe and no numeric count or audible warnings were received. Surgical margins were determined by placing sutures. Two metal clips were also placed at the base of the surgical field and four metal clips were applied for all four dimensions to guide further evaluation. The lesions detected by MMG such as microcalcifications were evaluated with specimen graphy whether all of the lesions were completely removed. The operation was completed after confirming that the entire lesion was removed. Sentinel node and occult lesion localization (SNOLL) was not performed simultaneously in any case. The lesions detected by USG were sent directly to the pathology laboratory. Frozen section was not preferred routinely. All surgical specimens were evaluated in paraffin embedded hematoxylin and eosin staining. Surgical margin status was evaluated according to pathology of the lesion. When the surgical margin was closer than 2 mm, the surgical margin was considered as closer or positive based on the pathology of the lesion. The weight and the volume of the specimen, the diagnosis of the lesion and the distance to the surgical margins were recorded. Patients were evaluated in detail for age, gender, clinical data, radiological data, preoperative marking, surgical results, pathological results, complication rates, local recurrence rates and follow-up period. Data were summarized as mean±standard deviation, numbers (n), percent (%), median (minimum and maximum).

RESULTS

In this study, surgical excision was performed in 67 patients with NPBL and PND, 65 of whom were females. The lesion could not be localized due to the spread of the radionuclide agent to the wide area in one female patient. A total of 66 patients (98.5%) were able to successfully localize the lesion with ROLL, and evaluated in detail (Figure 1).

All women patients were non-pregnant and non-lactating. The median age of the patients that underwent excision with ROLL was 48.1 (38–60) years. All patients had spontaneous and unilateral PND, and 62% of the patients (n=41) had bloody discharge. In the cytological analysis of nipple discharge, patients without atypical cells and malignant cells were included in the study. All patients evaluated with USG (n=66) and MRI (n=66), while 71.2% (n=47) of the patients were evaluated with MMG. BIRADS 4-5 category rates of the patients according to USG, MMG and MRI reports were 63.7% (n=42), 46.8% (n=22) and 84.8% (n=56), respectively (Table 1). Microcalcification was detected in 28.8% (n=19) of the patients.

Lesions were marked with USG in 81.8% patients (n=54), while the rate of marking with MMG was 18.2% (n=12). The mean time duration of preoperative marking was 14 ± 4.3 minutes. The mean operation time was determined as 35 ± 12 minutes. Since the lesion was highly suspicious in terms of malignancy, the surgical margin was confirmed with frozen in 16.7% of the patients (n=11). The removal of the microcalcification sites was confirmed by specimen graphics in 28.8% of the patients (n=19).

The median size of surgical specimen was 14 mm (8–48 mm). While apocrine metaplasia (n=17), fluoride type hyperplasia (n=15), sclerosing adenosis (n=15), fibrocystic change (n=11), ductal carcinoma in situ (DCIS) (n=9, 13.6%), fibroadenoma (n=7), invasive ductal carcinoma (n=4, 6%), atypical ductal hyperplasia (usual type) (n=3), radial scar (n=3), periductal mastitis (n=3), atypical lobular hyperplasia (n=1) were diagnosed in histopathological assessment, more than one pathologic diagnosis was obtained in some patients (Table 2).

Table 2: Final pathologic results (n=88) of the patients (n=66). (More than one pathologic diagnoses were obtained in some cases).

Pathologic results	n=66 (%100)
Invasive ductal carcinoma	4 (6)
Ductal carcinoma in situ (DCIS)	9 (13.6)
Atypical ductal hyperplasia (usual type)	3 (4.5)
Atypical lobular hyperplasia	1(1.5)
Radial scar	3 (4.5)
Periductal mastitis	3 (4.5)
Fluoride type hyperplasia	15 (22.7)
Sclerosing adenosis	15 (22.7)
Apocrine metaplasia	17 (25.8)
Fibrocystic change	11 (16.7)
Fibroadenoma	7 (10.6)

Surgical margin positivity (+) was detected in only one patient diagnosed with DCIS, and reoperation was performed. The surgical margin was found closer than 1 mm in another patient diagnosed with invasive carcinoma, only sentinel lymph node biopsy (SLNB) was performed in a second session without additional surgical procedure for the breast. As a result, two patients had closer than 1 mm surgical margin, one of them required reoperation. Wound dehiscence was observed in three patients (4.5%), healing was completed with secondary intention (n=2) and tertiary closure (n=1). Major complications were not seen in any of the study group patients. Median follow-up period was 62 (12-116) months. During the follow-up period, four patients (6.1%) had mild skin retraction. However, no patient needed additional surgery for recurrence or cosmetic reasons.

DISCUSSION

In this study, NPBLs were successfully localized (98.5%) via ROLL technique in patients with PND. Malignancy was detected in 19.7% of the patients (n=13). Although, two patients had closer than 1 mm surgical margin, lesion continuity at the surgical margin was not reported in any patient. Additionally, surgical margin negativity was achieved in 92.3% (n=12) of patients with malignancy.

Diameters of intraductal lesions causing PND are usually expressed in subcentimeters. For this reason, the lesions may usually present as NPBLs without any findings in physical examination and imaging. The sensitivity (0-51.7%) and specificity (0-96.3%) of MMG, USG, ductography and smear cytology are low [12]. In addition, false negativity and false positivity rates are also high. The most preferred methods for the diagnosis of NPBLs are imaging-guided FNAB, trucut biopsy and VAB [6]. However, the application of these techniques is limited in intraductal pathologies. In such cases, surgical excision of the involved ductus is necessary to exclude the malignancy as a definitive diagnosis, and different localization methods have been introduced for NPBLs [13]. The disadvantages of each method have led to the research of new methods. The standard method used for the localization and excision of such lesions is WGL. However, various complications of WGL have been experienced. New methods have been developed in recent years with the application of nuclear medicine methods in the surgical fields. Marking and resection of NPBLs with the ROLL technique is one of these new methods [8, 14]. ROLL provides fast, simple and accurate localization of the NPBLs [15]. Most of the PND-related lesions are close to the nipple, and WGL can cause discomfort due to the localization. In addition, performing WGL before the day of surgery can be uncomfortable for the patient. There is insufficient data in the literature regarding the marking of patients

with PND and NPBL. In this study, we performed radioguided surgery for our patients. We successfully localized 98.5% of the NPBLs in patients with PND.

Even PND is accompanied by mass, the malignancy rate increases up to 30%. In our study, malignancy was detected in 19.7% of the patients who underwent ROLL due to PND. The absence of tumor at the surgical margin, the reasonable distance of the tumor from the surgical margin and low re-excision rates are the criteria used to evaluate the success of surgery for NPBLs particularly in malignant lesions. There are studies reporting that the rate of reexcision is lower in patients who underwent excision with the ROLL technique [10, 16, 17]. The reexcision rate in our patients is 1.5%. The reexcision rate varies according to the surgical technique. Another way to reduce the need for reexcision is to confirm surgical margin assessment with frozen section. However, it may not be reasonable and possible to use frozen section for surgical margin assessment in all cases, it may be used only in patients with high risk of malignancy. When the reexcision is not performed in the same session, both the reexcision procedure and sentinel lymph node biopsy (SLNB) can be performed together in the next surgery. In the sentinel node and occult lesion localization (SNOLL) technique, removal of the mass from the breast and SLNB can be employed simultaneously [18]. However, since patients diagnosed with cancer were not included in this study, SNOLL technique was not performed for any patient.

One of the important expectations of the patients after breast surgery is to obtain a good cosmetic result. The amount of the removed tissue during BCS is important for better cosmetic results. The lesion should be removed in sufficient volume with oncological principles through an appropriate incision. It is especially necessary for nipple area related surgeries. It is possible to remove less tissue in excisions with ROLL compared to WGL [10, 19]. ROLL technique has been carried out regularly and intensively in our clinic for about fifteen years and is also included in our residency training program. In this context, it has become a technique that the residents can easily perform. Complications associated with WGL technique, such as pneumothorax and migration of the wire, have been reported. No major complications were detected in our study other than seroma and wound separation. ROLL technique can be performed more feasible than WGL, but it is essential to follow some principles. Before anesthesia induction, it is important to control and mark the boundaries of the area with the gamma probe on the breast skin. Although we have experienced spreading of the substance in one patient, we successfully localized the lesion with ROLL technique in 98.5% of the patients. The patient whose localization of the lesion with ROLL failed was excluded from the study. In rare cases of ROLL failure for localization of the mass,

postponing the surgery or other alternative methods should be planned. Projection of the lesion was marked on the skin with USG in that patient, and the lesion was excised. The specimen was evaluated with frozen section to enable safe surgical margins. For surgical success, the surgical margin should be at a certain distance from the tumor. The safety distance of surgical margin is 2 mm for DCIS, and the absence of tumour cells at the surgical margin is considered sufficient for invasive cancer cases [20, 21]. Therefore, less surgery is preferable in invasive carcinomas. In our study, only one patient had surgical margin positivity. Therefore, subsequently re-excision surgery was performed and safe surgical borders were obtained for that patient. In our study, one of the patients diagnosed with invasive carcinoma had close surgical margin. However, due to the lack of ink staining at the surgical margin, no further surgical procedure was performed for the breast. While the rate of patients requiring reexcision and surgical margin positivity was 1.5% (n=1) among all patients (n=66), this rate was 7.1% among patients with malignancy (n=13).

CONCLUSION

The final decision is always obtained by histopathological assessment to distinguish the diagnosis as benign or malignant in breast pathologies. The majority of the lesions causing PND consist of NPBLs and the pathological duct should be removed for definitive diagnosis. In surgical planning, it is important to localize the NPBLs accurately before surgery and remove the lesion with sufficient surgical margin. It is also important to avoid unnecessarily excision of surrounding healthy breast tissue since the lesion may be benign. In our study, it has been shown that ROLL and excision can be easily performed technically for NPBL in patients with PND and provides sufficient safe surgical margins with acceptable cosmetic results.

Acknowledgements

The authors have no conflicts of interest to declare. This research did not receive any specific grant from funding agencies in the public, commercial, or not-for-profit sectors. The results were presented in the 21th National Surgical Congress'18, Turkey as oral presentation.

REFERENCES

1. Fisher CS, Margenthaler JA. A look into the ductoscope: its role in pathologic nipple discharge. *Ann Surg Oncol*. 2011 Oct;18(11): 3187-91.
2. Vaughan A, Crowe JP, Brainard J, Dawson A, Kim J, Dietz JR. Mammary ductoscopy and ductal washings for the

- evaluation of patients with pathologic nipple discharge. *Breast J.* 2009 May-Jun;15(3):254-60.
3. Kamali S, Harman Kamali G, Akan A, Simşek S, Bender O. Use of ductoscopy as an additional diagnostic method and its applications in nipple discharge. *Minerva Chir.* 2014 Apr;69(2):65-73.
 4. de Paula IB, Campos AM. Breast imaging in patients with nipple discharge. *Radiol Bras.* 2017 Nov-Dec;50(6):383-8.
 5. van Gelder L, Bisschops RHC, Menke-Pluymers MBE, Westenend PJ, Plaisier PW. Magnetic resonance imaging in patients with unilateral bloody nipple discharge: useful when conventional diagnostic are negative? *World J Surg.* 2015 Jan;39(1):184-6.
 6. Kibil W, Hodorowicz-Zaniewska D, Popiela TJ, Kulig J. Vacuum-assisted core biopsy in diagnosis and treatment of intraductal papillomas. *Clin Breast Cancer.* 2013 Apr;13(2):129-32.
 7. Moncrief RM, Nayar R, Diaz LK, Staradub VL, Morrow M, Khan SA. A comparison of ductoscopy-guided and conventional surgical excision in women with spontaneous nipple discharge. *Ann Surg.* 2005 Apr;241(4):575-81.
 8. Cheang E, Ha R, Thornton CM, Mango VL. Innovations in image-guided preoperative breast lesion localization. *Br J Radiol.* 2018 May;91(1085):20170740.
 9. Rose A, Collins JP, Neerhut P, Bishop CV, Mann GB. Carbon localisation of impalpable breast lesions. *Breast.* 2003 Aug;12(4):264-9.
 10. Ocal K, Dag A, Turkmenoglu O, Gunay EC, Yucel E, Duce MN. Radioguided occult lesion localization versus wire-guided localization for non-palpable breast lesions: randomized controlled trial. *Clinics (Sao Paulo).* 2011;66(6):1003-7.
 11. Nadeem R, Chagla LS, Harris O, Desmond S, Thind R, Titterell C, Audisio RA. Occult breast lesions: a comparison between radioguided occult lesion localisation (ROLL) vs. wire-guided lumpectomy (WGL). *Breast.* 2005 Aug;14(4):283-9.
 12. Simmons R, Adamovich T, Brennan M, Christos P, Schultz M, Eisen C, Osborne M. Nonsurgical evaluation of pathologic nipple discharge. *Ann Surg Oncol.* 2003 Mar;10(2):113-6.
 13. Alshurbasi N, Cartledge CWJ, Kohlhardt SR, Hadad SM. Predicting Patients Found to Have Malignancy at Nipple Duct Surgery. *Breast Care (Basel)* 2020 Oct;15(5):491-7.
 14. Chan BKY, Wiseberg-Firtell JA, Jois RHS, Jensen K, Audisio RA. Localization techniques for guided surgical excision of non-palpable breast lesions. *Cochrane Database Syst Rev.* 2015 Dec;31(12):CD009206.
 15. Thind CR, Desmond S, Harris O, Nadeem R, Chagla LS, Audisio RA. Radio-guided localization of clinically occult breast lesions (ROLL): A DGH experience. *Clin Radiol.* 2005 Jun;60(6):681-6.
 16. Postma EL, Verkooijen HM, van Esser S, Hobbelink MG, van der Schelling GP, Koelemij R, Witkamp AJ, Contant C, van Diest PJ, Willems SM, Borel Rinkes IH, van den Bosch MA, Mali WP, van Hillegersberg R; ROLL study group. Efficacy of 'radioguided occult lesion localisation' (ROLL) versus 'wire-guided localisation' (WGL) in breast conserving surgery for non-palpable breast cancer: a randomised controlled multicentre trial. *Breast Cancer Res Treat.* 2012 Nov;136(2):469-78.
 17. Landman J, Kulawansa S, Mc Carthy M, Troedson R, Phillips M, Tinning J, Taylor D. Radioguided localisation of impalpable breast lesions using 99m-Technetium macroaggregated albumin: Lessons learnt during introduction of a new technique to guide preoperative localisation. *J Med Radiat Sci.* 2015 Mar;62(1):6-14.
 18. M Ahmed, M Douek. Sentinel node and occult lesion localization (SNOLL): a systematic review. *Breast.* 2013 Dec;22(6):1034-40.
 19. Sajid MS, Paramalli U, Haider Z, Bonomi R. Comparison of radioguided occult lesion localization (ROLL) and wire localization for non-palpable breast cancers: a meta-analysis. *J Surg Oncol* 2012 Jun 15;105(8):852-8.
 20. Solin LJ. Management of Ductal Carcinoma In Situ (DCIS) of the Breast: Present Approaches and Future Directions. *Curr Oncol Rep.* 2019 Mar 5;21(4):33.
 21. Hoekstra S, Stoller D, Raef H. Does gross margin examination reduce re-excision rate in breast conservation for invasive carcinoma? *CALLER Review.* *Eur J Breast Health* 2020 Mar 30;16(3):198-200.