

Primary mesenteric hydatid cyst as the cause of hypofunctioning kidney in [^{99m}Tc]Tc-DMSA scintigraphy: Background photopenia can reveal critical findings

Mohammad Ahmadi, Amin Saber Tanha, Mohammadjavad Bahonar, Ramin Sadeghi

Nuclear Medicine Research Center, Mashhad University of Medical Sciences, Mashhad, Iran

Corresponding Author:

Dr. Ramin Sadeghi

Address: Nuclear Medicine Research Center, Mashhad University of Medical Science, Ahmadabad St, Mashhad, 91766-99199, Iran.

Email: SadeghiR@mums.ac.ir

Running title: Mesentric hydatid cyst on [^{99m}Tc]Tc-DMSA scintigraphy

Article History:

Received: 26 June 2025

Revised: 19 October 2025

Accepted: 22 October 2025

Published Online: 27 December 2025

ABSTRACT

This case report involves a 67-year-old woman with a 20-year history of primary mesenteric hydatid cyst (PMHD) who presented with recent right flank pain. An abdominopelvic CT scan showed severe right-sided hydronephrosis caused by a large mesenteric cyst compressing the ureter. A [^{99m}Tc]Tc-DMSA scan revealed significant function loss in the right kidney, with a barely visible photopenic area in the mid-abdomen corresponding to the cyst. This case underscores the importance of careful evaluation of scintigraphic images, as overlooked photopenic zones can offer valuable insights into underlying conditions like PMHD, which can lead to renal dysfunction.

Keywords: SPECT/CT; Hydronephrosis; Renal failure; Pitfall; Primary mesenteric hydatid disease

INTRODUCTION

Hydatid disease is a parasitic infection caused by *Echinococcus granulosus*, with humans serving as incidental intermediate hosts. The liver is the most affected organ, but the disease can involve various sites, including the spleen, kidneys, pancreas, brain, ovaries, mesentery, vertebrae, and soft tissues of the neck. Intraperitoneal hydatid cysts usually result from a ruptured primary hepatic cyst. Primary mesenteric hydatid cysts are extremely rare. In this report we present a 67-year-old patient with a primary mesenteric hydatid cyst presented with a mid-abdominal photopenic area on [^{99m}Tc]Tc-DMSA scan, leading to renal dysfunction.

CASE PRESENTATION

A 67-year-old woman with a 20-year history of primary mesenteric hydatid cyst (PMHD) and left renal stones presented with new-onset right flank pain that began two weeks prior. An ultrasound examination indicated a small sized right kidney and the presence of a large mesenteric cyst. To further assess the suspected nephrolithiasis, a non-contrast abdominopelvic CT scan was performed (Figure 1A). This revealed decreased parenchymal thickness in the right kidney and severe right hydroureteronephrosis, though no evidence of urinary stones were identified. The CT scan also visualized an enlarged mesenteric hydatid cyst (arrowheads) measuring 115×120 mm which was exerting significant compression on the right ureter. A [^{99m}Tc]Tc-DMSA scan was subsequently conducted (Figure 1B) to evaluate right renal function. The scan demonstrated severe global cortical loss, indicating negligible function in the right kidney. Additionally, the scan revealed a significant photopenic area in the mid-abdomen (arrowheads). Subsequent SPECT/CT imaging (Figure 1C) confirmed that this area corresponded to the large mesenteric hydatid cyst which featured a surrounding rim of calcification. The SPECT/CT findings were consistent with the initial diagnostic CT scan (Figure 1A), confirming compression of the ureter along its course.

DISCUSSION

Most of the time, interpretation of radionuclide imaging primarily focuses on the target organ especially on areas of tracer uptake or accumulation. These areas remain the core of attention even when findings are atypical [1]. Conversely, regions of photopenia in the background are often overlooked or attributed to technical problems in image acquisition [2]. This oversight is particularly common when there is a decrease in uptake rather than a complete absence, which may be attributed to the high accumulation of the tracer in the surrounding tissue and consequently fails to receive adequate attention [3].

[^{99m}Tc]Tc-DMSA scan is commonly employed for the functional and morphological assessment of the renal cortex [4]. In [^{99m}Tc]Tc-DMSA scintigraphy, the primary focus of the reader is typically on the kidneys, often with less attention given to the ureters, bladder morphology, and blood pool activity. However, these additional aspects can provide valuable information, such as diagnosis of a neurogenic bladder or rarely facing the presence of a drooping lily sign aiding in identification of duplicated systems [5]. Although background activity is mostly assessed just to estimate renal function [6], the photopenic zones or altered biodistribution of the tracer may provide golden information, e.g., uncovering a systemic hematologic disorder [7,8]. A significant portion of the imaging field in [^{99m}Tc]Tc-DMSA scintigraphy includes the bowels, colon, mesentery, and peritoneum. While these areas are commonly normal on scans, they may provide important insights into the etiology of decreased renal function, as demonstrated in our case, or unveil additional findings like enterovesical fistula [9] or metastatic lesions [10].

CONCLUSION

The presented case highlights the importance of thorough evaluation of scintigraphic images, particularly in detecting rare conditions like primary mesenteric hydatid disease (PMHD). Careful interpretation of [^{99m}Tc]Tc-DMSA scintigraphy images is crucial, involving gradual adjustment of intensity or color bar settings to detect photopenic zones that may be indicative of underlying pathology and yield more informative insights than areas of increased uptake.

REFERENCES

1. Raman V, Kapse N, Karugaba R, Sharp DG, Stirling S, Hall M, Clarke S. An unusual presentation of abdominal aortic aneurysm on static renal Tc-99m DMSA scintigraphy. *Clin Nucl Med*. 2007 May;32(5):418-20.
2. Hsieh TC, Kao CH, Wang CH, Wu YC, Yen KY, Lin YY, Sun SS. Right subdiaphragmatic crescent photopenia: atypical presentation of Chilaiditi sign on FDG PET. *Clin Nucl Med*. 2009 Feb;34(2):109-10.
3. Ishii S, Shishido F, Miyajima M, Sakuma K, Shigihara T, Kikuchi K, Nakajima M. Causes of photopenic defects in the lower sternum on bone scintigraphy and correlation with multidetector CT. *Clin Nucl Med*. 2011 May;36(5):355-8.
4. Mohamadien NR, Mohamed MS, Mekkaway MA, Ali WA, Diab WA. 99mTc-DMSA renal cortical scanning: a comparison of planar, SPECT, and SPECT/CT imaging for the detection of renal cortical scarring. *Egypt J Radiol Nucl Med*. 2023 Dec 11;54(1):218.
5. Sahakyan K, Spevak MR, Ziessman HA, Gorin MA, Rowe SP. The scintigraphic drooping lily sign. *Clin Nucl Med*. 2018 May;43(5):352-3.
6. Paschali A, Tsiouris S. Increased background activity in DMSA scintigraphy of a nonazotemic patient with β -thalassemia major. *Clin Nucl Med*. 2016 Sep;41(9):714-5.
7. Mercer MK, Parisi MT, Revels JW, Blacklock L, Elojeimy S. Altered biodistribution on 99m Tc-Dimercaptosuccinic acid renal scan. *Clin Nucl Med*. 2023 Apr 1;48(4):e170-2.
8. Firuzyar T, Ghaedian T. The effect of antiseptic on 99mTc-DMSA scans. *Clin Nucl Med*. 2017 Mar;42(3):237-8.
9. Telli T, Kaya G, Işık Z, Tuncel M. Colonic visualization of 99mTc-DMSA due to enterovesical fistula. *Clin Nucl Med*. 2021 Jan;46(1):66-8.
10. Rondogianni P, Koniaris G. Tc-99m DMSA uptake by metastatic colorectal carcinoma. *Clin Nucl Med*. 2004 Aug;29(8):485-7.

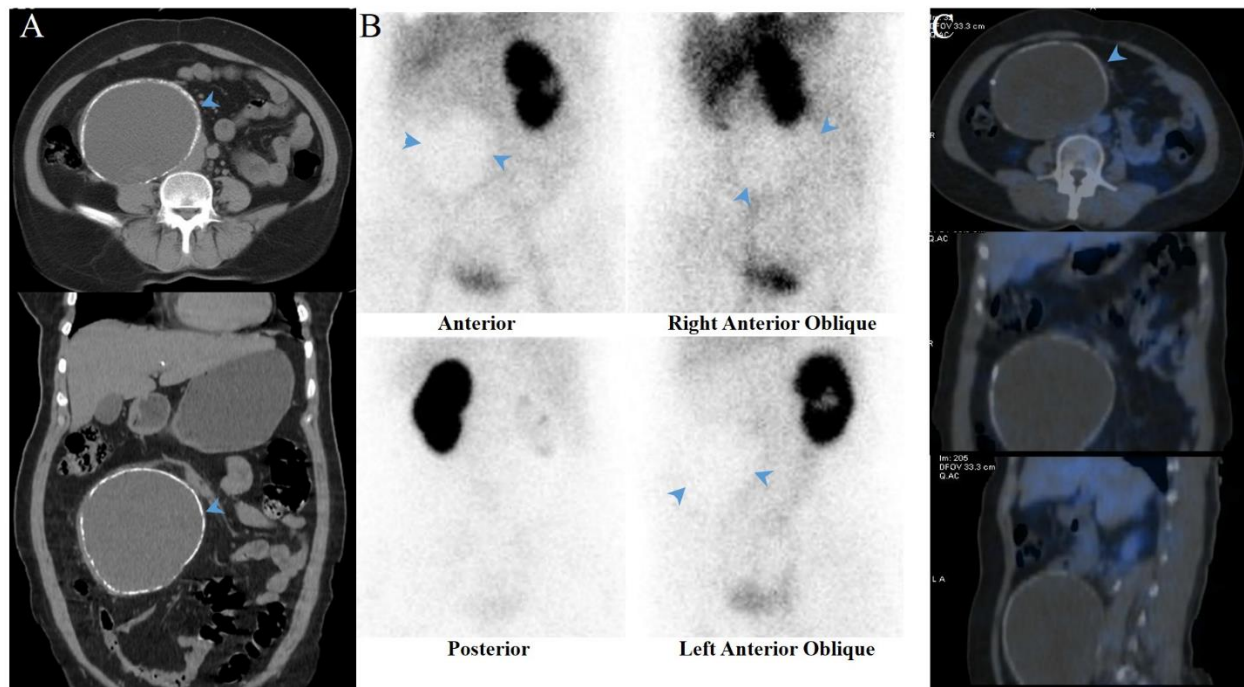


Figure 1. (A) The non-contrast-enhanced CT scan shows an enlarged mesenteric hydatid cyst (arrowheads) exerting compressive effects on the right ureter. (B) The [^{99m}Tc] Tc-DMSA scan reveals a significant photopenic area in the mid-abdomen (arrowheads). Subsequent SPECT/CT imaging (C) confines the photopenic area to the large mesenteric hydatid cyst with a surrounding rim of calcification.