



CASE REPORT

PSMA scintigraphy in metastases of prostate cancer within the genital tract

Faeze Rabani, Mohammad Hadi Samadi, Amin Saber Tanha, Nima Afshari, Atena Aghaee

Nuclear Medicine Research Center, Mashhad University of Medical Science, Mashhad, Iran

ARTICLE INFO

Article History:

Received: 09 September 2025

Revised: 18 November 2025

Accepted: 20 November 2025

Published Online: 27 December 2025

Keyword:

[^{99m}Tc]Tc-PSMA

Prostate cancer

SPECT/CT

PET/CT

ABSTRACT

We present a rare case of vas deferens involvement in high-grade prostate adenocarcinoma, detected by both [⁶⁸Ga]Ga-PSMA PET/CT and [^{99m}Tc]Tc-PSMA SPECT/CT imaging. A 68-year-old male with elevated PSA (Gleason score 4+5) showed locoregional disease involving the prostate, left seminal vesicle, and distal vas deferens on both PET/CT and SPECT/CT scans, with no regional or distant metastasis. This case highlights the value of PSMA imaging in detecting unusual metastatic patterns as well as the clinical utility of [^{99m}Tc]Tc-PSMA SPECT/CT as an accessible alternative to PET/CT. The supplementary file reviews additional reports of PSMA-avid metastases in male genital structures.

*Corresponding Author:

Dr. Atena Aghaee

Address: Nuclear Medicine Research

Center, Mashhad University of Medical

Science, Ahmabad St, Mashhad, 91766-

99199, Iran.

Email: aghaeeat@mums.ac.ir

Use your device to scan and
read the article online



How to cite this article: Rabani F, Samadi MH, Saber Tanha A, Afshari N, Aghaee A. PSMA scintigraphy in metastases of prostate cancer within the genital tract. Iran J Nucl Med. 2026;34(1):95-98.



<https://doi.org/10.22034/irjnm.2025.130300.1708>

INTRODUCTION

Prostate-specific membrane antigen (PSMA)-targeted imaging has significantly improved the detection of prostate cancer metastases, including rare and atypical sites. Vas deferens involvement (VDI) in prostate cancer is uncommon and underreported, with most published reports limited to isolated case studies. VDI is usually identified during restaging for biochemical recurrence, although rare instances have been reported at initial staging [1-4]. Emerging data suggest that VDI may hold independent prognostic value, akin to seminal vesicle invasion, potentially indicating a more aggressive disease phenotype [5]. We present a rare case of VDI detected using both [^{68}Ga]Ga-PSMA PET/CT and [$^{99\text{m}}\text{Tc}$]Tc-PSMA SPECT/CT, highlighting the utility of PSMA-targeted imaging.

CASE PRESENTAION

A 68-year-old man presented with lower urinary tract symptoms (LUTS) and was diagnosed with prostate adenocarcinoma (Gleason score 4+5), with a PSA level of 97.5 ng/mL. He underwent staging

with [^{68}Ga]Ga-PSMA PET/CT performed 60 minutes after intravenous administration of 119.88 MBq (3.24 mCi) of [^{68}Ga]Ga-PSMA, with acquisition from the skull to mid-thigh. After initial androgen deprivation therapy, the patient discontinued treatment and was lost to follow-up. Due to persistent symptoms and a PSA of 88 ng/mL after one year, he underwent restaging with $^{99\text{m}}\text{Tc}$ -PSMA scintigraphy, including whole-body planar imaging and SPECT/CT three hours after intravenous injection of 740 MBq (20 mCi) of [$^{99\text{m}}\text{Tc}$]Tc-PSMA. The initial [^{68}Ga]Ga-PSMA PET/CT demonstrated moderate uptake in the primary prostate tumor, the left seminal vesicle base, and a rounded nodule medial to the seminal vesicle, corresponding to the ampulla of the vas deferens, consistent with locoregional invasion (Figure 1). Restaging with [$^{99\text{m}}\text{Tc}$]Tc-PSMA SPECT/CT one year later revealed similar findings, confirming persistent disease confined to the prostate, left seminal vesicle, and vas deferens, with no evidence of nodal, skeletal, or visceral metastases (Figure 2). Subsequent treatment planning for the patient involved radiotherapy.

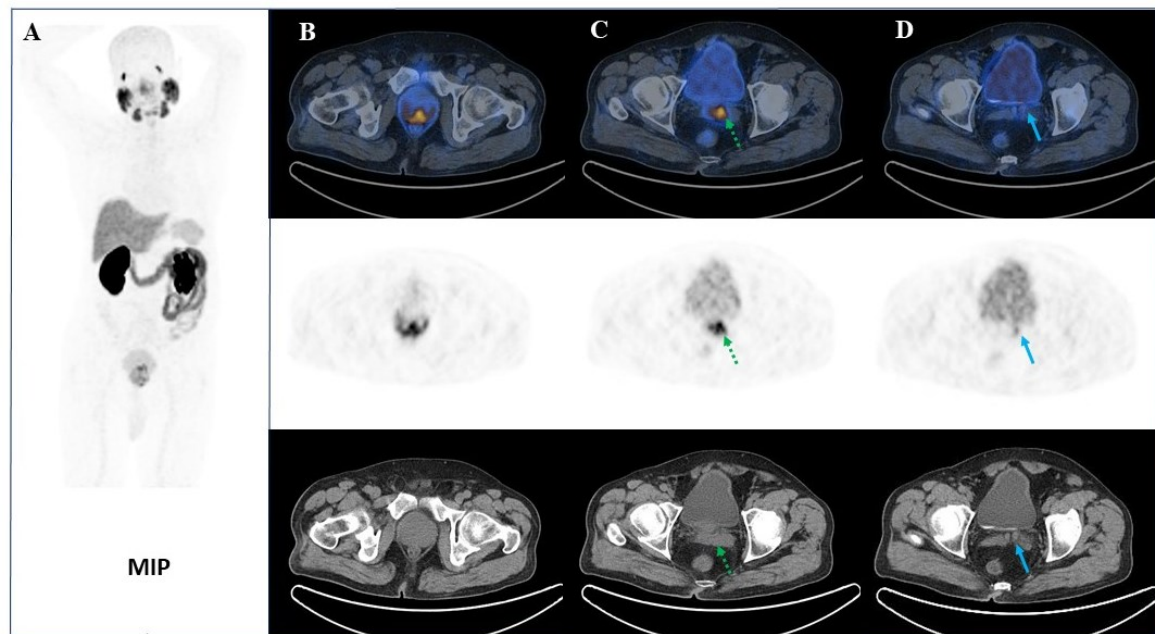


Figure 1. [^{68}Ga]Ga-PSMA PET/CT images showing uptake in the primary prostate tumor (B), left seminal vesicle base (C, dotted arrows), and ampulla of the vas deferens (D, arrows)

DISCUSSION

Assessing VDI is challenging due to overlapping activity from adjacent structures. However, in this case, the focal lesion is likely true infiltration, given its consistent appearance on both imaging modalities performed in separate sessions.

Additionally, the lesion's shape and anatomical location closely correspond to previously reported imaging features of vas deferens involvement, supporting its interpretation as true infiltration rather than an artifact [6-8]. Current evidence, although limited, indicates that vas deferens

involvement (VDI) is associated with poorer prognosis, warranting thorough pathological evaluation, and may lead to decisions regarding adjuvant therapy in selected patients [9, 10]. While there is no definitive evidence that VDI alters initial surgical planning, its presence can influence radiotherapy and systemic therapy strategies. Specifically, VDI may justify expansion of target volumes or focused treatment of vas-deferens-based recurrences and help identify patients who may benefit from closer surveillance or early initiation of systemic therapy when detected as a positive margin on pathology or on post-treatment imaging [11-13]. Case reports have demonstrated that both surgical excision and targeted radiotherapy for vas deferens recurrence can achieve durable local control, emphasizing the clinical relevance of recognizing and appropriately managing VDI [14, 15]. The concordance between PET/CT and SPECT/CT highlights the reliability of these modalities, while the ability of ^{99m}Tc -PSMA SPECT/CT to replicate PET/CT findings underscores its role as a cost-effective and accessible

alternative, particularly in regions with limited PET/CT availability. Comparative studies indicate that ^{99m}Tc -PSMA SPECT/CT demonstrates robust diagnostic performance for many clinically relevant lesions, though sensitivity may be reduced at very low PSA levels. In resource-limited settings, ^{99m}Tc -PSMA SPECT/CT offers a practical and scalable imaging strategy to guide diagnosis and treatment, with PET/CT remaining the preferred modality where available [16-19].

Our literature review showed that PSMA-avid metastases involving male genital structures—including the vas deferens, testes, epididymis, penis, scrotal sac, vesicourethral junction, and perineum—are predominantly reported in patients between 45 and 88 years of age (Supplementary file). Most cases occurred during biochemical recurrence, in individuals with high Gleason scores and moderate-to-intense PSMA expression (scores 2&3). These findings emphasize that atypical genitourinary spread often coincides with advanced or biologically aggressive prostate cancer.

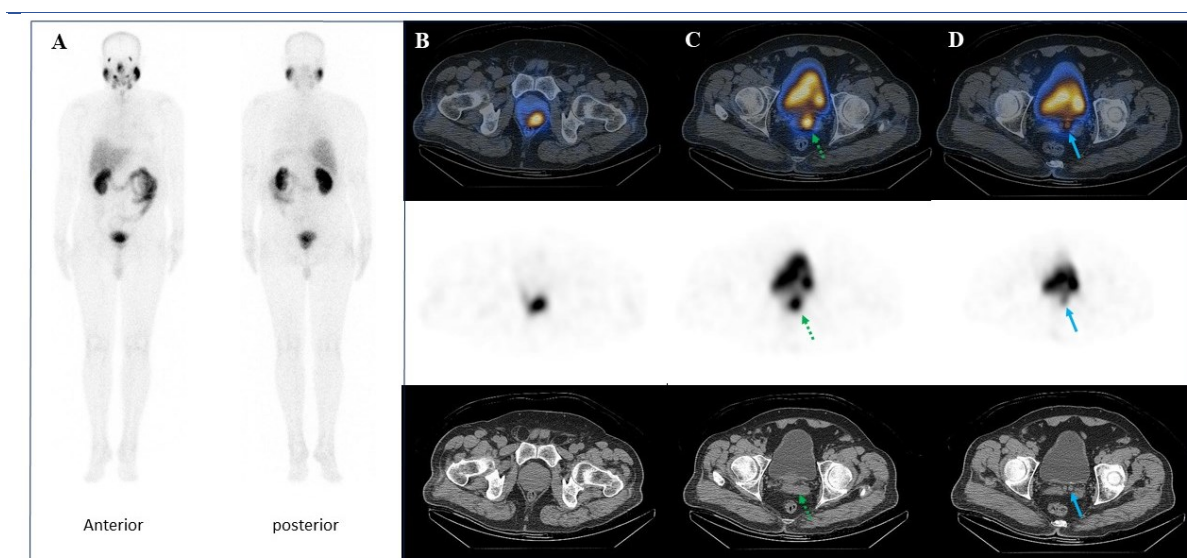


Figure 2. [^{99m}Tc]Tc-PSMA SPECT/CT images demonstrating findings consistent with PET/CT, including uptake in the primary prostate tumor (B), left seminal vesicle base (C, dotted arrows), and vas deferens ampulla (D, arrows)

CONCLUSION

Identification of vas deferens involvement (VDI) in prostate cancer has significant implications for prognosis, treatment planning, and surveillance. Advanced PSMA-based imaging, combined with thorough pathological assessment, enables more accurate risk stratification and personalized management, especially in high-risk patients.

REFERENCES

1. Valle LGM, Rahal A Jr, Falsarella PM, de Andrade JR, Smaletz O, Osawa A, Garcia RG. Prostate cancer recurrence in vas deferens - fusion image guide as an important tool in diagnosis. *Int Braz J Urol.* 2018 Jan-Feb;44(1):192-5.
2. Thaweerat W, Dankulchai P, Jitpraphai S, Khiewvan B. Isolated spermatic cord metastasis of prostate cancer after radiotherapy detected with 18F-PSMA PET/CT: a case report and literature review. *Int Cancer Conf J.* 2024 Jul 10;13(4):377-81.

3. Priftakis D, Afaq A, Bomanji J. Imaging of prostate cancer recurrence in the vas deferens with 68Ga-PSMA PET/CT. *Clin Nucl Med*. 2020 Jan;45(1):49-51.
4. Raeisi N, Saber Tanha A, Sadeghi R, Dorri Giv M, Dabbagh Kakhki VR. Prostate adenocarcinoma recurrence in the vas deferens unveiled by 99m Tc-PSMA SPECT/CT imaging. *Clin Nucl Med*. 2025 Dec 1;50(12):e700-1.
5. Yigit N, Karslioglu Y, Kurt B. Vas deferens invasion: A neglected issue in the sampling of radical prostatectomy materials. *Can Urol Assoc J*. 2014 Jul;8(7-8):E554-7.
6. Yin Y, Paller CJ, Pomper MG, Pienta KJ, Gorin MA, Rowe SP. Vas deferens infiltration by prostate cancer on prostate-specific membrane antigen-targeted 18F-DCFPyL positron emission tomography/computed tomography: a unique visual pattern. *World J Nucl Med*. 2019 Dec 18;18(4):424-7.
7. Erol Fenercioğlu Ö, Alçın G, Arslan E, Çermik TF, Ergül N. Vas deferens and inguinal canal metastasis of prostate cancer revealed by 68 Ga-prostate-specific membrane antigen PET/CT. *Clin Nucl Med*. 2022 Oct 1;47(10):e635-6.
8. Kim B, Kawashima A, Ryu JA, Takahashi N, Hartman RP, King BF Jr. Imaging of the seminal vesicle and vas deferens. *Radiographics*. 2009 Jul-Aug;29(4):1105-21.
9. Jang WS, Yoon CY, Kim KH, Kang YJ, Shin SJ, Cho NH, Lee JY, Cho KS, Ham WS, Rha KH, Hong SJ, Choi YD. Prognostic significance of vas deferens invasion after radical prostatectomy in patients with pathological stage T3b prostate cancer. *Ann Surg Oncol*. 2017 Apr;24(4):1143-9.
10. Saar M, Kamradt J, Sauer C, Stöckle M, Grobholz R. Margin status of the vas deferens in radical prostatectomy specimens: relevant or waste of time? *Histopathology*. 2014 Jul;65(1):45-50.
11. Bates AS, Sharma AD, Camilleri P, Browning L, Verrill C, Hamdy FC. 'Case of the month' from the department of urology, Oxford university hospitals, Oxford, UK: stereotactic radiotherapy to the vas deferens for PSMA-PET CT detected local recurrence 10 years after radical prostatectomy. *BJU Int*. 2024 Sep;134(3):377-9.
12. Gözen AS, Koudonas A, Senel S, Colecchia M, Rassweiler J. Preperitoneal vas deferens infiltration in high-risk prostate cancer. *BJU Int*. 2023 Sep 17;5(1):159-65.
13. Lim Joon D, Chao M, Piccolo A, Schneider M, Anderson N, Handley M, Benci M, Ong WL, Daly K, Morrell R, Wan K, Lawrentschuk N, Foroudi F, Jenkins T, Angus D, Wada M, Sengupta S, Khoo V. Proximal seminal vesicle displacement and margins for prostate cancer radiotherapy. *J Med Radiat Sci*. 2021 Sep;68(3):289-97.
14. Takamori H, Kamba T, Sumiyoshi S, Tsuzuki T, Kashima S, Yoshino T, Sano T, Goto T, Sawada A, Akamatsu S, Kobayashi T, Yamasaki T, Mizowaki T, Ogawa O, Inoue T. Solitary recurrence of prostate cancer surrounded by seminal vesicle/vas deferens-like epithelium. *IJU Case Rep*. 2020 Jul 30;3(5):171-3.
15. Vitale C, Nicosia L, Pastorello E, Rigo M, Doraku J, Salgarello M, Alongi F. Vas deferens metastasis from prostate adenocarcinoma treated with daily-adaptive MR-guided SBRT on 1.5T MR-linac. *Rep Pract Oncol Radiother*. 2022 May 19;27(2):371-4.
16. Wang Q, Ketteler S, Bagheri S, Ebrahimifard A, Luster M, Librizzi D, Yousefi BH. Diagnostic efficacy of [99mTc]Tc-PSMA SPECT/CT for prostate cancer: a meta-analysis. *BMC Cancer*. 2024 Aug 8;24(1):982.
17. Albalooshi B, Al Sharhan M, Bagheri F, Miyanath S, Ray B, Muhasin M, Zakavi SR. Direct comparison of 99mTc-PSMA SPECT/CT and 68Ga-PSMA PET/CT in patients with prostate cancer. *Asia Ocean J Nucl Med Biol*. 2020 Winter;8(1):1-7.
18. Fallahi B, Khademi N, Karamzade-Ziarati N, Fard-Esfahani A, Emami-Ardekani A, Farzanefar S, Eftekhari M, Beiki D. 99mTc-PSMA SPECT/CT versus 68Ga-PSMA PET/CT in the evaluation of metastatic prostate cancer. *Clin Nucl Med*. 2021 Feb 1;46(2):e68-e74.
19. Kolade OU, Brink A, Ayeni AO, More S, Holness J. Optimizing PSMA scintigraphy for resource limited settings - a retrospective comparative study. *Cancer Imaging*. 2024 Apr 1;24(1):46.