

Radionuclide shuntography in a hydrocephalic patient

Armaghan Fard Esfahani MD, Mohammad Taghavi MD,
Mohammad Eftekhari MD, Mohsen Saghari MD

Research Institute for Nuclear Medicine, Tehran University of Medical Sciences

ABSTRACT

Radionuclide shuntography is a safe and simple method to determine shunt patency and analyze changes in CSF (Cerebro-Spinal-Fluid) flow. We present a case of complicated CSF shunt, in which radioisotopic scan correctly identified disconnection of the shunt tubing system localizing the site of extravasation accurately. The findings were confirmed by surgery performed for correction of the shunt system.

Once the hydrocephalic patient has been shunted, regular examinations are required to assure shunt patency. Although routine surveillance is usually undertaken through repeat CT scanning, these studies only demonstrate the increasing ventricular size associated with a malfunctioning shunt and not why it is not functioning properly. Radioisotopic shuntography is the method of choice for this evaluation (1).

Case Report

A 5 -years-old child with ventriculo-peritoneal shunt installed at the age of 8 months, was admitted because of headache and vomiting. In physical examination both fontanelles were closed and the patient was paraplegic. To evaluate shunt patency, a radioisotopic shuntography was ordered. The patient was injected with 1 mCi of Tc-99m Pertechnetate into the reservoir and imaging was performed every

5min up to 1hr on an ADAC (genesis) gamma camera with a LEAP collimator. After a few minutes some portion of the administered activity extravasated and accumulated at the right side of the skull base. It's intensity increased with time (fig 1 & 2). This finding indicated disconnection of the shunt at this level. The patient underwent surgery and it was confirmed that the shunt tube had been disconnected where it passed subcutaneously posteroinferior to the right ear about the skull base consistent with the scan finding, and the distal part of the shunt had been fallen in the peritoneal cavity (fig3&4). Surgical correction was performed.

Discussion

The widespread use of diversionary shunts in treatment of various forms of hydrocephalus has created the need for simple method to analyze changes in CSF flow, to determine shunt patency and to identify the cause of complications.

Pressure removal from ventricles, begun since early 20th century, has had a significant progress with developing of one-way flow valves and silicone tubes (2). There is variety of shunts including ventriculo-peritoneal, ventriculo-jugular, ventriculo-atrial and lumbo-peritoneal shunts. Common complications of CSF shunt surgery are ventricular blockage, subdural hematoma, craniosynostosis, chronic headache, slit ventricle syndrome and less commonly infection and thromboembolism. Disconnection of the shunt catheter or distal catheter knotting and kinking are more common in children. Clarification of shunt dysfunction may require the evaluation of CSF dynamics by radionuclide shuntography. This method especially if the administered radionuclide is Tc-99m provides diagnostic information that is minimally invasive, but accurate in determination of shunt patency. After injection of radiopharmaceutical under strictly aseptic conditions into the shunt

reservoir, serial images are obtained to monitor the ventricles and flow of the CSF into the distal shunt catheter. The distal shunt tubing is visualized as a linear band of radioactivity. In ventriculo-peritoneal shunts, there should be free flow of radioactivity at the distal tip of functioning shunt. Signs of inadequate function include: a reservoir that requires pumping to initiate flow, lack of free intraperitoneal flow, extravasation of injected radiopharmaceutical or pooling at the reservoir site that suggests a break in the shunt tubing secondary to mechanical stress or discontinuity of connections.(3). Shunt obstruction is the most common complication of diversionary shunts, responsible for 56% of primary shunt insufficiency cases (4) and is mostly seen in ventricular catheter. Distal catheter is involved less commonly. CSF pseudocyst is seen in patients with previous shunt infection or multiple previous surgical manipulations (5).

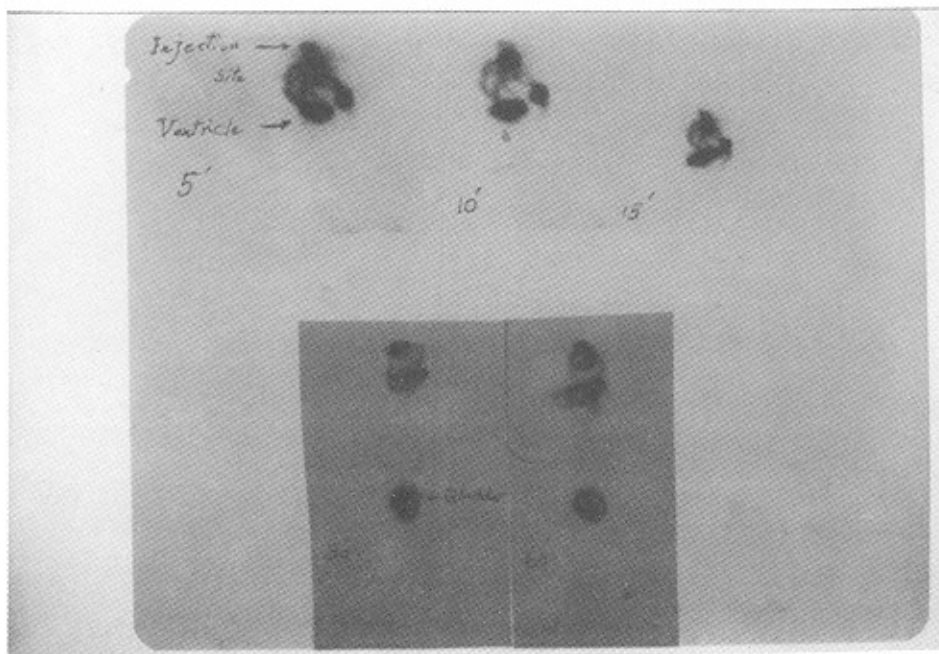
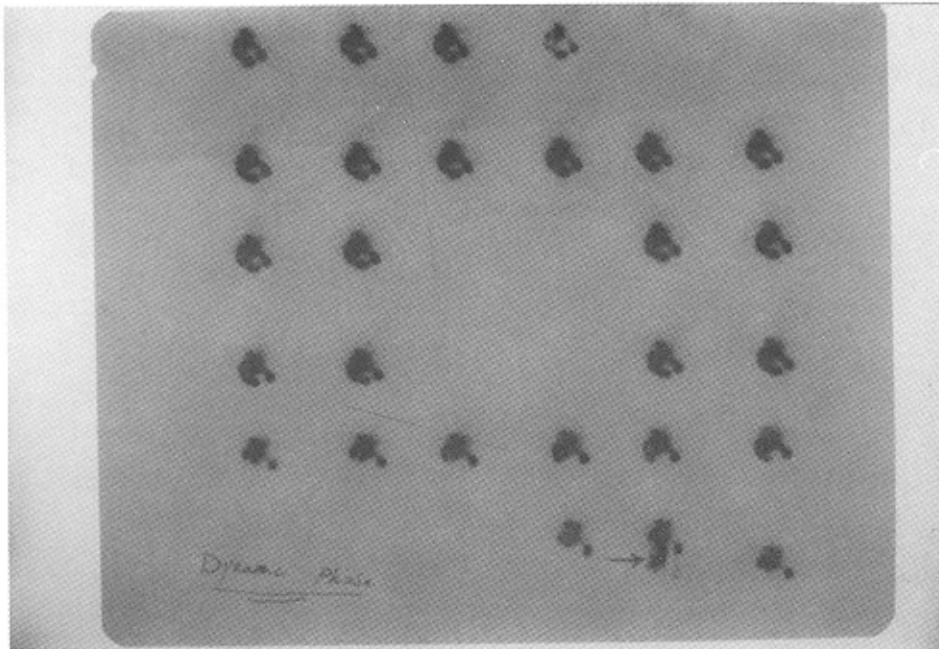


Fig 1 & 2 : Extravasation of radiotracer from tubing system and pooling at the right side of skull base (arrow) ,

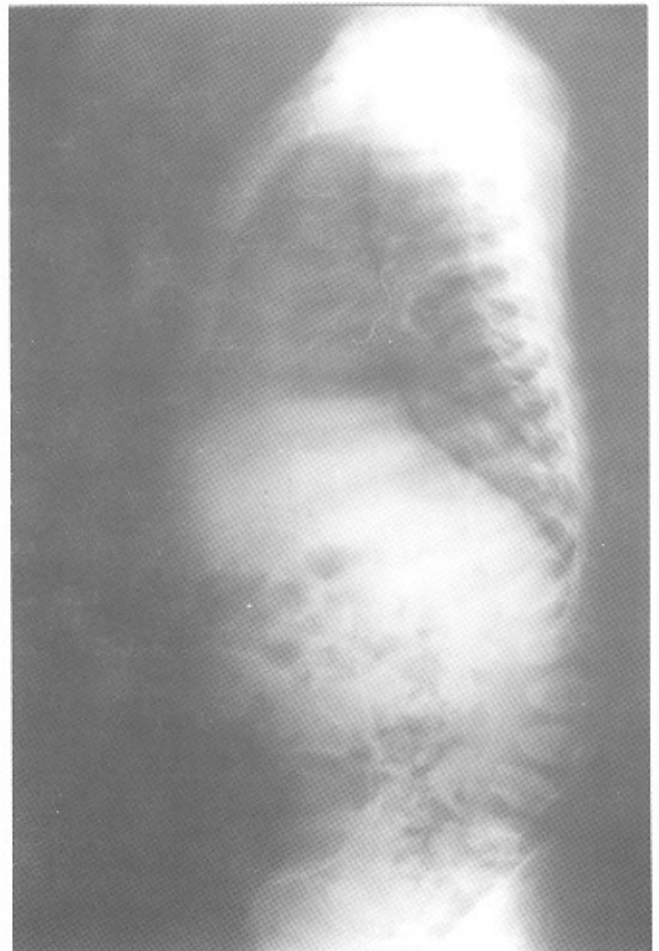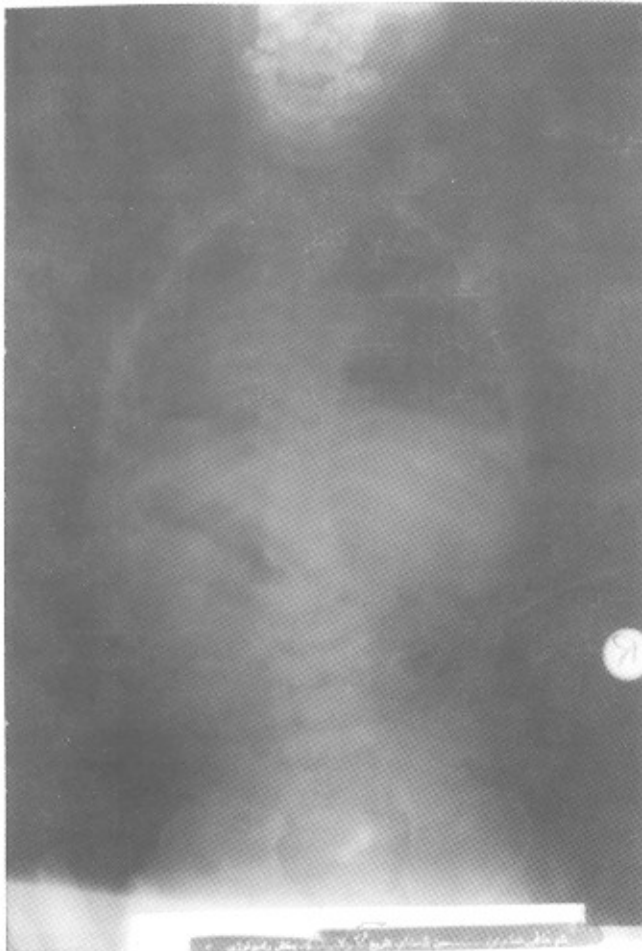


Fig 3 & 4 : Distal part of shunt system is fallen in the peritoneal cavity.

References

- 1 - Harbert JC, Eckelman WC, Neumann RD; In: Nuclear Medicine Diagnosis and Therapy. USA, Thieme Medical Publishers. 1996; 392
- 2 - Kanev PM, Park TS; The treatment of hydrocephalus. Neurosurg Clin North Am 1993; 4:611-619
- 3 - Sandler MP, Coleman RE, Wackers FJ, Patton JA, Gottschalk A, Hoffer PB; In: Diagnostic Nuclear Medicine, USA, W&W. 1996; 1170-1172
- 4 - Sainte Rose C, Hoffman HJ, Hirsch JF; Shunt failure, Concepts Pediatric Neurosurg 1989; 9:7
- 5 - HannYS, Engelhard H, Mclone DG; Abdominal CSF psuedocyst; Clinical feature and surgical management, Pediatric NeuroSci 1985; 12:75-79