

The Pattern of Brain Perfusion SPECT in Non-medicated Schizophrenic Patients

Farzaneh Pooyafard, MD¹; Babak Fallahi, MD²; Seyed Mohammad Assadi, MD¹;
Homayoun Amini, MD¹; Davood Beiki, PhD^{2,3}; Armaghan Fard-Esfahani, MD²;
Fatemeh Rahiminezhad, MD¹; Nazila Shahmansouri, MD¹; Mohammad Reza Mohammadi MD¹

¹Psychiatry and Psychology Research Center, Roozbeh Hospital, ²Research Institute for Nuclear Medicine,
³Department of Nuclear Pharmacy, Faculty of Pharmacy, Tehran University of Medical Sciences,
Tehran, Iran

(Received 10 March 2008, Revised 22 March 2008, Accepted 25 March 2008)

ABSTRACT

Introduction: Studies with single photon emission computed tomography (SPECT) have revealed inconsistent changes of regional cerebral blood flow (rCBF) in schizophrenia. Some studies investigated the rCBF and its relationship with psychopathology, positive and negative symptoms in treated patients. However, there is a little information about the pattern of rCBF in recently untreated or never treated schizophrenic patients. The aim of this study was to evaluate the pattern of rCBF of the drug-naïve or drug free schizophrenic patients.

Methods: Thirty-three patients with schizophrenia participated in the study. For each subject, the regional brain perfusion was evaluated with SPECT and the clinical state was assessed according to PANSS and CGI in a medication-free state. Also a group of 12 cases without any history of neurological or psychological disorder was enrolled as a control group for comparing of the SPECT data. Regional perfusion indices (RPI) were defined as mean count per pixel in each of 25 brain regions normalized to the mean count per pixel of the whole brain. The RPI patterns were compared in control and patient subjects.

Results: In comparison with control subjects, the RPI of the anterior cingulate and inferior parts of the prefrontal and temporal cortices of the schizophrenic patients are significantly higher while the RPI of the occipital and parietal regions are unilaterally lower. Different schizophrenic patients showed hyperperfusion as well as normal or hypoperfusion in different regions of the brain cortex. However, hyperperfusion rather than hypoperfusion mainly is seen in the inferior prefrontal and temporal regions, while hypoperfusion patterns are more prominent in the cerebellar, occipital, parietal and dorsolateral prefrontal cortices.

Conclusion: Different patterns of brain perfusion are seen in drug-free or drug-naïve patients with schizophrenia. Hyperperfusion in the frontal and temporal regions and hypoperfusion in the cerebellar, parietal and dorsolateral prefrontal cortices are the most predominant abnormal patterns in these cases.

Key words: Perfusion, Brain, Schizophrenia, SPECT.

Iran J Nucl Med 2008; 16(1): 43-51

Corresponding author: Dr Babak Fallahi, Research Institute for Nuclear Medicine, Shariati Hospital, North Kargar Ave., Tehran, Iran E-mail: bfallahi@sina.tums.ac.ir

INTRODUCTION

Recent studies of cerebral perfusion or metabolism with single photon emission computed tomography (SPECT) or positron emission tomography (PET) in schizophrenic patients have revealed inconsistent findings of regional cerebral blood flow (rCBF) and/or glucose metabolism. Some studies have described an impairment of frontal rCBF or metabolism mainly in medicated patients with chronic disease (1-7), while others revealed hyperfrontality in acute unmedicated cases. (8-13). In addition some studies exhibited increased or decreased metabolism or perfusion in the temporal, parietal and even basal ganglia (7,8,13-16). In one study that may be a major one in this subject, most of the drug-naïve patients showed hyperperfusion in different brain regions (17). In one study a lateralization pattern in the form of increased perfusion in the left hemisphere was found in young schizophrenic patients before neuroleptic therapy (8). In addition some study groups have concluded that the state of perfusion is mostly dependent on the state of neuroleptic drug consumption in schizophrenic patients (18, 19). On the other hand, in some studies, a correlation has been found between the symptoms and perfusion state in different brain regions of schizophrenic patients (8, 17). A major drawback in most of these studies is small sample size of patients studied in drug-free or drug naïve states. Also studies on rCBF in schizophrenic patients have rarely concerned a control group for comparison. The aim of this study was to evaluate the prevailing perfusion pattern in recently untreated or never treated schizophrenia patients in comparison with control subjects.

METHODS

Patients

This study was performed using a protocol approved by the local ethics committee of Tehran University of Medical Sciences. Actively psychotic schizophrenic patients meeting the criteria for the diagnostic and statistical manual of mental disorders (DSM-IV) included if they were neuroleptic-naïve or neuroleptic-free for at least 4 weeks and had no anatomical abnormality on brain computed tomography scan. Patients with schizophreniform, schizoaffective, bipolar mood and any other disorders in axis II of DSMIV, substance abuse and obvious neurologic disorders were excluded from the study. In addition severely elevated hepatic enzymes, severe thyroid

dysfunction, pregnancy and lactation, and consumption of the drugs interfering with serotonin receptors (such as cyproheptadine or metoclopramide) were incorporated in the exclusion criteria.

Thirty-three patients, 23 (69.7%) male and 10 (30.3%) female; mean age 30.85 ± 6.36 (22-46) years were enrolled. All patients were right handed. The baseline clinical characteristics of the studied patients were defined by at least two experienced psychiatrists and summarized in Table 1. The initial examinations and history taking were performed on admission. Clinical assessment was done using the positive and negative syndrome scale of schizophrenia (PANSS) and clinical global impression (CGI; Guy 1976), (Table 1). The PANSS and CGI were obtained during a formalized, semi-structured interview. There are 33 items (16 global psychopathological, 7 positive, 7 negative and 3 aggression risk symptoms) on a seven-point scale from 1 (normal) to 7 (extremely abnormal). The CGI, total PANSS, Summative positive (Sum P), Summative negative (Sum N) and summative psychopathological (Sum G) symptoms scores were recorded.

The patients referred to the research institute for nuclear medicine for SPECT imaging the day after clinical assessment. To prevent any possible bias, the SPECT images were interpreted with blindness to the results of the clinical examination.

Control Subjects

Control cases were comprised of 12 right handed cases, 4 women (33.3%) and 8 men (66.7%) who were referred after a minor accidental trauma without neurological and psychiatric abnormalities and without morphological alterations of the brain on CT images. The mean \pm standard deviation of the age in control group (31.25 ± 8.54) showed no significant difference with the group of schizophrenic patients, ($p=0.865$). Also no difference was noted between groups based on gender, education, marriage status and history of smoking, so the control group was demographically comparable to the patients group.

Imaging Protocol

All of the control subjects and patients underwent cannulation of an arm vein and were allowed to rest for at least 10 minutes before injection of 740 MBq Tc-99m ethylcysteinate dimer (Tc-99m ECD) as a radiotracer prepared according to the manufacturer's instructions. During the injection, subjects were lying comfortably in a semi-darkened and silent room with their eyes open and ears unplugged. The radiotracer was injected in a resting supine position.

Table 1: Demographic and clinical data of the studied groups

	Schizophrenia patients		Control cases		Difference (P value)
Gender	23 (69.7%) M	10 (30.3%) F	8 (66.7%) M	4 (33.3%) F	0.846 NS
Age (years) mean±SD (range)	30.85 ± 6.36 (22-46)		31.25 ± 8.54 (18-44)		-
Duration of disease (years) mean±SD (range)	7.21 ± 4.22 (1-17)		-		-
State of neuroleptic therapy	8 (24.2%) NN	25 (75.8%) NF	-		-
Drug free interval* (months) mean±SD (range)	4.94 ± 5.71 (1-24)		-		-
Smoking	17 (51.5%) Yes	16(48.5%) No	6 (50%) Yes	6 (50%) No	0.937 NS
Marriage	4 (12.1%) married 27 (81.8%) single 2 (6.1%) divorced		-		-
Type of schizophrenia	20 Paranoid 5 Disorganized 3 Undifferentiated 5 Residual		-		-
Education	1 Non-educated 7 primitive 12 Intermediate 13 Well-educated		0 Non-educated 2 primitive 4 Intermediate 6 Well-educated		0.465 NS
CGI Median (range)	6 (4-7)		-		-
Total PANSS Median (range)	92 (63-122)		-		-
General psychopathology Median (range)	46 (31-67)		-		-
Positive scale Median (range)	25 (9-37)		-		-
Negative scale Median (range)	24 (10-44)		-		-

M: Male, F: Female, NS: Non-significant, SD: Standard deviation, NN: Neuroleptic naïve, NF : Neuroleptic free,
* Calculated only for neuroleptic-free patients

All cases were scanned with a dual-head SPECT (ADAC, SOLUS, Milpitas, CA) gamma camera equipped with a low-energy general purpose collimator, 20-25 minutes after injection using a special head-holder for fixation in a complete symmetrical position with transverse slices parallel to

the orbitomeatal (OM) plane. A 20% window centered at a 140 keV photopeak for Tc-99m was used. The image acquisition was performed in a 360° step and shot rotation (180° rotation for each head) with 30 seconds per azimuth view for a total 64 views in a 128 ×128 matrix with a zoom of 1.84. Restless patients

received up to 15 mg diazepam intravenously 10 minutes after the radiotracer injection.

SPECT Data Reconstruction and Analysis

For each control or patient case, all steps for image reconstruction and analysis were carried out by two observers (one of them was an experienced nuclear physician and the other was a well-trained technologist), each of them were blinded to the results of the analysis obtained by the other one. Reconstruction was performed by filtered back projection using a Gaussian filter. Attenuation correction was performed. The images were reoriented to obtain transaxial slices parallel to the OM plane. Sixteen transverse slices from the lower part of the cerebellum to the vertex were used to make 4 composite slices; each of them was 4 pixels thick. The most basal and the most dorsal slices were not selected to minimize partial volume effect. On the composite transaxial slices, brain contours were drawn using an automated technique to describe the limits of the brain and to calculate the average count per pixel of the whole brain cortex. On each composite slice the circular regions of interest (ROI) were drawn (42 ROIs), each 12 pixels in size (4 pixels in diameter), with a semiautomatic ROI drawing technique in the circular regional brain analysis software (Euro Custom Menue/Pegasys/ADAC). The ROIs in this size were larger than about $2.5 \times$ spatial resolution (FWHM) of our gamma camera to avoid partial volume effect and to allow an optimal quantification.

Using an anatomical guideline, the brain was divided into 12 identical regions on each reciprocal side and one region in the anterior cingulate cortex. Each of the anatomical regions was attributed to a number of summed ROIs on each side. Semiquantitative regional perfusion index (RPI) for each of the 25 anatomical regions of the whole brain cortex was calculated automatically by normalization of the mean count per pixel in the region with mean count per pixel of the whole brain.

For all patients and control group (45 cases), all 42 ROIs were redrawn by the same nuclear physician and the intra-observer variability determined for every single ROI was significantly lower than one standard deviation (SD) of the ROI values ($p < 0.0001$).

The interobserver variability was also lower than 1 SD ($p < 0.047$).

Statistical Analysis

The *Shapiro-Wilks test*, *Lilliefors test* and *Kolmogorov-Smirnov Z test* were used to determine whether the observed 25 regional perfusion indices of 12 control subjects have come from a normal

distribution. These tests showed that despite the small sample size of control subjects, the perfusion of all brain regions except for right and left ventrolateral prefrontal cortex ($p = 0.044$, $p = 0.039$ with K-S-Z) are fitted to a normal distribution in the control group. To estimate the exact significance of difference from a normal distribution, *Monte Carlo approximation* with 99% confidence level was also used and the goodness-of-fit to normal distribution was verified with lower bound of p values. So a 95% confidence interval of perfusion values in control group were defined as normal range of RPI in each brain region and accordingly the state of perfusion in each brain region of the schizophrenia patients was categorized as hypoperfusion- and hyperperfusion state.

A *multivariate analysis of variances (MANOVA)* was performed to compare SPECT data of the patients and control group. The F is corrected with *Levene's test* for equality of error variances across groups. This test was based on the linearly independent pairwise comparisons among the estimated marginal means and the mean difference was significant at the 0.05 level of p after adjustment for multiple comparisons with *Bonferroni*.

RESULTS

The demographic and clinical data of the patients are summarized in the Table 1. The RPIs for many brain regions are higher than that of control group (Table 2). The frequencies of each perfusion state in the different brain regions are detailed in Table 3. Although in most cases of schizophrenia, normal perfusion state is seen in the cerebellum, ventromedial prefrontal cortex (VMPC), ventrolateral prefrontal cortex (VLPC), dorsolateral prefrontal cortex (DLPC), occipital lobe and anterior cingulate cortex (ACC), hypoperfusion as well as hyperperfusion may be seen in these regions. Hyperperfusion is more frequent in the prefrontal and inferior temporal cortex (ITC). Also in most cases, hypoperfusion is noted in the parietal lobes. The orbital prefrontal cortex (OPC) shows most likely normal state or hyperperfusion. A lateralization pattern in the form of left sided hypoperfusion is noted mainly in the medial temporal cortex.

DISCUSSION

Comparing with many studies that have evaluated the rCBF of schizophrenic patients, this study was clearly designed with a relatively greater sample size of drug-free or drug-naïve cases and benefited from a better evaluation of the brain perfusion states in comparison with control subjects.

Table 2: Comparison of regional perfusion indices (mean count per pixel of each brain region normalized to the whole brain average count per pixel) between control group and schizophrenia patients.

Brain Region	Baseline schizophrenia 33 cases		Control 12 cases		Comparison			
					F*		P*	
	Right	Left	Right	Left	Right	Left	Right	Left
Cerebellum	4.159 ± .6911	3.963 ± .6891	4.059±.5495	3.911±.5071	.18	.05	.67	.82
VMPC	1.261 ± .1494	1.227 ± .1569	.983±.1764	1.006±.1302	23.08	17.01	.001*	.001*
VLPC	1.131 ± .1874	1.081 ± .1686	.962±.1032	.979±.0781	8.25	3.85	.007*	.059
DLPC	1.311 ± .1611	1.242 ± .1384	1.230±.1031	1.179±.0739	2.43	2.12	.12	.15
Parietal	1.249 ± .1243	1.138 ± .1399	1.293±.0264	1.243±.0160	1.47	6.55	.23	.016*
Occipital	1.393 ± .1246	1.307±.1368	1.484±.0992	1.443±.0853	4.75	9.61	.035*	.004*
ACC	1.354 ± .1470		1.190±.0740		12.90		.001*	
Inferior temporal	3.439 ± .8787	3.169±.8532	3.174±.4221	2.641±.2501	.95	4.32	.33	.04*
OPC	.961 ± .2098	.944±.2110	.705±.0908	.756±.0549	15.92	9.01	.001*	.001*
Lateral temporal	1.254 ± .1090	1.195±.1449	1.120±.1008	1.102±.0592	12.05	4.48	.001*	.04*
Medial temporal	1.232 ± .1291	1.125±.1549	1.148±.0518	1.151±.0452	4.65	.31	.034*	.57
Basal ganglia	1.244 ± .1507	1.202±.1503	1.225±.0763	1.253±.0572	.17	1.25	.68	.27
Superior temporal	1.424 ± .1368	1.296±.1495	1.379±.0945	1.323±.0435	1.01	.36	.32	.55

*The F tests the difference between the group of schizophrenia patients and control subjects and is corrected with Levene's test for equality of error variances across groups. This test is based on the linearly independent pairwise comparisons among the estimated marginal means and the mean difference is significant at the .05 level of p after adjustment for multiple comparisons with Bonferroni.

VMPC: ventromedial prefrontal cortex; VLPC: ventrolateral prefrontal cortex; DLPC: dorsolateral prefrontal cortex; ACC: anterior cingulated cortex; OPC: orbital prefrontal cortex

Table 3: Frequency and proportional frequency of different perfusion states in each brain region of schizophrenia patients

Brain regions		State of regional brain perfusion in schizophrenia patients		
		Hypoperfusion	Normal perfusion	Hyperperfusion
Cerebellum	R	7 (21.2 %)	22(66.7%)	4 (12.1%)
	L	7 (21.2%)	24 (72.7%)	2 (6.1%)
VMPC	R	1 (3.0%)	29 (87.9%)	3 (9.1%)
	L	2 (6.1%)	28 (84.8%)	3 (9.1%)
VLPC	R	3 (9.1%)	22 (66.7%)	8 (24.2%)
	L	6 (18.2%)	19 (57.6%)	8 (24.2%)
DLPC	R	8 (24.2%)	22 (66.7%)	3 (9.1%)
	L	11 (33.3%)	18 (54.5%)	4 (12.1%)
Parietal	R	19 (57.6%)	8 (24.2%)	6 (18.2%)
	L	22 (66.7%)	7 (21.2%)	4 (12.1%)
Occipital	R	6 (18.2%)	26 (78.8%)	1 (3.0%)
	L	9 (27.3%)	22 (66.7%)	2 (6.1%)
ACC	-	1 (3.0%)	22 (66.7%)	10 (30.3%)
Inferior temporal	R	4 (12.1%)	12 (36.4%)	17 (51.5%)
	L	2 (6.1%)	11 (33.3%)	20 (60.6%)
OPC	R	2 (6.1%)	15 (45.5%)	16 (48.5%)
	L	3 (9.1%)	15 (45.5%)	15 (45.5%)
Lateral temporal	R	2 (6.1%)	17 (51.5%)	14 (42.4%)
	L	7 (21.2%)	15 (45.5%)	11 (33.3%)
Medial temporal	R	7 (21.2%)	18 (54.5%)	8 (24.2%)
	L	19 (57.6%)	7 (21.2%)	7 (21.2%)
Basal ganglia	R	7 (21.2%)	16 (48.5%)	10 (30.3%)
	L	13 (39.4%)	18 (54.5%)	2 (6.1%)
Superior temporal	R	9 (27.3%)	21 (63.6%)	3 (9.1%)
	L	16 (48.5%)	14 (42.4%)	3 (9.1%)

VMPC: ventromedial prefrontal cortex; VLPC: ventrolateral prefrontal cortex; DLPC: dorsolateral prefrontal cortex; ACC: anterior cingulate cortex; OPC: orbital prefrontal cortex

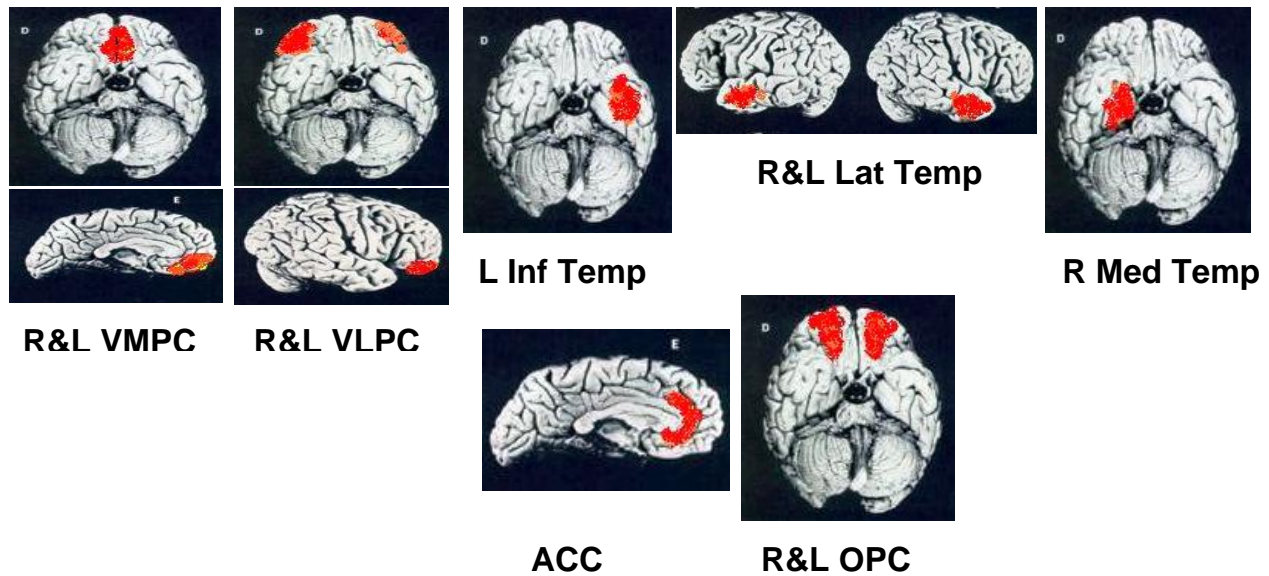


Figure 1: Regions with increased perfusion average as compared with control group

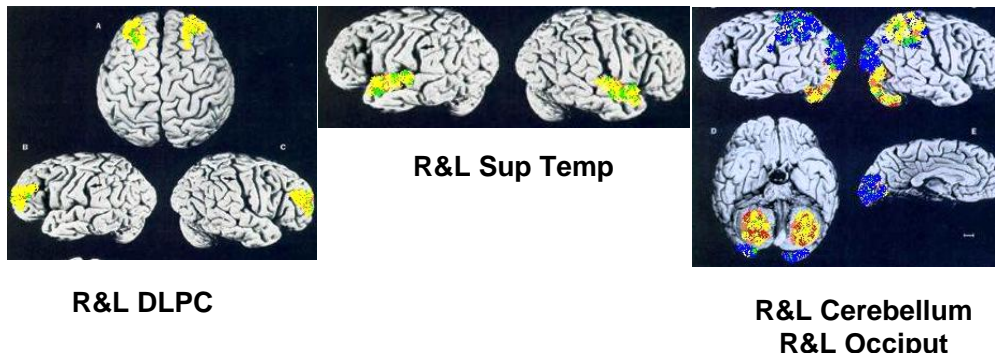


Figure 2: Regions with no difference (yellow) or decrease in perfusion average (blue) as compared with control group

A comparison of rCBF from all neuroleptic-naïve or neuroleptic-free patients to control subjects revealed significantly greater values mainly in the prefrontal cortex.

The most frequent PET/SPECT pattern reported in schizophrenia is hypofrontality. According to several articles, hypofrontality may be associated by the chronicity of illness, with a predominance of negative

symptoms and the aging process (20, 21). Some authors have pointed out that any observed rCBF pattern in schizophrenic patients may depend on the medication status of the patients examined (18), but even in unmedicated schizophrenic patients different rCBF patterns have been described. Some groups found hyperfrontality in unmedicated patients with acute disease (8-10,13,18). Catafau et al (8) found

prefrontally increased blood flow in neuroleptic naive schizophrenic patients, which they ascribed to positive symptoms. These authors concluded that there is no evidence of hypofrontality in young schizophrenic patients with acute disease who had never been exposed to neuroleptics. Other researchers measured hypofrontality in neuroleptic-naive patients (22).

Most frequently, it has been supposed that the small number of patients examined and the variety of techniques employed are the reasons for these variable findings.

Sabri et al (17), revealed no significant differences between regional rCBF of all their 24 drug-naïve schizophrenic patients and control subjects, primarily, but with separating the patients into different subgroups, the differences were noted and this difference in rCBF was shown to depend on the magnitude of the positive symptoms. In the present investigation, a relatively large number of actively psychotic schizophrenic patients (33 cases; 8 neuroleptic-naïve and 25 neuroleptic free) was studied and the results clearly show that hyperperfusion is more prominent in the anterior cingulate and inferior (ventral) parts of prefrontal and temporal cortices, while hypoperfusion is more frequent in the occipital, parital, superior temporal and dorsal parts of prefrontal cortex (Fig 1 & 2).

Weinberger et al. in 1988 (23) showed that positive symptoms may be related to the cortical or subcortical hyperdopaminergic state while negative symptoms may be related to the cortical hypodopaminergic state. It was hypothesized by these authors that hypofrontality and negative symptoms may be related to the cortical hypodopaminergic state, and positive symptoms may be related to the subcortical hyperdopaminergic state but this hypothesis was not proven. Significant negative correlations were found by Gonul et al (24) between the left superior frontal cortical perfusion and negative symptom scores not only during the drug-free period but also after the treatment. Evaluation of the magnitude of the correlation between the changes of rCBF and severity of the symptoms is a subject for further studies.

CONCLUSION

In different patients, hyperperfusion as well as normal or hypoperfusion may be noted in different regional brain cortices. However, hyperperfusion rather than hypoperfusion mainly is seen in the anterior cingulate, inferior prefrontal and temporal regions, while hypoperfusion patterns are more prominent in the occipital, parietal and dorsolateral prefrontal

cortices. Different symptoms of schizophrenia may be related to the hyperperfusion or hypoperfusion patterns of the brain cortex that this may be a subject for further studies.

ACKNOWLEDGEMENT

This research has been supported by Tehran University of Medical Sciences. The authors are indebted to the technologists especially Mrs. M. Darvishha and Mr. N. Ahmadin at our institute for their technical assistance.

REFERENCES

1. Bavelaar Brodie JD, Christman DR, Corona JF, Fowler JS, Gomez-Mont F, Jaeger J et al. Patterns of metabolic activity in the treatment of schizophrenia. *Ann Neurol* 1984; 15:166-169.
2. Buchsbaum MS, Ingvar DH, Kessler R, Waters RN, Cappelletti J, van Kammen DP et al. Cerebral glucography with positron tomography. Use in normal subjects and in patients with schizophrenia. *Arch Gen Psychiatry* 1982; 39:251-259.
3. DeLisi LE, Buchsbaum MS, Holcomb HH, Dowling-Zimmerman S, Pickar D, Boronow J et al. Clinical correlates of decreased anteroposterior metabolic gradients in positron emission tomography of schizophrenic patients. *Am J Psychiatry* 1985; 142:78-81.
4. Farkas T, Wolf AP, Jaeger J, Brodie JD, Christman DR, Fowler JS. Regional brain glucose metabolism in chronic schizophrenia. A positron emission transaxial tomographic study. *Arch Gen Psychiatry* 1984; 41:293-300.
5. Ingvar DH, Franzen G. Abnormalities of cerebral blood flow distribution in patients with chronic schizophrenia. *Acta Psychiatr Scand* 1974; 50:425-462.
6. Lewis SW, Ford RA, Syed GM, Reveley AM, Toone BU. A controlled study of ^{99m}Tc-HMPAO single-photon emission imaging in chronic schizophrenia. *Psychol Med* 1992; 22:27-35.
7. Wolkin A, Jaeger J, Brodie JD, Wolf AP, Fowler J, Rotrosen J et al. Persistence of cerebral metabolic abnormalities in chronic schizophrenia as determined by positron emission tomography. *Am J Psychiatry* 1985; 142:564-571.
8. Catafau AM, Parellada E, Lomeña FJ, Bernardo M, Pavía J, Ros D et al. Prefrontal and temporal blood flow in schizophrenia: resting and activation technetium-99m-HMPAO SPECT patterns in young neuroleptic-naive patients with acute disease. *J Nucl Med* 1994; 35(6):935-941.
9. Cleghorn JM, Garnett ES, Nahmias C, Firnau G, Brown GM, Kaplan R et al. Increased frontal and reduced parietal glucose metabolism in acute

- untreated schizophrenia. *Psychiatry Res* 1989; 28:119-133.
10. Szechtman H, Nahmias C, Garnett ES, Firnau G, Brown GM, Kaplan RD et al. Effect of neuroleptics on altered cerebral glucose metabolism in schizophrenia. *Arch Gen Psychiatry* 1988; 45:523-532.
 11. Volkow ND, Brodie JD, Wolf AP, Angrist B, Russel J, Cancro R. Brain metabolism in patients with schizophrenia before and after acute neuroleptic administration. *J Neurol Neurosurg Psychiatry* 1986; 49:1199-1202.
 12. Wiesel FA, Wik G, Sjogren I, Blomqvist G, Greitz T, Stone-Elander S. Regional brain glucose metabolism in drug free schizophrenic patients and clinical correlates. *Acta Psychiatr Scand*. 1987; 76:628-641.
 13. Sheppard G, Gruzelier J, Manchanda R, Hirsch SR, Wise R, Frackowiak R et al. Oxygen-15 positron emission tomographic scanning in predominantly never treated acute schizophrenic patients. *Lancet* 1983; 2:1448-1452.
 14. Devous MD SR, Paulman RG, Herman J, Gregory RR, Bonte FI, Raese JD. Single-photon tomography studies with schizophrenic patients. *J Clin Exp Neuropsychol* 1988; 10:321-322.
 15. Paulman RG, Devous MD SR, Gregory RR, Herman JH, Jennings L, Bonte FJ et al. Hypofrontality and cognitive impairment in schizophrenia: dynamic single-photon tomography and neuropsychological assessment of schizophrenic brain function. *Biol Psychiatry* 1990; 27:377-399.
 16. Syed GMS, Barret JJ, Toone BK. What does rCBF SPECT offer in schizophrenia? *Nucl Med Commun* 1992;13:879-884.
 17. Sabri O, Erkwoh R, Schreckenberger M, Cremerius U, Schulz G, Dickmann C et al. Regional cerebral blood flow and negative/positive symptom in 24 drug-naive schizophrenics. *J Nucl Med*.1997;38(2):181-8.
 18. Ebmeier KP, Blackwood DH, Murray C, Souza V, Walker M, Dougall N et al. Single-photon emission computed tomography with ^{99m}Tc-exametazimine unmedicated schizophrenic patients. *Biol Psychiatry* 1993; 33(7):487-495.
 19. Miller DD, Andreasen NC, O'Leary DS, Watkins GL, Boles Ponto LL, Hichwa RD. Comparison of the effects of risperidone and haloperidol on regional cerebral blood flow in schizophrenia. *Biol Psychiatry* 2001; 49:704-715.
 20. Volkow ND, Wolf AP, Van Gelder P, Brodie JD, Overall JE, Cancro R et al. Phenomenological correlates of metabolic activity in 18 patients with chronic schizophrenia. *Am J Psychiatry* 1987; 144: 151-158.
 21. Wolkin A, Sanfilippo M, Wolf AP, Angrist B, Brodie JD, Rotrosen J. et al. Negative symptoms and hypofrontality in chronic schizophrenia. *Arch Gen Psychiatry* 1992; 49:959-965.
 22. Andreasen NC, Rezaei K, Alliger R, Swayze VW 2nd, Flaum M, Kirchner P, et al. Hypofrontality in neuroleptic-naive patients and in patients with chronic schizophrenia. Assessment with xenon 133 single-photon emission computed tomography and the Tower of London. *Arch Gen Psychiatry* 1992;49:943-958.
 23. Weinberger DR, Berman KF, Illowsky BP. Physiological dysfunction of dorsolateral prefrontal cortex in schizophrenia. A new cohort and evidence for a monoaminergic mechanism. *Arch Gen Psychiatry* 1988; 45:609-615
 24. Gonul AS, Kula M, Sofuoğlu S, Tutus A, Esel E. Tc-99 HMPAO SPECT study of regional cerebral blood flow in olanzapine-treated schizophrenic patients. *Eur Arch psychiatry Clin Neurosci*. 2003;225:29-33.