

Application of Ursodeoxycholic Acid in Hepatobiliary Scintigraphy for Neonatal Hyperbilirubinemia: Comparison with Phenobarbital

Original Article

Enayatollah Nemat Khorasani¹, Fariba Mansouri²

¹Pediatrics Department, ²Internal Medicine Department, Imam Reza Hospital, Kermanshah University of Medical Sciences, Kermanshah, Iran.

(Received 31 August 2009, Revised 6 October 2009, Accepted 26 October 2009)

ABSTRACT

Introduction: Early differentiation of biliary atresia from neonatal hepatitis is of utmost importance, since on time surgery of biliary atresia significantly improves the outcome. Hepatobiliary scintigraphy is an integral part of diagnosis work-up of these patients; however its specificity for diagnosis of biliary atresia is suboptimal. In this study we evaluated the value of ursodeoxycholic acid pre-treatment for improvement of hepatobiliary scintigraphy specificity.

Methods: Thirty consecutive infants with direct hyperbilirubinemia were included into the study. All infants underwent hepatobiliary scintigraphy with ^{99m}Tc-bromo iminodiacetic acid (^{99m}Tc-BRIDA) twice (first after pre-treatment with phenobarbital and the other time after pre-treatment with ursodeoxycholic acid).

Results: Of 30 patients included into our study 13 had final diagnosis of extrahepatic biliary atresia and 17 had neonatal hepatitis. Bowel was visualized in 11 patients with neonatal hepatitis after phenobarbital pre-treatment and in 16 after ursodeoxycholic acid pretreatment which amounts to 80 % and 96.6 % specificity for diagnosis of biliary atresia with phenobarbital and ursodeoxycholic acid respectively. All patients had complications of phenobarbital administration (lethargy, poor feeding, irritability, hypotonia, etc) to some extent. These findings decreased significantly after discontinuation of phenobarbital and were not present with ursodeoxycholic acid.

Conclusion: Ursodeoxycholic acid is a safe and efficient drug for pre-treatment of patients with neonatal cholestasis syndrome who are going to undergo hepatobiliary scintigraphy. Compared to phenobarbital, this drug has fewer complications and is more efficient.

Key words: Ursodeoxycholic acid, Hepatobiliary scintigraphy, ^{99m}Tc-BRIDA, Infantile jaundice, Neonatal hyperbilirubinemia

Iran J Nucl Med 2009;17(2):20-25

Corresponding author: Dr Enayatollah Nemat Khorasani, Pediatrics Department, Imam Reza Hospital, Kermanshah University of Medical Sciences, Kermanshah, Iran.
E-mail: Khorasani@dr.com

INTRODUCTION

Hyperbilirubinemia and persistent jaundice beyond two weeks of age in full-term infants and three weeks in preterm infants is not physiological (1, 2). The two most common categories of neonatal cholestasis are intrahepatic causes (which are loosely called neonatal hepatitis) and extrahepatic biliary atresia. The etiologies of the former are usually of infectious, metabolic or genetic nature. The latter is caused by mechanical obstruction in the extrahepatic bile ducts usually due to failure of canalization during fetal growth (3). Early differentiation of these two entities is of utmost importance, since on time surgery of biliary atresia significantly improves the outcome. Any delay in this treatment can cause unrecoverable and serious damage to liver tissue resulting in biliary cirrhosis (4).

Many procedures are in use for differentiation of the above mentioned pathologies; including liver biopsy, ultrasonography, hepatobiliary scintigraphy, etc (5). Hepatobiliary scintigraphy is usually used for patients with neonatal cholestasis with excellent sensitivity. Radionuclide studies of the hepatobiliary system are usually performed with ^{99m}Tc -diisopropyl iminodiacetic acid (^{99m}Tc -DISIDA) or ^{99m}Tc -methylbromo iminodiacetic acid (^{99m}Tc -mebrofenin or ^{99m}Tc -BRIDA). These tracers are transported to the liver bound to albumin and are actively taken up by the hepatocytes. These compounds are not conjugated, but are excreted into the bile canaliculi following the same anionic pathway as bilirubin. Patients are typically premedicated with phenobarbital (5 mg/Kg/bid given for 5 days). It stimulates the hepatic transport system for organic anions. This is primarily achieved by induction of hepatic microsomal enzymes, thereby increasing bilirubin conjugation and excretion (6). However when the hepatic function is poor due to hepatocellular damage, differentiation of biliary atresia

from neonatal hepatitis can be impossible with hepatobiliary scintigraphy which significantly decreases the specificity of this imaging modality even with phenobarbital pre-treatment (7). Several other approaches have been used to increase the specificity of hepatobiliary scintigraphy with various results (8-10). One of these methods is pre-treatment of the patients with ursodeoxycholic acid (9, 11-14). However the evidence in literature regarding its use is scant and in this study we evaluated the value of this drug in hepatobiliary scintigraphy with the direct comparison with phenobarbital.

METHODS

We evaluated 30 consecutive infants with (age range 2-8 weeks) with neonatal cholestasis (direct bilirubine more than 20% of the total bilirubin). Each infant had careful clinical examination and underwent ultrasonography before including into the study in order to exclude possible choledochal cyst.

All infants were pre-treated with phenobarbital (5mg/Kg bid for 5 days). Subsequently 1 mCi ^{99m}Tc -BRIDA was injected intravenously to each patient. Immediate dynamic imaging was performed (60 sec/frame) for 30 minutes in the supine position. Delayed imaging was done till 24 hours in various intervals.

After a week interval (turn over time of phenobarbital), all patients received 20 mg/Kg bid of ursodeoxycholic acid for 5 days and hepatobiliary scintigraphy was repeated with the same protocol.

Liver biopsy and intraoperative cholangiography were used for the patients without bowel visualization. Since there is no gold standard for final diagnosis of neonatal hepatitis, we used combination of the results of clinical data and the findings of serologic and other etiologic investigations (including serum and urinary chromatography, thyroid function tests,

sweat test, α 1 antitrypsin of serum, TORCH study and hepatitis viruses' infections) (15, 16).

This study was approved by the local ethical committee of our university and informed consent was taken from the parents.

RESULTS

Of 30 patients included into our study 13 had final diagnosis of extrahepatic biliary atresia and 17 had neonatal hepatitis. The etiologies of neonatal hepatitis were as follows: 8 patients with α 1 antitrypsin deficiency, 3 patients tyrosinemia, 3 patients Galctosemia, and 3 patients TORCH infections.

Bowel was visualized in 11 patients with neonatal hepatitis after phenobarbital pretreatment and in 16 after ursodeoxycholic acid pretreatment. This amounts to specificity of 80 % and 96.6 % for diagnosis of biliary atresia with phenobarbital and ursodeoxycholic acid respectively.

All patients had complications of phenobarbital administration (lethargy, poor feeding, irritability, hypotonia, etc) to some extent. These findings decreased significantly after discontinuation of phenobarbital and were not present with ursodeoxycholic acid.

Figure 1 shows a patient with the diagnosis of neonatal hepatitis and bowel visualization only after ursodeoxycholic acid treatment.

DISCUSSION

Despite several efforts to improve the specificity of hepatobiliary scintigraphy for diagnosis of biliary atresia, this figure remained sub-optimal (about 75-80% in most series) (10, 17). phenobarbital is the most frequent drug which is used for pre-treatment of infants with neonatal cholestasis with some favorable results (6). However the effect of phenobarbital is controversial and some authors do not

recommend it before hepatobiliary scintigraphy due to its complications or suboptimal results (8, 18).

Another drug which has been used for pre-treatment in hepatobiliary scintigraphy is ursodeoxycholic acid. The effect of this drug on hepatocellular function was reported first by several groups such as Hayakawa et al, Ullrich et al and Salva et al. They reported improvement in hepatic function after ursodeoxycholic administration to patients with history of chronic liver disease (14, 19, 20). It is also used for post-operative management of the patients with biliary atresia as well as treatment of chronic liver disease (21, 22). Several mechanisms are proposed for the effect of ursodeoxycholic on the hepatocellular function such as "direct cytoprotection, a detergent action on dysfunctional microtubules, immunomodulation, and induction of hypercholesteris" (9).

Johnson et al. in a study reported that ursodeoxycholic acid changed the pattern of the scan from non-excretor to excretor in 5 patients with neonatal hepatitis (23). Colombo et al. also reported improvement in the hepatobiliary scintigraphy 1 year after initiation of ursodeoxycholic acid in patients with cystic fibrosis (13). Poddar et al. in a study showed that ursodeoxycholic acid administration can improve the specificity of hepatobiliary scintigraphy for diagnosis of biliary atresia from 54.3% to 88.6% (9). Our study also supports Poddar et al. findings since the specificity of the study increased from 80% to 96.6% after ursodeoxycholic administration.

To the extent of our knowledge no other study has compared the effect of phenobarbital with ursodeoxycholic acid in a same group of patients as we did in our study. As mentioned above, ursodeoxycholic acid was superior to phenobarbital considering the specificity of the test for diagnosis of biliary atresia. The complications of pre-treatment with ursodeoxycholic acid are negligible (such as

lethargy, poor feeding, irritability, and hypotonia) compared to phenobarbital. Poddar et al and Jeong et al in separate studies involving ursodeoxycholic acid

administration didn't find any adverse effect (9, 11). We have the same results as the two studies mentioned above.

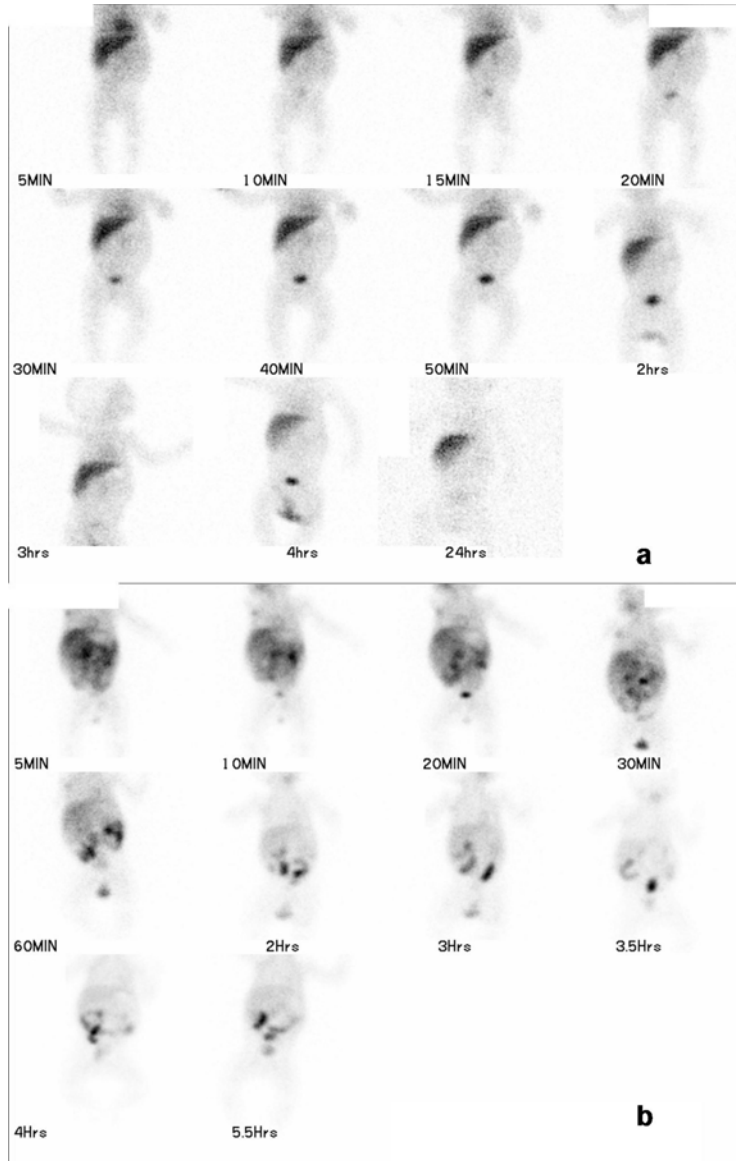


Figure 1. Hepatobiliary scintigraphy of a patient with neonatal hepatitis. Note non-visualization of the bowel after phenobarbital pre-treatment (a) and bowel excretion of the tracer after administration of ursodeoxycholic acid (b).

CONCLUSION

Ursodeoxycholic acid is a safe and efficient drug for pre-treatment of patients with neonatal cholestasis syndrome who are going to undergo hepatobiliary scintigraphy. Compared to phenobarbital, this drug has fewer complications and is more efficient.

REFERENCES

- Balistreri WF. Neonatal cholestasis. *J Pediatr* 1985;106:171-184.
- Miyano T, Fujimoto T, Ohya T, Shimomura H. Current concept of the treatment of biliary atresia. *World J Surg* 1993;17:332-336.
- Roach JP, Bruny JL. Advances in the understanding and treatment of biliary atresia. *Curr Opin Pediatr* 2008;20:315-319.
- Mieli-Vergani G, Howard ER, Portman B, Mowat AP. Late referral for biliary atresia: missed opportunities for effective surgery. *Lancet* 1989;1:421-423.
- Burton EM, Babcock DS, Heubi JE, Gelfand MJ. Neonatal jaundice: clinical and ultrasonographic findings. *South Med J* 1990;83:294-302.
- Majd M, Reba RC, Altman RP. Effect of phenobarbital on ^{99m}Tc-IDA scintigraphy in the evaluation of neonatal jaundice. *Semin Nucl Med* 1981;11:194-204.
- Gilmour SM, Hershkop M, Reifen R, Gilday D, Roberts EA. Outcome of hepatobiliary scanning in neonatal hepatitis syndrome. *J Nucl Med* 1997;38:1279-1282.
- Gupta DK, Charles AR, Srinivas M, Dave S, Bal CS. Betamethasone in plus phenobarbitone prior to hepatobiliary scintigraphy increases diagnostic accuracy in infants with jaundice. *Indian J Pediatr* 2001;68:1039-1041.
- Poddar U, Bhattacharya A, Thapa BR, Mittal BR, Singh K. Ursodeoxycholic acid-augmented hepatobiliary scintigraphy in the evaluation of neonatal jaundice. *J Nucl Med* 2004;45:1488-1492.
- Sadeghi R, Kianifar HR, Kakhki VR, Zakavi SR, Ansari K. ^{99m}Tc sestamibi imaging - can it be a useful substitute for hepatobiliary scintigraphy in infantile jaundice? *Nuklearmedizin* 2009;48:100-103.
- Jeong HJ, Kim CG. Pretreatment with ursodeoxycholic acid (UDCA) as a novel pharmacological intervention in hepatobiliary scintigraphy. *Yonsei Med J* 2005;46:394-398.
- Colombo C, Crosignani A, Battezzati PM, Castellani MR, Comi S, Melzi ML et al. Delayed intestinal visualization at hepatobiliary scintigraphy is associated with response to long-term treatment with ursodeoxycholic acid in patients with cystic fibrosis-associated liver disease. *J Hepatol* 1999;31:672-677.
- Colombo C, Castellani MR, Balistreri WF, Seregni E, Assaisso ML, Giunta A. Scintigraphic documentation of an improvement in hepatobiliary excretory function after treatment with ursodeoxycholic acid in patients with cystic fibrosis and associated liver disease. *Hepatology* 1992;15:677-684.
- Hayakawa T, Katagiri K, Shiraka S, Nakai T, Takeshima A, Kawamura Y et al. [The influence of ursodeoxycholic acid on hepatobiliary scintigraphy with ^{99m}Tc-N-pyridoxyl-5-methyltryptophan in chronic liver diseases]. *Nippon Shokakibyo Gakkai Zasshi* 1988;85:2389-2395.
- Sadeghi R. Evidence based medicine in nuclear medicine practice. Part I: Introduction, Asking answerable questions and searching for the best evidence. *Iran J Nucl Med* 2009;17(1):41-48.
- Sadeghi R. Evidence based medicine in nuclear medicine practice. Part II: Appraising and applying the evidence. *Iran J Nucl Med* 2009; 17(1):49-56.
- Rodeck B, Becker AC, Gratz KF, Petersen C. Early predictors of success of Kasai operation in children with biliary atresia. *Eur J Pediatr Surg* 2007;17:308-312.
- Charearnrad P, Chongsrisawat V, Tepmongkol S, Poovorawan Y. The effect of phenobarbital on the accuracy of technetium-^{99m} diisopropyl iminodiacetic acid hepatobiliary scintigraphy in differentiating biliary atresia from neonatal hepatitis syndrome. *J Med Assoc Thai* 2003;86 Suppl 2:S189-194.
- Ullrich D, Rating D, Schroter W, Hanefeld F, Bircher J. Treatment with ursodeoxycholic acid renders children with biliary atresia

- suitable for liver transplantation. *Lancet* 1987;2:1324.
20. Sarva RP, Fromm H, Farivar S, Sembrat RF, Mendelow H, Shinozuka H et al. Comparison of the effects between ursodeoxycholic and chenodeoxycholic acids on liver function and structure and bile acid composition in the Rhesus Monkey. *Gastroenterology* 1980;79:629-636.
 21. Willot S, Uhlen S, Michaud L, Briand G, Bonneville M, Sfeir R et al. Effect of ursodeoxycholic acid on liver function in children after successful surgery for biliary atresia. *Pediatrics* 2008;122:e1236-1241.
 22. Tarao K, Fujiyama S, Ohkawa S, Miyakawa K, Tamai S, Hirokawa S et al. Ursodiol use is possibly associated with lower incidence of hepatocellular carcinoma in hepatitis C virus-associated liver cirrhosis. *Cancer Epidemiol Biomarkers Prev* 2005;14:164-169.
 23. Johnson K, Alton HM, Chapman S. Evaluation of mebrofenin hepatoscintigraphy in neonatal-onset jaundice. *Pediatr Radiol* 1998;28:937-941.