

## Spinal cord metastasis from testicular seminoma detected by F-18 FDG PET/CT study prior to neurological symptoms: An unusual presentation

Armaghan Fard-Esfahani, Mehraneh Marzban, Alireza Emami-Ardekani,  
Arman Hassanzadeh-Rad, Babak Fallahi, Davood Beiki,  
Parham Geramifar, Mohammad Eftekhari

Research Center for Nuclear Medicine, Shariati Hospital,  
Tehran University of Medical Sciences, Tehran, Iran

(Received 5 April 2016, Revised 19 May 2016, Accepted 20 May 2016)

### ABSTRACT

A 60-year-old patient with testicular seminoma was referred for F-18 FDG PET/CT Study to evaluate recurrence. In addition to hypermetabolic cervical, mediastinal and hilar lymph node tumoral metastases, segmental intense FDG uptake along the lumbar spinal cord suggestive of tumoral metastasis was noted which quite an unusual presentation is. At the time of PET study the patient was symptomless, and neurological symptoms and signs associated with spinal cord metastasis developed only several days afterwards, emphasizing the role of FDG PET study in early detection of spinal cord metastasis. The patient underwent radiotherapy of the spinal cord with consequent clinical improvement.

**Key words:** Spinal cord metastasis; Seminoma; Testicular cancer; F-18 FDG PET scan

**Iran J Nucl Med 2016;24(2):147-149**

Published: July, 2016

<http://irjnm.tums.ac.ir>

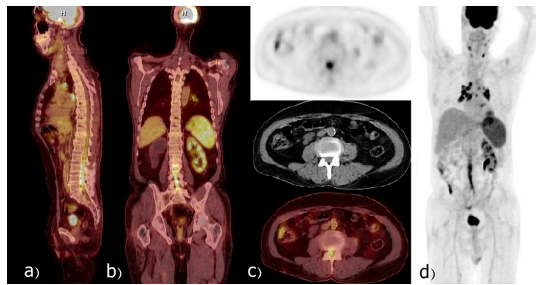
**Corresponding author:** Dr. Armaghan Fard-Esfahani, Research Center for Nuclear Medicine, Shariati Hospital, N Kargar Ave. 1411713135, Tehran, Iran. E-mail: [fardesfa@tums.ac.ir](mailto:fardesfa@tums.ac.ir)

## INTRODUCTION

Metastatic testicular seminoma usually presents with retroperitoneal lymph node involvement while spinal cord metastasis is a rare finding. FDG PET study can detect metastatic lesions before conventional diagnostic procedures and as in this case, prior to relevant clinical symptoms.

## CASE REPORT

A 60-year-old patient with a testicular mass underwent radical orchiectomy following pathologic confirmation of pure classic seminoma. He received 5 cycles of chemotherapy. Three years later, he presented with cervical lymphadenopathy with no other symptoms. The neck-chest CT study showed bilateral neck as well as significant mediastinal lymphadenopathy. Abdominal and pelvic CT scans were unremarkable. The tumor markers were not elevated. To investigate for extent of involvement, a whole body F-18 PET/CT was performed 60 minute after intravenous injection of 388.5 MBq of F-18 FDG by PET/CT scanner (siemens biograph 6, LSO crystal, 3 ring) demonstrating intense FDG uptake (SUVmax= 7.94) in the spinal cord at L2-L5 level, in addition to metabolically active lymph nodes in the cervical (SUVmax= 9), mediastinal (SUVmax= 12.98) and hilar (SUVmax= 13.9) regions, all consistent with hypermetabolic metastatic involvement (Figure 1).



**Fig 1.** F-18 Fluorodeoxyglucose (FDG) PET/CT images: (a) Sagittal and (b) Coronal (c) Transaxial images show hypermetabolic metastatic involvement along the spinal cord at L2-L5 levels. Increased FDG uptake in the spleen is attributed to extramedullary hematopoiesis, secondary to post-chemotherapy bone marrow suppression. (d) Maximal intensity projection image shows hypermetabolic metastatic lymph nodes in the cervical, mediastinal and pulmonary hilar regions, in addition to metastatic involvement of the spinal cord.

Furthermore, diffuse FDG uptake observed in the spleen was attributed to extramedullary hematopoiesis, secondary to post-chemotherapy bone marrow suppression (Figure 1). Although at the time of performing PET/CT study the patient had no

neurological symptoms to support the finding of spinal cord FDG-avid metastasis, several days later he was admitted with newly developed symptoms of sensory loss of lower extremities progressing to paralysis and urinary incontinence. Due to rapid exacerbation of the symptoms, patient was referred to the department of radiation oncology with diagnosis of metastatic spinal cord involvement and was palliatively cured.

## DISCUSSION

Testicular cancer is the most common solid tumor in young men between 15 and 34 years old with increasing incidence worldwide [1]. Testicular cancer commonly presents as a unilateral lump or painless swelling noticed incidentally. Pain is less common, 1/3 of patients present with a dull ache, acute pain is uncommon, occurring in 10% of patients. Testis cancers uncommonly present with symptoms related to metastatic disease [2]. Germ cell tumors (GCT) consists 95% of malignant testicular tumors. GCT is classified as seminoma or nonseminoma. Tumor markers including alpha-fetoprotein (AFP), lactate dehydrogenase and of  $\beta$ HCG ( $\beta$ -subunit of human chorionic gonadotropin) are critical in diagnosis, determining prognosis and assessing treatment outcome [3]. Pure testicular seminomas do not have specific serum tumor markers, but in certain cases can produce a small amount of  $\beta$ HCG [4]. Treatment of these tumors may consist of surgery, radiotherapy, chemotherapy or a combination of them, depending on the stage and type of the tumor [3].

Relapse rate is reported around 15%-20% in 5 years, mostly being detected in infradiaphragmatic lymph nodes, mainly in the retroperitoneal paraaortic region [5-7]. Our patient's relapse occurred 3 years after his primary diagnosis, with cervical lymphadenopathy which is not a common relapsing site in these patients. Hematogenous spread is more common in non-seminomatous germ cell tumors and metastases usually occur in the lungs, liver, and brain [8]. However, the metastasis from the presented case of seminoma occurred in the spinal cord which is a rare location for involvement (Figure 1).

PET scanning does not contribute in early stages of seminoma [I, B], but is a possible option for stages II/III, in particular for defining treatment strategy in case of residual tumor [9]. PET/CT especially has significance in detection of metastasis, and is superior to other conventional methods [10-14].

A report of 2,550 patients revealed bone metastases only in 3 cases with seminoma (0.12%) [15]. Moreover, CNS metastasis occurred only once in a series of 142 patients (0.7%) [16]. Recently Gómez et al. reported a case of testicular germ cell tumor who was referred for F-18 FDG PET/CT for progressive

decline in clinical status including spinal pain, gait difficulty and Charcot's neurologic triad (scanning speech, intention tremor and nystagmus). PET/CT scan demonstrated two focal hypermetabolic metastatic lesions, one in the spinal cord at C4-C5 vertebral levels and second, in the cerebellum [17]. The discovery of the CNS metastasis localized in spinal cord at L2-L5 level in our case (Figure 1) is rather unique since PET/CT was positive before neurological symptoms.

In summary, our case illustrates the rare presentation of relapsing seminoma with spinal cord metastasis, pointing to the potential of FDG PET/CT for correct localization of the CNS metastasis, early diagnosis and effective treatment decision.

### CONCLUSION

CNS especially spinal cord metastasis is a rare presentation in cases of testicular tumors. In this report, early detection of unsuspected spinal cord metastasis before occurrence of clinical symptoms is presented. The potential of PET/CT in early diagnosis and treatment decision making is emphasized.

### REFERENCES

- Groll RJ, Warde P, Jewett MA. A comprehensive systematic review of testicular germ cell tumor surveillance. *Crit Rev Oncol Hematol*. 2007 Dec;64(3):182-97.
- Khan O, Protheroe A. Testis cancer. *Postgrad Med J*. 2007 Oct;83(984):624-32.
- Motzer RJ, Jonasch E, Agarwal N, Beard C, Bhayani S, Bolger GB, Chang SS, Choueiri TK, Costello BA, Derweesh IH, Gupta S, Hancock SL, Kim JJ, Kuzel TM, Lam ET, Lau C, Levine EG, Lin DW, Michaelson MD, Olencki T, Pili R, Plimack ER, Rappersaud EN, Redman BG, Ryan CJ, Sheinfeld J, Shuch B, Sircar K, Somer B, Wilder RB, Dwyer M, Kumar R. Testicular Cancer, Version 2.2015. *J Natl Compr Canc Netw*. 2015 Jun;13(6):772-99.
- Boujelbene N, Cosinschi A, Boujelbene N, Khanfir K, Bhagwati S, Herrmann E, Mirimanoff RO, Ozsahin M, Zouhair A. Pure seminoma: a review and update. *Radiat Oncol*. 2011 Aug 8;6:90.
- Aparicio J, García del Muro X, Maroto P, Paz-Ares L, Alba E, Sáenz A, Terrasa J, Barnadas A, Almenar D, Arranz JA, Sánchez M, Fernández A, Sastre J, Carles J, Dorca J, Gumà J, Yuste AL, Germà JR; Spanish Germ Cell Cancer Cooperative Group (GG). Multicenter study evaluating a dual policy of postorchietomy surveillance and selective adjuvant single-agent carboplatin for patients with clinical stage I seminoma. *Ann Oncol*. 2003 Jun;14(6):867-72.
- Warde P, Specht L, Horwich A, Oliver T, Panzarella T, Gospodarowicz M, von der Maase H. Prognostic factors for relapse in stage I seminoma managed by surveillance: a pooled analysis. *J Clin Oncol*. 2002 Nov 15;20(22):4448-52.
- Chung P, Parker C, Panzarella T, Gospodarowicz MK, Jewett S, Milosevic MF, Catton CN, Bayley AJ, Tew-George B, Moore M, Sturgeon JF, Warde P. Surveillance in stage I testicular seminoma - risk of late relapse. *Can J Urol*. 2002 Oct;9(5):1637-40.
- Dearnaley D, Huddart R, Horwich A. Regular review: Managing testicular cancer. *BMJ*. 2001 Jun 30;322(7302):1583-8.
- Schmoll HJ, Jordan K, Huddart R, Pes MP, Horwich A, Fizazi K, Kataja V; ESMO Guidelines Working Group. Testicular seminoma: ESMO Clinical Practice Guidelines for diagnosis, treatment and follow-up. *Ann Oncol*. 2010 May;21 Suppl 5:v140-6.
- Ambrosini V, Zucchini G, Nicolini S, Berselli A, Nanni C, Allegri V, Martoni A, Rubello D, Cricca A, Fanti S. 18F-FDG PET/CT impact on testicular tumours clinical management. *Eur J Nucl Med Mol Imaging*. 2014 Apr;41(4):668-73.
- Cook GJ, Sohaib A, Huddart RA, Dearnaley DP, Horwich A, Chua S. The role of 18F-FDG PET/CT in the management of testicular cancers. *Nucl Med Commun*. 2015 Jul;36(7):702-8.
- Nirmal TJ, Kekre NS. Management of urological malignancies: Has positron emission tomography/computed tomography made a difference? *Indian J Urol*. 2015 Jan-Mar;31(1):22-7.
- Becherer A. PET in testicular cancer. *Methods Mol Biol*. 2011;727:225-41.
- Rioja J, Rodríguez-Fraile M, Lima-Favaretto R, Rincón-Mayans A, Peñuelas-Sánchez I, Zudaire-Bergera JJ, Parra RO. Role of positron emission tomography in urological oncology. *BJU Int*. 2010 Dec;106(11):1578-93.
- Jamal-Hanjani M, Karpathakis A, Kwan A, Mazhar D, Ansell W, Shamash J, Harper P, Rudman S, Powles T, Chowdhury S. Bone metastases in germ cell tumours: lessons learnt from a large retrospective study. *BJU Int*. 2013 Jul;112(2):176-81.
- Mencil PJ, Motzer RJ, Mazumdar M, Vlamis V, Bajorin DF, Bosl GJ. Advanced seminoma: treatment results, survival, and prognostic factors in 142 patients. *J Clin Oncol*. 1994 Jan;12(1):120-6.
- Gómez FJ, Báñez IA, González RL, Jiménez-Granero P, Dorado IB. 18F-FDG PET/CT with unusual bone and CNS metastases from testicular seminoma. *Int Braz J Urol*. 2015 Mar-Apr;41(2):393-4.