

Abnormal cerebral blood flow in methamphetamine abusers assessed by brain perfusion single emission computed tomography

Vahid Reza Dabbagh Kakhki¹, Fereshteh Madani Sani², Bita Dadpour^{3,4}

¹Nuclear Medicine Research Center, Mashhad University of Medical Sciences, Mashhad, Iran

²Cardiac Anesthesia Research Center, Mashhad University of Medical Sciences, Mashhad, Iran

³Medical Toxicology Research Center, Mashhad University of Medical Sciences, Mashhad, Iran

⁴Addiction Research Centre, Faculty of Medicine, Mashhad University of Medical Sciences, Mashhad, Iran

(Received 14 August 2016, Revised 12 November 2016, Accepted 16 November 2016)

ABSTRACT

Introduction: Amphetamines are central nervous system (CNS) stimulant substances and amphetamine abuse is considered a growing problem in our country. Previous studies revealed destructive effects of amphetamines on metabolism, perfusion and structure of brain. The aim of current study was evaluating regional cerebral blood flow (rCBF) disturbances in methamphetamine (MA) abusers using brain perfusion SPECT.

Methods: This case control study was carried out on 15 MA abusers and 10 healthy volunteers. All 15 MA abusers had a history of MA abuse for at least one year, positive qualitative urinary test for amphetamine. All cases were substance dependent based on Diagnostic and Statistical Manual of Mental Disorders, 4th Edition (DSM-IV) criteria. Patients with opioid and other substance abuse except nicotine and caffeine, positive history of head trauma, loss of consciousness more than 30 minutes and also pregnant women were excluded. All subjects underwent brain perfusion Single-photon emission computed tomography (SPECT).

Results: Of 15 MA users 11 and 4 cases were males and females respectively. Mean age was 42/46±12.08 (range: 22-65) years old. Mean age of control group was 39.56±10.10 (range: 25-63) years old. All MA abusers were currently on using MA. Mean dose of MA use was 0.7 gram per day and mean duration of consumption was 4.86 (1-12) years. Significant differences were observed in scan results (normal or abnormal scan) between two groups ($p<0.05$). Of all 15 MA abusers, global decreased tracer uptake was observed in 4 patients (26.7%), global decrease uptake except for the cerebellum was detected in 6 cases (40%), and decreased tracer uptake in fronto-temporal lobes was observed in 2 cases (13.3%), decreased uptake was detected only in the temporal lobe in 2 patients (13.3%) and in temporo-occipital lobes in one case (6.7%). In patients group, decrease in perfusion was more prominent in right frontal, superior frontal and parietal lobes compared with left hemisphere. SPM (Statistical Parametric Mapping) analysis showed significant difference in rCBF between MA abusers and normal volunteers throughout the cerebral cortex with nonhomogeneous decreased tracer uptake.

Conclusion: In this study, we showed that amphetamine abuse can induce diffuse and nonhomogeneous disorders of brain perfusion which was more prominent in the right hemisphere.

Key words: Methamphetamine; Abuse; Cerebral blood flow; Brain Perfusion SPECT

Iran J Nucl Med 2017;25(Suppl 1):47-51

Published: February, 2017

<http://irjnm.tums.ac.ir>

Corresponding author: Dr. Bita Dadpour, Addiction Research Centre, Faculty of Medicine, Mashhad University of Medical Sciences, Mashhad, Iran. E-mail: dadpourb@mums.ac.ir

INTRODUCTION

It is estimated that more than 35 million people consume amphetamine compound, regularly (United Nations Office on Drug and Crime, 2003).

Over the past decades, methamphetamine (MA) abuse is significantly increased and turned to a central concern in public health [1].

A combination that mainly consists of methamphetamine (methamphetamine \pm amphetamine) is consumed as a commonly used amphetamine compound with street name "Shisheh" (glass) in Iran. The route of consumption is inhalation to a large extent and in less commonly is intra venous injection. Methylphenidate and "ecstasy-type" drugs belong to this class as well.

MA induces a false feeling of well-being, an overestimation of mental and physical capacities. Insomnia, loss of appetite and psychosis are some other effects of MA abuse. It is a rapidly addictive substance in repeated consumption. As a neurotoxin, it can induce adrenergic hyperactivity by changing in brain neurotransmitters and monoamine levels. Stimulation of sympathetic nervous system activity results in tachycardia, hypertension and cardiac dysrhythmia. MA overdose may be associated with palpitation, angina, myocardial infarction and ventricular fibrillation. High temperature, ischemic and hemorrhagic stroke and convulsion are some other anticipated consequences in acute overdose [2].

In short term consumption, patients may experience tremor, insomnia, loss of appetite, euphoria, overexcitement and loquacity although some other effects such as emotional changes, anxiety, violent behavior, hallucinations and paranoia may develop in long term use. Undesirable alterations in neurobehavioral function due to MA abuse such as memory, response inhibition, decision making and attention impairment may be persistent for a long term period after abstinence [3, 4].

Brain effects of MA are considered as an important concern over the last two decades. By performing brain perfusion SPECT, it is demonstrated that binge MA consumption might lead to long term alteration in regional and global blood flow in a hypo perfusion pattern which looks like a previously reported picture of Parkinson disease [5]. Another investigation by fractional brain Magnetic Resonance Imaging (MRI) revealed that prefrontal and orbito frontal dysfunction in MA-dependent subjects resulted in serious problems in decision-making [3].

There are several brain imaging studies on how can MA affect on structure and chemistry of brain in animal and human. As a stimulant substance, brain dopaminergic and serotonergic pathways might be damaged by continues use of MA. Dopamine transporters of striatum in MA abusers were lower

than control group in a PET study [6]. Perfusion alteration, varying neuronal metabolites and activation of cortex were found in previous brain imaging investigations in MA abusers [7].

In current investigation, we evaluated cerebral blood flow (CBF) disturbances in methamphetamine (MA) abusers using brain perfusion SPECT.

METHODS

Fifteen admitted patients in Medical Toxicology Centre with diagnosis of methamphetamine abuse were recruited. They were referred for MA abstinence and this study was carried out before implementation of abstinence program. A semi-structured clinical interview was performed by an expert psychiatrist. Inclusion criteria were: (1) ages: 19–49 years, (2) MA dependency determined by Structured Clinical Interview for DSM-IV (SCID-IV), which was administered by an expert psychiatrist. Exclusion criteria were: (1) any significant neurological or medical illness in past or current (2) history of any psychotic disorders requiring psychotropic drugs (3) use of any other illegal substances at least in last one year (4) head trauma and loss of consciousness more than 30 minutes and (5) finally pregnancy. All patients and also control group fulfilled written informed consent. Volunteers were selected among physicians, students and patients with respect to all criteria for entry and exit from the study. This study was approved by the institutional review board and human ethics of Mashhad University of Medical Sciences. After giving written informed consent, the subjects received the SPECT brain perfusion SPECT study. Two groups were matched based on sex and age. There was no significant difference in term of age and gender between patients (11 men and 4 women, 42.46 ± 12.08 years) and control group (6 men and 4 women, 39.56 ± 10.10 years).

Urinary screen test for amphetamine compounds was done for all patients as well as controls before performing brain perfusion scan.

Brain perfusion SPECT

Twenty minutes after accessing IV line and in quiet environment, 20 mCi (740 MBq) ^{99m}Tc -ECD was administered and after 40 minutes of radiotracer injection, the SPECT images were obtained using a gamma camera (Dual-head gamma camera; ECAM; Siemens) equipped with a low-energy, high resolution collimator. Sixty four images were acquired of 10 s each using 128×128 matrix in 360° camera rotation. Tomographic data reconstruction was carried out and Trans axial, sagittal, and coronal reconstructions were generated using back-projection and a Butterworth filter. Chang's attenuation correction was performed. Brain perfusion scans were interpreted by two nuclear

medicine specialists separately which were blind to the all subjects; if contradictory results were obtained viewpoint of third nuclear medicine specialist would be exerted. Total count of regions of interest (ROI) and maximum count in each ROI and Voxel (3mm) were calculated. The ratio of total and maximal count of each lobe (Figure 1) on cerebellum was compared between control and patient groups. The right and left lobes in patient group were also compared. Images were analyzed using statistical parametric mapping (SPM).

Statistical analysis

Statistical parametric mapping (SPM) was used to determine the difference of relative regional cerebral flow (rCBF) in ^{99m}Tc -ECD SPECT images between MA users and healthy comparison subjects. After spatial and count normalization, significant differences of rCBF between MA users and healthy comparison subjects were estimated at every voxel using t-statistics. Analysis for statistical parametric mapping (SPM) was performed in MATLAB environment. All SPECTs of patients and normal controls were spatially normalized to the standard SPECT template embedded in SPM, and smoothed with m Gaussian filter. The unpaired t test was used for comparison between two groups. Results were obtained at $p < 0.05$ corrected for multiple comparisons.

Group differences in variables involving continuous data were computed using independent sample t-test. Between-group comparisons involving categorical data were assessed using Fisher's exact test for 2×2 table. Paired sample t test was used for comparison between right and left hemispheres in MA users. Statistical significance was defined at the 0.05 and two-tailed.

RESULTS

Of 15 MA users, 11 and 4 cases were males and females respectively. Mean age (SD, Min-Max) was

42/46 (12.08, 22-65) years old. Mean age of control group was 39.56 (10.10, 25-63) years old. All MA abusers were daily MA consumer and had used MA at morning and before admitting to hospital. Mean dose of MA use was 0.7 gram per day and mean duration of consumption was 4.86 (1-12) years. Inhalation was the route of consumption in all 15 MA users and 3 MA abusers had history of intravenous consumption too. Median daily dose of MA use was 0.71 (range: 0.2-2.5) gram. Their median length of MA consumption was 4.86 (range 1-12) years. All patients had positive urinary test for MA and negative for other illegal substances; all controls had negative results.

In qualitative analysis, all SPECT images in case group were abnormal whereas all images in control group were normal ($p < 0.01$). Of 15 MA abusers, global decreased tracer uptake was observed in 4 patients (26.7%), global decrease uptake except for the cerebellum was detected in 6 cases (40%), and decreased tracer uptake in fronto-temporal lobes was observed in 2 cases (13.3%), decreased uptake only in the temporal lobe in 2 patients (13.3%) and in temporo-occipital lobes in one case (6.7%).

Mean count ratio as well as maximal count ratio of different lobes to cerebellum between MA abusers and normal volunteers were compared. There was significant decreased in mean count ratio in the MA abusers in right parietal and right occipital lobes (both: $p = 0.02$). There was significant decrease in maximal count ratio in the MA abusers in the right parietal ($p = 0.01$) and right superior frontal (0.04) lobes.

In comparison between right and left hemispheres in MA abusers; decreased uptake count in right frontal lobe, superior right frontal lobe and right parietal lobe was detected compared with uptake count in left side in cases group (all three: $p < 0.01$).

In SPM analysis; there was significant difference as well as non-homogeneous tracer uptake throughout all portions of the cortex and cerebellum between MA abusers and normal volunteers (Figure 2).

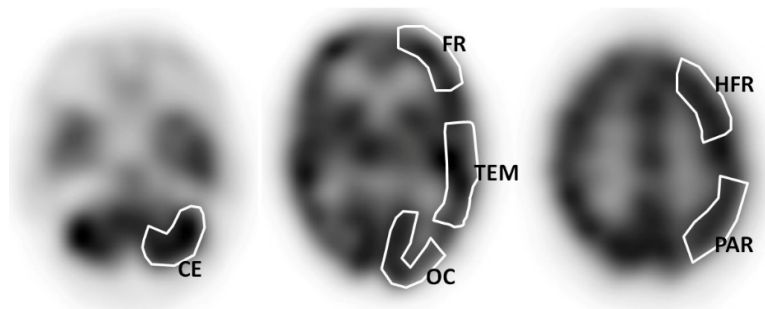


Fig 1. Regions of interest (ROIs) drawn in the different portions of brain perfusion SPECT: Cerebellum (CE); Occipital (OC); Temporal (TEM); Frontal (FR); Parietal (PAR) and High frontal (HFR).

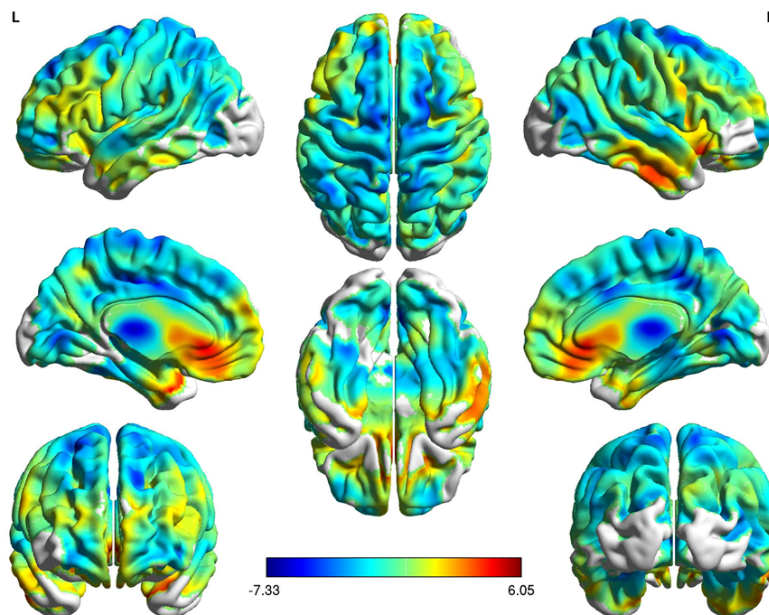


Fig 2. Anatomical localization of significant and nonhomogeneous decreased ^{99m}Tc -ECD SPECT findings in a patient with methamphetamine abuser (3-D images of SPM analysis; level significance of $P < 0.05$).

DISCUSSION

We reported a decrease in rCBF in the different portions of the brain (in all portions of the cortex as well as in the cerebellum) in MA abusers. This decrease in rCBF was prominent in the right cerebral lobes. To the best of our knowledge, there were a few reports about qualitative and quantitative brain perfusion SPECT study in MA users. All MA abusers in our study were without other substance abuse at least in last one year.

Iyo et al. performed a qualitative study of brain perfusion SPECT on 9 MA abuser patients; patchy perfusion deficits in the cerebral cortices were reported in six cases [8].

In another study on 21 patients with amphetamine abuse using visual interpretation of brain perfusion SPECT, normal brain perfusion SPECT was noted in only one patient; multiple perfusion defects of both hemispheres was reported in 71% (15) of patients [9].

Hwang et al studied on changes of relative rCBF in cases of long-term and short term abstinence from MA use. Decreased relative rCBF in the right anterior cingulate cortex (Brodmann area 32) was detected in MA abstinent cases compared to healthy subjects. Greater rCBF in long-term abstinent cases was shown in comparison to short-term abstinent patients as well. The authors reported that rCBF in the anterior cingulate cortex have decreased in abstinent MA users and prolonged abstinent cases had smaller degree of impairment [10].

The mechanism of perfusion deficits in MA abuse is not fully understood [8]. Intracerebral hemorrhage or vasculitis are suggested as complications of amphetamine use [9]. Histological and angiographic investigations in monkeys demonstrated necrotizing angitis, focal infarctions, reversible and irreversible decreases in small cerebral arteries calibre and flow in MA treated cases. Human studies also revealed cerebral vascular changes similar to vasculitis in drug abusers; intracerebral hemorrhage was reported in MA abusers [8]. Segmental luminal irregularities, microaneurysms, vessel outlines indistinctiveness and vessels thrombosis were reported. Amphetamine use may induce small cortical vasoconstriction, hemorrhage and occlusion [9]. In agreement to our study; Kao et al reported multiple areas of decreased tracer uptake in two hemispheres. Small crystals in amphetamine contaminants may also induce embolic phenomena or vasculopathy [9].

Based on previous studies, some of the deficits were irreversible even after a long term MA abstinence [8].

Hwang et al. compared rCBF patterns in alcohol dependent cases who was methamphetamine abstinent- vs. cocaine-abstinent individuals. Global CBF in MA abstinent cases was significantly lower than cases in cocaine abstinence that were in turn, significantly lower than non-alcoholic non-stimulant drug dependent cases. Abnormal perfusion in the posterior superior frontal region was detected in cocaine cases compared to normal; specific regional deficits were not detected in MA patients [10].

Change et al aimed at determining persistent abnormalities in relative rCBF and cognitive function in MA abstinent cases by magnetic resonance imaging perfusion MRI and performing neuropsychological tests. Bilateral decreased relative rCBF was detected in putamen/insular cortices and the right lateral parietal region, but increased relative rCBF bilaterally in the left temporoparietal white matter, the left occipital brain region and the right posterior parietal region. Female MA users showed increased relative rCBF whereas the male MA users had decreased relative rCBF. MA users had slower reactions on several tasks particularly tasks related to working memory. MA abuse can induce persistent physiologic changes of the brain, these changes is associated with slower time of reaction on computerized assessment of cognitive function [11].

A review article about drug induced changes on CBF was performed on 1991 by Mathew et al. Increase or decrease in CBF and cerebral metabolic rate and also vasospasm was reported after high or low dose of IV administration of amphetamine in animal studies. In human investigations, although some studies revealed no global change in CBF after amphetamine administration, increase in CBF in particular in left hemisphere and frontal lobes in an amphetamine addict case after ingestion of drug and significant or non-significant decreased CBF in healthy cases after amphetamine injection were reported. Amphetamine is one of drugs which may induce stroke [12].

It should be mentioned that some changes in the dopamine transporters (DATs) may be seen in MA abusers which could be assessed by ^{99m}Tc-TRODAT-1 SPECT brain images.

CONCLUSION

In this study, we showed that amphetamine can induce diffuse and non-homogeneous disorders of brain perfusion which was more prominent in the right hemisphere.

REFERENCES

1. Volkow ND, Chang L, Wang GJ, Fowler JS, Ding YS, Sedler M, Logan J, Franceschi D, Gatley J, Hitzemann R, Gifford A, Wong C, Pappas N. Low level of brain dopamine D2 receptors in methamphetamine abusers: association with metabolism in the orbitofrontal cortex. *Am J Psychiatry*. 2001 Dec;158(12):2015-21.
2. De-Carolis C, Boyd GA, Mancinelli L, Pagano S, Eramo S. Methamphetamine abuse and "meth mouth" in Europe. *Med Oral Patol Oral Cir Bucal*. 2015 Mar 1;20(2):e205-10.
3. Paulus MP1, Hozack NE, Zauscher BE, Frank L, Brown GG, Braff DL, Schuckit MA. Behavioral and functional neuroimaging evidence for prefrontal dysfunction in methamphetamine-dependent subjects. *Neuropsychopharmacology*. 2002 Jan;26(1):53-63.
4. Cuzen NL, Koopowitz SM, Ferrett HL, Stein DJ, Yurgelun-Todd D. Methamphetamine and cannabis abuse in adolescence: a quasi-experimental study on specific and long-term neurocognitive effects. *BMJ Open*. 2015 Jan 30;5(1):e005833.
5. Chung YA, Peterson BS, Yoon SJ, Cho SN, Chai S, Jeong J, Kim DJ. In vivo evidence for long-term CNS toxicity, associated with chronic binge use of methamphetamine. *Drug Alcohol Depend*. 2010 Sep 1;111(1-2):155-60.
6. Volkow ND, Chang L, Wang GJ, Fowler JS, Leonido-Yee M, Franceschi D, Sedler MJ, Gatley SJ, Hitzemann R, Ding YS, Logan J, Wong C, Miller EN. Association of dopamine transporter reduction with psychomotor impairment in methamphetamine abusers. *Am J Psychiatry*. 2001 Mar;158(3):377-82.
7. Thompson PM, Hayashi KM, Simon SL, Geaga JA, Hong MS, Sui Y, Lee JY, Toga AW, Ling W, London ED. Structural abnormalities in the brains of human subjects who use methamphetamine. *J Neurosci*. 2004 Jun 30;24(26):6028-36.
8. Iyo M, Namba H, Yanagisawa M, Hirai S, Yui N, Fukui S. Abnormal cerebral perfusion in chronic methamphetamine abusers: a study using ^{99m}Tc-HMPAO and SPECT. *Prog Neuropsychopharmacol Biol Psychiatry*. 1997 Jul;21(5):789-96.
9. Kao CH, Wang SJ, Yeh SH. Presentation of regional cerebral blood flow in amphetamine abusers by ^{99m}Tc-HMPAO brain SPECT. *Nucl Med Commun*. 1994 Feb;15(2):94-8.
10. Hwang J, Lyoo IK, Kim SJ, Sung YH, Bae S, Cho SN, Lee HY, Lee DS, Renshaw PF. Decreased cerebral blood flow of the right anterior cingulate cortex in long-term and short-term abstinent methamphetamine users. *Drug Alcohol Depend*. 2006 Apr 28;82(2):177-81.
11. Chang L, Ernst T, Speck O, Patel H, DeSilva M, Leonido-Yee M, Miller EN. Perfusion MRI and computerized cognitive test abnormalities in abstinent methamphetamine users. *Psychiatry Res*. 2002 Jun 15;114(2):65-79.
12. Mathew RJ1, Wilson WH. Substance abuse and cerebral blood flow. *Am J Psychiatry*. 1991 Mar;148(3):292-305.