

False positive lower limb lymphoscintigraphy due to inadvertent intra-vascular injection of the tracer: Importance of tracer re-injection

Ghasemali Divband¹, Hasan Ravari², Gholamhossein Kazemzadeh²,
Hamed Shayegani¹, Somayeh Khosravi¹, Ramin Sadeghi¹

¹ Nuclear Medicine Research Center, Mashhad University of Medical Sciences, Mashhad, Iran

² Vascular Surgery Research Center, Mashhad University of Medical Sciences, Mashhad, Iran

(Received 18 September 2016, Revised 15 December 2016, Accepted 19 December 2016)

ABSTRACT

We presented a 30 year-old woman presented with symmetrical swelling of the lower limbs since 5 years ago with sparing of the feet. She was highly suspicious of having lipoedema and was referred for lower limb lymphoscintigraphy to rule out possible lymphedema. Lymphoscintigraphy images showed asymmetrical injection sites and unusually high liver and spleen uptake. Inguinal nodes was not visualized on the right side. With the suspicion of inadvertent intra-vascular injection, another injection was done on the right side. Repeated imaging showed inguinal nodes with normal uptake. In conclusion, in case of any suspicion of intra-vascular injection of the radiotracer in limb lymphoscintigraphy, re-injection of the tracer can be of especial use to avoid false positive results.

Key words: Lymphoscintigraphy; Lymphedema; Lipoedema; ^{99m}Tc-Phytate; Re-injection

Iran J Nucl Med 2017;25(2):136-138

Published: July, 2017

<http://irjnm.tums.ac.ir>

Corresponding author: Dr Ramin Sadeghi, MD, Nuclear Medicine Research Center, Mashhad University of Medical Sciences, Mashhad, Iran. E-mail: sadeghir@mums.ac.ir

INTRODUCTION

Lymphoscintigraphy is an integral part of lymphatic mapping in oncology [1, 2], and management of patients with limb swelling [3]. In order to get an optimal results, the lymphoscintigraphy technique including patient preparation, injection and imaging, should be performed with high precision. In the current case, we reported one of the possible pitfalls of lymphoscintigraphy imaging for diagnostic work up of lower limb swelling.

CASE REPORT

A 35 year-old woman presented with symmetrical swelling of the lower limbs since 5 years ago with sparing of the feet was referred to our department for lower limb lymphoscintigraphy (Figure 1: right side image). The patient laboratory exams (including BUN, creatinine, and liver function tests) were all normal. Lower limb Doppler ultrasound showed normal blood flow in the arteries and veins of the lower limbs. On physical examination, there was non-pitting edema of the lower limbs and Stemmer's sign was negative bilaterally (Figure 1: left side images). The patient had no family history of leg swelling and reported no underlying disease or taking any medication. The referring physician was suspicious of lipoedema and ordered lower limb lymphoscintigraphy to rule out lymphedema.

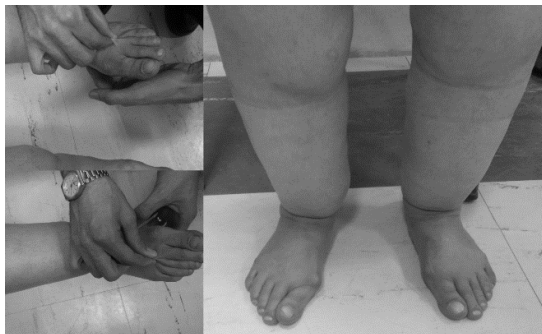

Fig 1. Picture of the lower limbs of the patients (right side). The left side shows bilateral negative Stemmer's sign.

Two equally divided doses (0.5 mCi) of ^{99m}Tc-Phytate were injected in a sub-cutaneous fashion between the first and second interdigital web spaces of both feet. One hour post-injection, whole body lymphoscintigraphy imaging of the patient was done with a dual head gamma camera (ECAM-Siemens) equipped with a low energy high resolution collimators and Tc-99m photopeak and 12 cm/min speed. The scan showed high activity in the liver and spleen, asymmetrical activity of the injection sites (considerably higher on the left side), and no inguinal nodes on the right side (Figure 2).

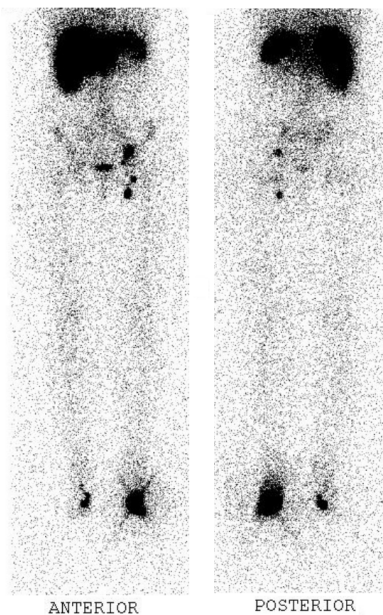


Fig 2. Lymphoscintigraphy of the patient one hour post-injection. Note intense liver uptake as well as low activity of the injection site on the right side. Inguinal lymph nodes on the right side were not visible.

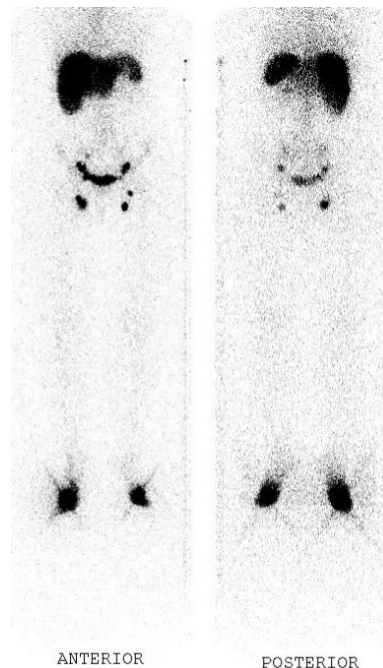


Fig 3. Lymphoscintigraphy of the patient, after re-injection of the tracer on the right side. Note visualization of the inguinal lymph nodes on the right side.

With the suspicion of inadvertent intra-vascular injection of the tracer (due to asymmetrical activity of the injection sites, and very high liver and spleen uptake), another dose of the tracer was injected in the right lower limb and lymphoscintigraphy imaging was repeated 30 minutes later. This time, the inguinal nodes on the right side were visible. Quantitative evaluation of the inguinal to injection site showed 9% and 8.5% of the injection site uptake on the right and left sides respectively (Figure 3).

DISCUSSION

Lymphoscintigraphy is an integral part of lymphedema evaluation and can be very useful for differentiation between lymphedema and other causes of lower limb swelling [3-6]. Several tracers including ^{99m}Tc -Phytate have been used for limb lymphoscintigraphy and sentinel node mapping with excellent results [7-10]. Correct injection of the tracer in the interdigital web space of the limbs is very important in order to have an interpretable lymphoscintigraphy. In our case, inadvertent intra-vascular injection of the radiotracer resulted in asymmetrical activity in the injection sites which is not expected to occur as both sides were injected with same doses of the radiotracer. In addition unusually high uptake in the liver and spleen raised the suspicion of intra-vascular injection. Re-injection of the tracer showed normal inguinal nodes on the right side and a false positive result (lymphedema pattern on lymphoscintigraphy) was prevented.

Successful informative lymphoscintigraphy of the limbs for diagnosis of lymphedema needs careful attention to all aspects of imaging including: radiotracer preparation [11], injection technique (epifacial versus sub-facial injections, dose, location, etc) [12], time of imaging, imaging protocols [3]. Any problem in the phases of imaging mentioned above can result in non-diagnostic lymphoscintigraphy. Our case showed the importance of correct injection in this procedure.

CONCLUSION

In conclusion, in case of any suspicion of intra-vascular injection of the radiotracer in limb lymphoscintigraphy, re-injection of the tracer can be of especial use to avoid false positive results.

REFERENCES

1. Aliakbarian M, Memar B, Jangjoo A, Zakavi SR, Reza Dabbagh Kakhki V, Aryana K, Forghani MN, Sadeghi R. Factors influencing the time of sentinel node visualization in breast cancer patients using intradermal injection of the radiotracer. *Am J Surg.* 2011 Aug;202(2):199-202.
2. Ansari M, Rad MA, Hassanzadeh M, Gholami H, Yousefi Z, Dabbagh VR, Sadeghi R. Sentinel node biopsy in

- endometrial cancer: systematic review and meta-analysis of the literature. *Eur J Gynaecol Oncol.* 2013;34(5):387-401.
3. Sadeghi R, Kazemzadeh G, Keshtgar M. Diagnostic application of lymphoscintigraphy in the management of lymphoedema. *Hell J Nucl Med.* 2010 Jan-Apr;13(1):6-10.
4. Peña Quián Y, Hernández Ramirez P, Batista Cuellar JF, Perera Pintado A, Coca Pérez MA. Lymphoscintigraphy for the assessment of autologous stem cell implantation in chronic lymphedema. *Clin Nucl Med.* 2015 Mar;40(3):217-9.
5. Burnand KM, Glass DM, Mortimer PS, Peters AM. Lymphatic dysfunction in the apparently clinically normal contralateral limbs of patients with unilateral lower limb swelling. *Clin Nucl Med.* 2012 Jan;37(1):9-13.
6. Stollendorf DP, Dietrich MS, Ridner SH. Symptom Frequency, Intensity, and Distress in Patients with Lower Limb Lymphedema. *Lymphat Res Biol.* 2016 Jun;14(2):78-87.
7. Kazemzadeh GH, Sadeghi R, Ebrahimi E, Rad MA. A successful experience in managing a chylous reflux: importance of lymphoscintigraphy. *Clin Nucl Med.* 2014 May;39(5):485-7.
8. Ravari H, Sadri K, Sadeghi R. Growth plate uptake of Tc-99m-phytate on lymphoscintigraphy images. *Lymphat Res Biol.* 2015 Mar;13(1):59-61.
9. Shariati F, Ravari H, Kazemzadeh G, Sadeghi R. Isolated primary lymphedema tarda of the upper limb. *Lymphat Res Biol.* 2013 Mar;11(1):43-5.
10. Dabbagh Kakhki VR, Jangjoo A, Tavassoli A, Asadi M, Sadri K, Fatahi Masoom A, Mehrabibahar M, Memar B, Ansari M, Sadeghi R. Sentinel node mapping for early breast cancer patients using ^{99m}Tc -phytate: Single center experience on 165 patients. *Iran J Nucl Med.* 2012;20(2):25-9.
11. Sadri K, Ayati NK, Shabani G, Zakavi SR, Sadeghi R. Sentinel node detection failure due to defective labeling and large particle size of Tc-99m antimony sulfide colloid. *Iran J Nucl Med.* 2011;19(1):6-11.
12. Szuba A, Shin WS, Strauss HW, Rockson S. The third circulation: radionuclide lymphoscintigraphy in the evaluation of lymphedema. *J Nucl Med.* 2003 Jan;44(1):43-57.