

• ((Special Article)) •

POSITRON TOMOGRAPHY OF BREAST CANCER IN A COMMUNITY HOSPITAL : A CASE STUDY OF ADVANCED DISEASE USING A COINCIDENCE GAMMA CAMERA

Cohen P, Sossi V, Ruth T, Johnson RR, Lyster D, Mankoff D

Lions Gate Hospital, Vancouver BC, Canada and
University of Washington, Seattle, USA

Until recently PET scanning has been available only at major universities or teaching hospitals possessing the necessary resources and expertise to operate a research PET facility. Most dedicated PET centers cost several millions of dollars, and include a cyclotron, a radiochemistry laboratory to synthesize PET radiopharmaceuticals, a multicrystal dedicated PET camera, advanced computer facilities and a staff of many researchers, radiochemists, physicists, computer programmers, physicians and technologists. Because of the extensive staff requirements, operating costs have also been in the millions of dollars, and as a result, Canada has only a handful of PET centers (1-8).

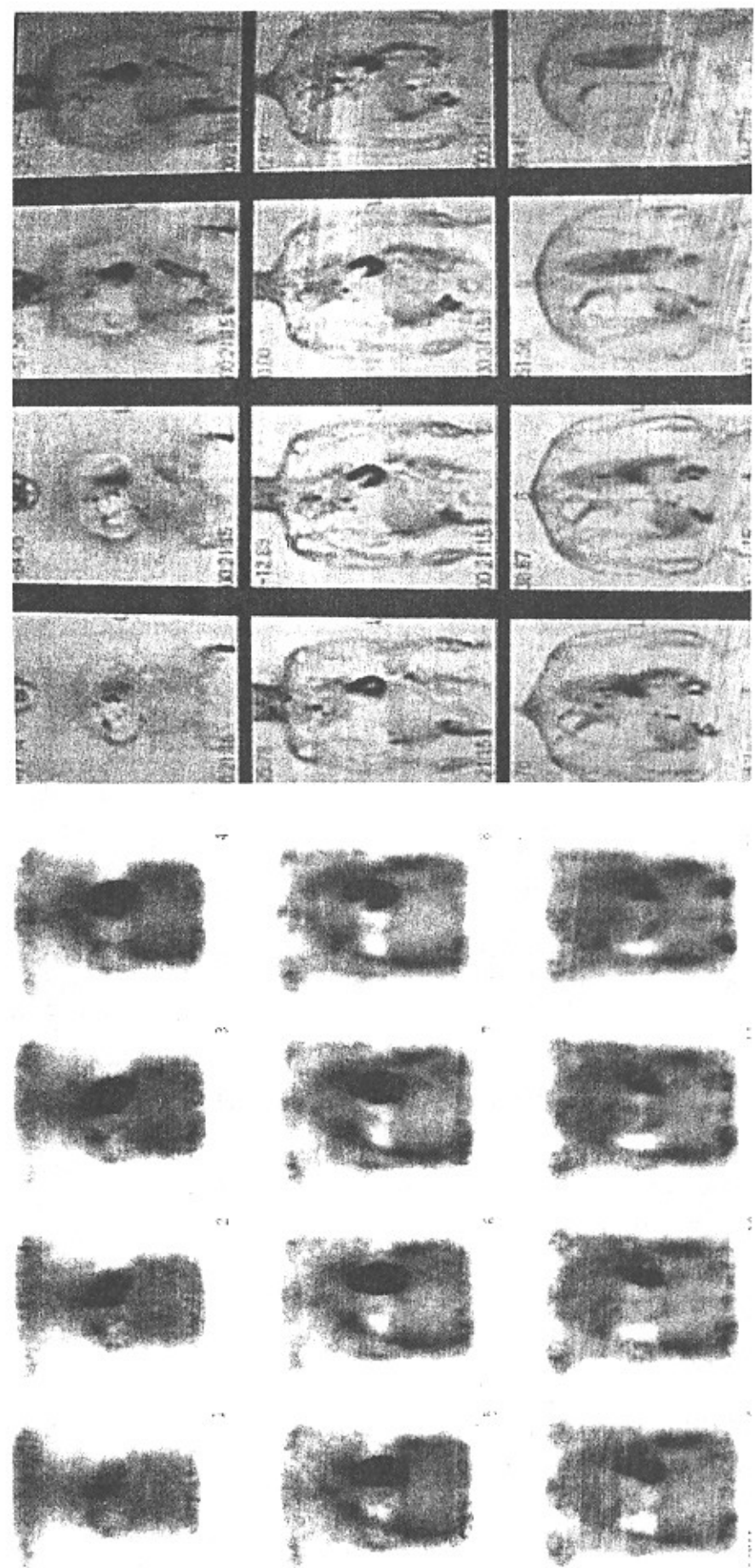
Lions Gate Hospital, a 450 Bed Community hospital located in North Vancouver, British Columbia in September 1997 became the first center in Canada to upgrade a regular dual-head ADAC Vertex SPECT camera to coincidence PET. Canada has relatively few PET centers, with most dedicated to neuroPET, including an active PET group at the University of British Columbia. Only two other Canadian centers currently are able to do oncological studies using dedicated PET cameras. Phantom studies were conducted throughout 1998 at Lions Gate Hospital using Torso and cylindrical phantoms to determine optimal count rates and optimal Noise-Equivalent-Counts (NEC) for the system. Initial patient studies began in early 1998.

Despite lower sensitivities and detection rates

compared to dedicated PET systems, (10-19) several studies conclude the coincidence PET systems are useful clinically, especially in imaging lung tumors (95% sensitivity and 75% specificity)(9-16).

Based on these studies, the US Health Care Financing Agency (HCFA) recommended reimbursement for lung tumor PET imaging with coincidence PET systems, as well as dedicated PET scanners. Other reports, comparing lesion detection on dedicated PET scanners with coincidence scanner (12) have been less enthusiastic, noting that only 57 per cent of neoplastic lesions were seen on coincidence cameras compared to dedicated ring PET systems, with only 32% of mediastinal nodes less than 1.3 cm. detected.

FEMALE AGE 41
METASTATIC BREAST CANCER
LGH ADAC Coincidence **UWash GE Advance Dedicated PET**



Even these authors conclude that current coincidence gamma cameras compare comparatively well with dedicated PET (particularly in the lung, and less well in the abdomen). Initial reports of coincidence camera performance have also been without correction for attenuation, scatter, or random photons (13).

We report on a case study of a 41 year old female with known cancer of the left breast which presented as a lump pain in the left breast area. Initial mamograms and CA 15.3 were negative. the woman underwent mastectomy and local radiation and was symptom-free for a period of 2 years when she again noted pain in the left chest wall. This was thought to be nerve irritation from the radiotherapy, as mamography, serum CA 15.3 and initial CT scans were all negative, when she suddenly developed a pleural effusion. A PET scan done at the University of Washington (Seattle, Washington, USA) on that center's dedicated PET camera (GE Advance), showed multiple metastatic lesions, with spread to the contralateral breast, mediastinum, axillary nodes, and an a large right-sided pleural effusion. A subsequent PET scan was done on the dual-head coincidence PET scanner at Lions Gate Hospital (ADAC MCD) in North Vancouver, and showed similar findings, although there is an obvious decrease in image quality due to the lower count rate and lack of scatter, random, and attenuation correction, most lesions are detected using the ADAC coincidence system. study was obtained using the ADAC MCD camera operating in coincidence mode without collimators, with 40 second data acquisition per stop, requiring roughly 45 minutes to scan the thorax.

The patient's disease was unfortunately refractory to chemotherapy and hormonal therapy, and she died 6 months after the two PET studies were performed.

References

- 1 - Lewellen TK, Miyaoka RS, Kaolan MS, et al. Preliminary investigation of coincidence imaging with a standard dual-headed SPECT system. *J Nucl Med* 1995;36:175P.
- 2 - Muehllehner G, Geagan M, Countryman P. SPECT scanner with PET coincidence capability. *J Nucl Med* 1995;36:70P
- 3 - Muehllehner O, Colsher JO, Lewitt RM. A hexagonal bar positron camera: Problems and solutions. *IEEE, NS* 1993;30:652-660.
- 4 - Mankoff DA, Muehllehner G, Karp JS. The high count rate performance of a two dimensionally positron-sensitive detector for positron emission tomography. *Phys Med Biol.* 1989;34:437-456.
- 5 - Mankoff DA, Muehllehner O, Miles O, A local coincidence triggering system for PET tomographs composed of large-area positron-sensitive detectors. *IEEE-NS.* 1990;37:730-736.
- 6 - Karp JS, Daube-Witherspoon ME, Hoffman EJ, et al: Performance standards in positron emission tomography. *J Nucl Med* 12:2342-2350
- 7 - Muehllehner G, Jines H, Fundamentals of coincidence imaging with dual head Gamma cameras, Society of Nuclear Medicine categorical course Manual 1997;45-49.
- 8 - Baehre M., Meller B, Lauer I, Luig, H. Richter E. PET With A Gamma camera coincidence system: Phantom studies and first clinical results, Abstract J of Nuclear Med Vol 39. No 5 May 1998; 108P
- 9 - Weber W, Young DO, Abdel-Dayem H, Sfakianakis G, Wier G, Shreve P, Swaney C, Gates M, Girardeau MO, Rijk P, Parker A, Valk

- P, Seung A, Caputo G, Sollito R, Hines H, Wagner H, Assessment of Pulmonary Lesions With 18-FDG Positron Imaging Using A Gamma Camera operated in coincidence mode, Abstract J of Nuclear Med, Vol 39.,No 5, May 1998:108P
- 10 - Delbeke D, Sandler MP, Al-Sugair A, Martin WH, Coleman RE, Comparison of FDG in patients with focal pulmonary lesions, Abstract J of Nuclear Med, Vol 39., No 5 May 1998:108P.
- 11 - Abdel-Dayem HM, Bonfils E, Teitgin P, El-Zeftawy HA, Luo J, Naddaf S, Kumar M, Atay S, Degirmenci B. Dual head coincidence imaging (DHCI) of F-18 FDG in primary lung nodules (PLN), Abstract J of Nuclear Med, Vol 39., No5, May 1998:109P.
- 12 - Shreve P, Steveton RS, Deters E, Gross MD, Wahl RL, Lesion detection in oncologic diagnosis: Comparison of dual head coincidence with dedicated PET imaging, Abstract J of Nuclear Med, Vol 39., No 5, May 1998:108P.
- 13 - Al-Sugaie A, Hamblen SM, Laymon CE, Turkington TG, Coleman RE, Lesion detection using nonattenuation corrected dedicated and camera-based PET compared with attenuation corrected dedicated PET, Abstract J of Nuclear Med, Vol 39., No 5, May 1998:108P.
- 14 - Sossi V, Krzywinski M, Cohen P, Knitzek K, Hudkins K, Rosario J De, Morrison KS, Jivan S, Johnson RR, Ruth TJ, UBC/TRIUMF performance of the ADAC MCD dual head coincidence camera, Abstract J of Nuclear Med Vol 39. No 5, May 1998:173P.
- 15 - Sossi V, Kryzwinski M, Cohen P, Mankoff DA, Rosario J De, Ruth TJ, Effect of count-rate on contrast in a dual head coincidence camera, 1998 IEEE/MIC meeting Nov 1998, Toronto Canada.
- 16 - Budinger TF, PET Instrumentation: What are the limits? Seminars in Nuclear Medicine, Vol XXVII, No3 July 1998 pp 274-267.
- 17 - Freifelder R, Karp JS, Surti S, Wear JA, A detectors, Abstract J of Nuclear Med, Vol 39., No 5, May 1998:171P.
- 18 - Murthy K, Thompson CJ, Bergman AM, Robar JL, Lisboa R, Loutfi A, Gagnon JH, 18F-FDG PEM: prliminary clinical evaluation of a metabolic imaging system dedicated to the early detection of breast carcinoma, Abstract J of Nuclear Med, Vol 39., No 5, May 1998:146P.
- 19 - Shreve P, Steventon RS, Gross M, Diagnosis of spine metastasis by FDG imaging using a gamma camera in coincidence mode, Clinical Nuclear Medicine Vol 23, No 12. pp 799-802.