

Detection of solitary bone metastasis by ^{99m}Tc -octreotide scintigraphy in a patient with Hurthle cell carcinoma: A case report

Parinaz Jahanpanah, Sara Shakeri, Zahra Kiamanesh, Zakie Nasiri, Kamran Aryana

Nuclear Medicine Research Center, Mashhad University of Medical Sciences, Mashhad, Iran

(Received 18 March 2019, Revised 23 July 2019, Accepted 24 July 2019)

ABSTRACT

A 75-year-old male patient with non-avid radioiodine Hurthle cell carcinoma was evaluated by ^{99m}Tc - octreotide scintigraphy, in order to find possible metastatic lesions. A bony metastatic lesion was detected by this procedure which was confirmed by histopathology. ^{99m}Tc -octreotide scintigraphy is a precise and cost-effective imaging modality for detection of non-iodine avid lesions in metastatic differentiated thyroid carcinomas.

Key words: Hurthle cell carcinoma; ^{99m}Tc -octreotide scintigraphy; Negative whole body iodine scan; Thyroid cancer; Elevated Tg level

Iran J Nucl Med 2020;28(1):48-50

Published: January, 2020

<http://irjnm.tums.ac.ir>

Corresponding author: Dr. Kamran Aryana, Nuclear Medicine Research Center, Mashhad University of Medical Sciences, Mashhad, Iran. E-mail: aryanak@mums.ac.ir

CASE PRESENTATION

A 75-year-old male patient with a history of non-avid radioiodine Hurthle cell carcinoma and unexplained elevated thyroglobulin (Tg=14 ng/ml) was referred for investigation of possible metastatic involvement by ^{99m}Tc-octreotide scintigraphy. Since the neck sonography and whole-body iodine scan were negative and the patient could not afford the cost of ¹⁸F-FDG PET/CT, ^{99m}Tc-octreotide scintigraphy was an alternative option for investigating possible metastatic lesions.

Four hours after IV administration of 740 MBq (20 mCi) of ^{99m}Tc- octreotide, whole body scan was performed using a dual-head E-CAM, SPECT camera equipped with low-energy and high-resolution collimator. Hybrid SPECT/CT acquisition was performed from the pelvic region, with SPECT parameters of 128×128 matrices, 64 projections over 360°, and 20 seconds per step, and CT parameters of 5.0-mm slice thickness with a 2.5-mm collimation for attenuation correction. Reconstruction of SPECT/CT images was done with iterative method (OSEM, number of iterations 8, subsets 4). The whole body delayed images after 4 hours in planar view revealed a focal zone of increased tracer uptake in the posterior portion of the pelvis (Figure 1), which was confined to the left iliac ala in SPECT/CT acquisition (Figure 2).

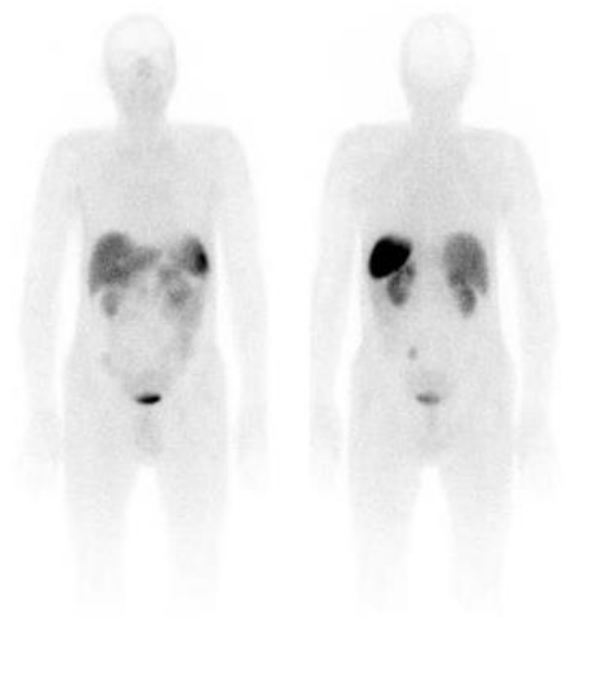


Fig1. ^{99m}Tc-octreotide scintigraphy in planar view revealed a focal zone of increased tracer uptake in the posterior portion of the pelvis.

The radiologic correlation was recommended for further evaluation. Pelvic transaxial MRI also showed a low T1 weighted signal (Figure 3A) and high T2

weighted signal (Figure 3B) lesion in the left iliac ala next to the sacroiliac joint with adjacent bone marrow edema. Excisional biopsy of the sacroiliac joint was compatible with metastatic Hurthle cell carcinoma. The patient refused to perform the excisional surgery and is being followed by Tg level measurements and has been stable in this setting.

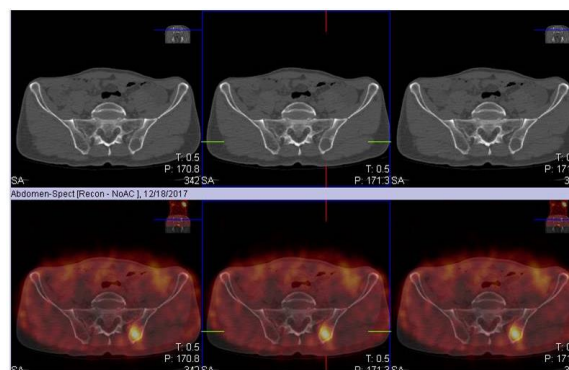


Fig 2. SPECT/CT acquisition confined the tracer uptake to the left iliac ala.

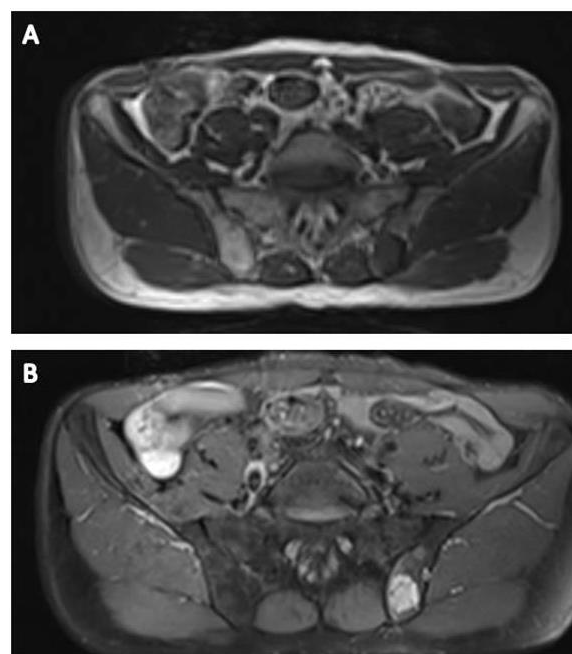


Figure3. Pelvic transaxial MRI showed a low T1 weighted signal (A) and high T2 weighted signal (B) lesion in the left iliac ala next to the sacroiliac joint with adjacent bone marrow edema.

DISCUSSION

Some differentiated thyroid cancer (DTC) variants may fail to concentrate iodine [1-4], therefore accompanied by negative ¹³¹I-WBS [5]. Despite the high sensitivity of FDG PET/CT imaging in detecting residual malignant foci [4, 6], SPECT-imaging is more

cost-effective, widely available, simpler procedure with lower radiation dose and acceptable accuracy [5]. The uptake of somatostatin analogs can be visualized in patients with DTC and elevated serum Tg levels, that was helpful for finding metastatic sites [7]. The expression of Somatostatin analogs is due to the presence of these receptors on follicular cells of the majority of DTC patients, as proved by Baudin et al [8]. It seems that the Somatostatin receptor (SSTR) imaging can play an important role in the management of DTC patients with evidence of non-iodine avid metastasis [5]. Czepczyński et al. revealed that despite of good sensitivity and specificity of SSSTR imaging in DTC patients, it is not high enough to be recommended as a routine modality instead, should be considered as a complementary diagnostic imaging method [9]. Many iodine negative metastatic DTC lesions express SSSTRs and octreotide therapy can change the biological activity of these kinds of lesions [10]. So, another major advantage of somatostatin receptor imaging in patients with multiple avid metastatic lesions would be patient selection for targeted therapy with radiolabeled somatostatin analogs.

In conclusion, although ^{99m}Tc-octreotide scintigraphy is not the first choice for evaluation of metastatic thyroid cancer, it is a sensitive and cost-effective complementary imaging modality for detection of non-iodine avid lesions in metastatic differentiated thyroid carcinomas.

REFERENCES

1. Lowe VJ, Mullan BP, Hay ID, McIver B, Kasperbauer JL. 18F-FDG PET of patients with Hürthle cell carcinoma. *J Nucl Med.* 2003 Sep;44(9):1402-6.
2. Zhang H, Zeng L, Liang C, Qiu H, Zhang M, Zhu Y, Xie C. Successful treatment of Hurthle cell thyroid carcinoma with lung and liver metastasis using docetaxel and cisplatin. *Jpn J Clin Oncol.* 2012 Nov;42(11):1086-90.
3. Khan S, Sharibi A, Neff R, Grace W, Young IS. Metastatic Hürthle cell carcinoma: a unique case report and review of the literature. *Endocr Pract.* 2005 Jul-Aug;11(4):285-9.
4. Pryma DA, Schöder H, Gönen M, Robbins RJ, Larson SM, Yeung HW. Diagnostic accuracy and prognostic value of 18F-FDG PET in Hürthle cell thyroid cancer patients. *J Nucl Med.* 2006 Aug;47(8):1260-6.
5. Shinto AS, Kamaleshwaran K, Mallia M, Korde A, Samuel G, Banerjee S, Velayutham P, Damodharan S, Sairam M. Utility of ^{99m}Tc-Hynic-TOC in 131I whole-body scan negative thyroid cancer patients with elevated serum thyroglobulin levels. *World J Nucl Med.* 2015;14(2):101-108.
6. Feine U, Lietzenmayer R, Hanke JP, Held J, Wöhrle H, Müller-Schauenburg W. Fluorine-18-FDG and iodine-131-iodide uptake in thyroid cancer. *J Nucl Med.* 1996 Sep;37(9):1468-72.
7. Haslinghuis LM, Krenning EP, De Herder WW, Reijs AE, Kwekkeboom DJ. Somatostatin receptor scintigraphy in the

follow-up of patients with differentiated thyroid cancer. *J Endocrinol Invest.* 2001 Jun;24(6):415-22.

8. Baudin E, Schlumberger M, Lumbroso J, Travagli JP, Caillou B, Parmentier C. Octreotide scintigraphy in patients with differentiated thyroid carcinoma: contribution for patients with negative radioiodine scan. *J Clin Endocrinol Metab.* 1996 Jul;81(7):2541-4.
9. Czepczyński R, Gryczyńska M, Ruchała M. ^{99m}Tc-EDDA/HYNIC-TOC in the diagnosis of differentiated thyroid carcinoma refractory to radioiodine treatment. *Nucl Med Rev Cent East Eur.* 2016;19(2):67-73.
10. Robbins RJ, Hill RH, Wang W, Macapinlac HH, Larson SM. Inhibition of metabolic activity in papillary thyroid carcinoma by a somatostatin analogue. *Thyroid.* 2000 Feb;10(2):177-83.