



CASE REPORT

Dangle-shaped gallbladder extended to the pelvic cavity in a [^{99m}Tc]Tc-MDP SPECT/CT bone scan

Mahdi Haghighatafshar

Department of Nuclear Medicine, School of Medicine, Shiraz University of Medical Sciences, Shiraz, Iran

ARTICLE INFO

Article History:

Received: 04 July 2023

Revised: 25 October 2023

Accepted: 30 October 2023

Published Online: 19 December 2023

Keyword:

Artifacts

Altered distribution

Non-osseous uptake

Gallbladder

Chemotherapy

ABSTRACT

A bone scan was performed on a 69-year-old man with small cell lung carcinoma (limited stage) following 2nd course of adjuvant chemotherapy using etoposide and cisplatin demonstrating extra-osseous tracer accumulation in the right lower abdominal cavity originally thought to be in the ascending colon, was proven to be an ectopically located gallbladder extending to the right lower quadrant (RLQ). Otherwise, the bone scan did not show abnormal skeletal uptake. The precise reason for gallbladder excretion of [^{99m}Tc]Tc-MDP derivatives is unknown. None of the other patients injected with the same [^{99m}Tc]Tc-MDP kit demonstrated any gallbladder or other abnormal soft tissue tracer accumulation. In the interpretation of non-osseous uptakes in the right abdominal cavity, ectopic and/or abnormal shaped gallbladder should be taken into consideration.

*Corresponding Author:

Dr. Mahdi Haghighatafshar

Address: Department of Nuclear Medicine,

School of Medicine, Shiraz University of

Medical Sciences, Shiraz, Iran

Email: afsharm@sums.ac.ir

Use your device to scan and read the article online



How to cite this article: Haghighatafshar M. Dangle-shaped gallbladder extended to the pelvic cavity in a [^{99m}Tc]Tc-MDP SPECT/CT bone scan. Iran J Nucl Med. 2024;32(1):96-98.



<https://doi.org/10.22034/IRJNM.2023.129305.1564>

INTRODUCTION

Considerable number of reports has been published about soft tissue absorption in bone scintigraphy. This finding can occur due to artifacts or known pathophysiological causes such as metastatic calcifications, metabolic processes, or extravascular accumulation of radiopharmaceuticals [1]. The first step after soft tissue detection of radiotracer in a bone scan is to evaluate the quality control parameters of the [^{99m}Tc]Tc-MDP kit, which may be responsible for the abnormal findings. If there were no problems in the quality control of the [^{99m}Tc]Tc-MDP kit, biodistribution changes should be investigated, which can occur in various conditions. In this case, the bone scan revealed localization of [^{99m}Tc]Tc-MDP in the gallbladder that initially assumed to be

in the ascending colon. The precise reason for gallbladder excretion of [^{99m}Tc]Tc-MDP derivatives is unknown.

CASE PRESENTATION

A 69-year-old man with small cell lung carcinoma was started on adjuvant chemotherapy using etoposide and cisplatin. After 2 courses of chemotherapy, he was referred for a whole body bone scan. The study was performed following i.v. injection of 20 mCi of [^{99m}Tc]Tc-MDP. The bone scan did not show any abnormal skeletal uptakes. Surprisingly an area of diffuse extra osseous uptake was noted in the RLQ which initially was interpreted as radiotracer accumulation in the ascending colon (Figure 1).

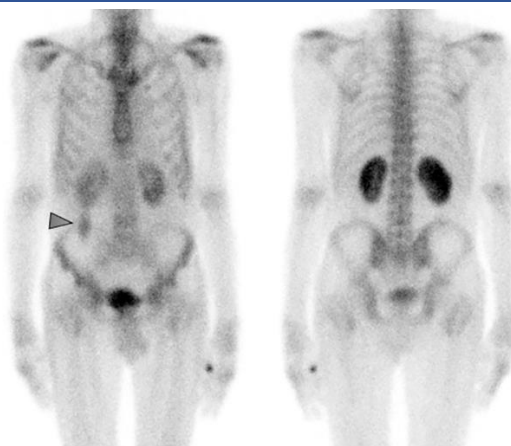


Figure 1. The 3h delayed anterior and posterior view of the whole body bone scan revealed diffuse uptake in the RLQ (arrow)

For better characterization and localization of this finding, SPECT/CT imaging was done (Figure 2). Fused SPECT/CT images revealed diffuse and uniform accumulation of radiotracer within the dangle-shaped gallbladder (green arrow) extended to the pelvic cavity (yellow arrow).

Quality control of radiopharmaceutical didn't show any impurity. All the other patients who have received MDP doses from the same vial with the same badge number, demonstrated normal distribution of the bone seeking agent throughout the skeletal system.

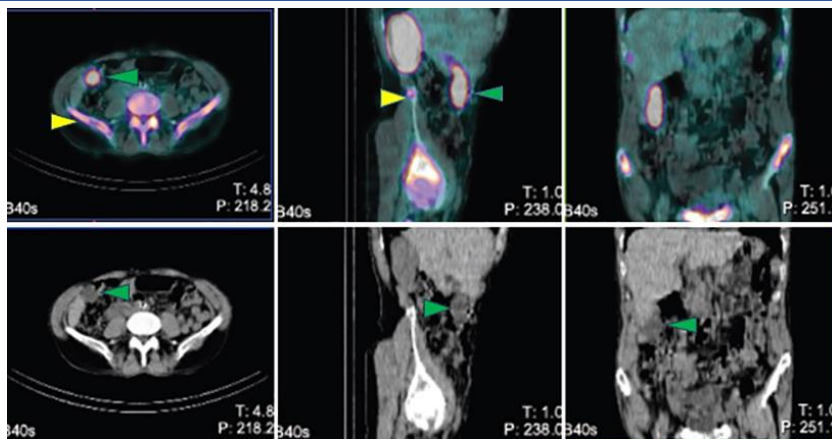


Figure 2. Fused SPECT/CT images revealed homogenous and diffuse accumulation within the dangle-shaped gallbladder (green arrow) extended to the pelvic cavity (yellow arrow)

DISCUSSION

Several metabolic pathways for the accumulation of [^{99m}Tc]Tc-MDP are suggested [2-4]. In view of abdominal sonography and CT images not showing any inflamed and/or calcified gallbladder wall or liver metastasis. Gallbladder excretion of [^{99m}Tc]Tc-MDP is rare and has an unknown mechanism [5-7]. Liver metastasis and increased interstitial pressure has been suggested as a mechanism by some studies. This was not clearly the case in our patient with no evidence of liver metastasis. We assume that iatrogenic alteration of radiotracer by chemotherapeutic drugs is most likely responsible for gallbladder excretion of [^{99m}Tc]Tc-MDP [5]. In the interpretation of soft tissue uptakes in the right abdominal cavity, possibility of an ectopic and/or abnormal shape of the gallbladder as described in our case need to be thoroughly evaluated.

This case has been approved by the Ethics Committee (IR.SUMS.MED.REC.1401.502) and the Institutional Review Board of Shiraz University of Medical Sciences (No.27551) and informed consent forms were signed by the patient.

CONCLUSION

In the interpretation of non-osseous uptakes of the bone seeking agent in the right abdominal cavity, possibility of ectopic and/or abnormal shape of the gallbladder should be taken into consideration.

REFERENCES

1. Eftekhari M, FARD EA, Haghghatafshar M, Keivan A, Beiki D, Aghahosseini F, EMAMI AA, Saghari M. Bone scan with incidental visualization of the entire colon. *Iran J Nucl Med.* 2010;18(2):56-9.
2. Bhatnagar P, Chakraborti KL, Sachdev P, Sawroop K, Bhatnagar A, Kashyap R. Serendipitous gallbladder uptake in a bone scan. *Clin Nucl Med.* 2005 Jul;30(7):512-3.
3. Loutfi I, Collier BD, Mohammed AM. Nonosseous abnormalities on bone scans. *J Nucl Med Technol.* 2003;31:149-53.
4. Zuckier LS, Freeman LM. Nonosseous, nonurologic uptake on bone scintigraphy: atlas and analysis. *Semin Nucl Med.* 2010;40:242-56.
5. Bozzetto J, Lancelot S, Giammarile F. Chemotherapy-related gallbladder visualization in a 99mTc-HMDP SPECT/CT bone scan. *Clin Nucl Med.* 2013;38:829-31.
6. Vallabhajosula S, Killeen RP, Osborne JR. Altered biodistribution of radiopharmaceuticals: role of radiochemical/pharmaceutical purity, physiological, and pharmacologic factors. *Semin Nucl Med.* 2010;40:220-41.
7. Hassan FU, Nathan M, Gnanasegaran G, Fogelman I. Soft tissue uptake in radionuclide bone scintigraphy. In: Fogelman I, Gnanasegaran G, van der Wall H. Editors. *Radionuclide and Hybrid Bone Imaging.* Springer, Berlin, Heidelberg. 2012. pp. 409-32.