

## **[<sup>99m</sup>Tc-DMSA (V)] in Detection of Metastases of Medullary Thyroid Carcinoma**

**Shahram Dabiri, MD**

*Department of Nuclear Medicine, Tabriz University of Medical Sciences, Tabriz, IRAN*

**(Received 24 June 2006, Revised 23 July 2006, Accepted 14 November 2006)**

### **ABSTRACT**

**Introduction:** Medullary thyroid carcinoma (MTC) is a rare thyroid cancer secreting calcitonin (CT) which is the most sensitive and specific tumor marker for MTC. This type of thyroid cancer is able to metastasize to different body areas including regional lymph nodes, lungs, liver and bone. The aim of this study was to assess the sensitivity and specificity of [<sup>99m</sup>Tc-DMSA (V)] whole body scan (WBS) in detection of metastases in MTC.

**Methods:** This descriptive and prospective study was performed in 15 patients with MTC referred to our nuclear medicine centre since 2004 to 2005. These patients were compared regarding age, sex, and duration of the disease. Sensitivity and specificity of each diagnostic modality in detection of metastases were calculated and compared statistically.

**Results:** [<sup>99m</sup>Tc-DMSA (V)] showed 91% sensitivity and 75% specificity as compared with serum calcitonin as gold standard. The figures for CT scan were 82% and 45%, respectively. CEA showed 64% sensitivity and 50% specificity.

**Conclusion:** It is concluded that despite the slightly lower sensitivity and specificity of [<sup>99m</sup>Tc-DMSA (V)] as compared to calcitonin (Gold-standard method), this radiotracer can be used for identification of recurrence or metastasis of medullary thyroid carcinoma.

**Key words:** Medullary thyroid carcinoma, [<sup>99m</sup>Tc-DMSA (V)], Metastasis.

**Iran J Nucl Med 2006; 14(26): 15-24**

**Corresponding Author:** Shahram Dabiri MD, Department of Nuclear Medicine, Tabriz University of Medical Sciences, Tabriz, Iran, E-mail: sh\_dabiri@yahoo.com

## INTRODUCTION

Thyroid cancers are classified as papillary, follicular (including Hürthle cell), medullary, and anaplastic. Medullary thyroid carcinoma (MTC) constitutes about 3-10% of all thyroid cancers (1).

MTC may be sporadic (75%) or may occur on a hereditary (25%) basis (2, 3). Hereditary MTC can occur either alone [familial MTC (FMTC)] or as the thyroid manifestation of multiple endocrine neoplasia type 2 (MEN 2) syndromes (MEN 2A and MEN 2B) or other forms (4, 5).

MTC originates in the parafollicular cells (C cells) of the thyroid, secreting both calcitonin and carcinoembryonic antigen (CEA) (6). Calcitonin (CT) is the most sensitive and specific tumor marker in the preoperative diagnosis of nodular thyroid diseases (7-9) and in the follow-up treatment of MTC (10). For the diagnosis of tumor recurrence in MTC patients, the postoperative CT determination is of central importance (11). CT values decreasing into the normal range are regarded as evidence of complete tumor extirpation, also called biochemical cure (12, 13).

The early detection of all tumor sites in patients with MTC before primary surgery is important, because MTC tends to metastasize to regional lymph nodes of the neck and mediastinum early during the course of the disease (14). The major sites of distant metastasis of this tumor are lung, liver and bone (15). Early stage (T1N0) MTC is associated with a very good prognosis. Postoperative external radiation therapy can achieve good locoregional control in patients with lymph node metastasis or locally advanced disease (16).

Surgery is the only successful treatment for MTC, as there is no effective adjuvant therapy for residual disease. A total thyroidectomy and vigilant management and surveillance of the neck are recommended. Interdisciplinary management including surgeons, endocrinologists, pathologists, radiotherapists, radiologists, and oncologists should be considered (1).

Patients who undergo thyroidectomy for MTC often have elevations of postoperative serum calcitonin levels, which are indicative of

metastatic or residual disease. It has been extremely difficult to localize tumor in these patients with standard diagnostic studies such as ultrasonography, computed tomography, or magnetic resonance imaging scans (17). Detection of recurrence from MTC remains a diagnostic problem, especially when increased serum tumor marker levels suggest recurrence and conventional imaging techniques are non-diagnostic (18).

The 10-year survival rate for MTC is 50%; thus, good tumor-seeking radiopharmaceuticals are needed to localize foci of recurrence and metastasis during follow-up. Numerous radiocompounds are currently being used to detect local and distant recurrences of MTC, including <sup>201</sup>Tl, <sup>131</sup>I-MIBG, [<sup>99m</sup>Tc-DMSA (V)], and <sup>99m</sup>Tc-MIBI (19). Pentavalent technetium-99m dimercaptosuccinic acid [<sup>99m</sup>Tc-DMSA (V)] has been shown to be taken up by the primary and recurrent tumor, along with its metastasis, with sensitivity variably reported as 65 to 88% (15).

In patients with MTC (a) [<sup>99m</sup>Tc-DMSA (V)] imaging of the thyroid demonstrates an area of reduced uptake corresponding to the site of the nodule that is solid on ultrasound. (b) liver-spleen scans demonstrate areas of reduced tracer uptake in the sites of metastasis and (c) bone metastasis are picked up as areas of increased tracer uptake on bone scan. However, all these findings are non-specific as other pathological states can give rise to such scan findings (15).

[<sup>99m</sup>Tc-DMSA (V)] is selectively taken up into sites of primary, recurrent and metastatic medullary carcinoma of the thyroid. Due to its remarkably low, non-specific uptake in organs such as the liver and bone marrow, identification of liver and bone metastases is facilitated (19). This greatly increases the specificity of the diagnosis of medullary carcinoma of thyroid in suspected primary, recurrent and metastatic sites. Thus this imaging agent is now contributing significantly to patient management with its ability to define both local soft tissue recurrence and distant metastasis (15).

In this study we assessed sensitivity and specificity of [<sup>99m</sup>Tc-DMSA (V)] compared with the results of CT scan, and CEA levels. Calcitonin was the gold-standard method.

## METHODS

This survey was a prospective descriptive-analytic study. 15 patients with medullary thyroid carcinoma (MTC) which their diagnosis had been confirmed by pathologic examination after thyroidectomy since early of Jan 2004 to late of December 2005 were selected. The small number of cases was due the fact that MTC is a rare condition.

All of the patients referred to our nuclear medicine center for [<sup>99m</sup>Tc-DMSA (V)] whole body scanning (WBS).

WBS in anterior and posterior views was performed 2 hours following injection of 4 mCi of this radiotracer. The areas of enhanced local absorption were indicative of metastasis. Because a single imaging modality is not sufficient for diagnosis of metastases, neck and chest CT scans were performed and serum calcitonin and CEA was measured. So, the accuracy of any of mentioned methods for diagnosis of various metastases (e.g. cervical lymph nodes, mediastinal, pulmonary and hepatic metastases) were determined. Also, the combinations of several methods in diagnosis of MTC were compared.

Regarding the radiation absorption by the patients, an informed consent signed by all of them. By definition, the serum calcitonin levels of > 1000 pg/ml were considered as indicative of confirmed metastasis (7). The sensitivity and specificity of all of imaging modalities and also serum calcitonin and CEA levels in diagnosis of metastasis were calculated.

Then, the collected data was analyzed by SPSS statistical software, using Mann-Whitney and Chi-square tests. The values of  $\leq 0.05$  were considered statistically significant.

## RESULTS

The patients had average age of  $40 \pm 11.8$  years with range of 17-68 years and frequent age of 37 years (13.3 %). The average duration of the disease (MTC) was  $4.3 \pm 2.4$  years with range of 2-5 years.

8 cases (53.3%) had right-sided tumor and 7 cases (46.7%) had left-sided involvement.

According to the Table 1 there was not significant difference between two sex groups regarding age (PV=0.388) and duration of disease (PV=0.689). According to the Table 2, the difference between calcitonin-positive and calcitonin-negative groups, about age (PV=0.104), duration of disease (PV=0.661), the number of positive CT scan (PV=0.28), was not significant but regarding the number of positive [<sup>99m</sup>Tc-DMSA (V)] scan, the difference was significant (PV=0.04).

**Table 1:** Age, sex, and duration of disease between patients

variable	Male	female
Number (%)	6(40%)	9(60%)
Age average (years)	42.6 $\pm$ 6.1	38.3 $\pm$ 14.6
Average duration of the disease (years)	4	4.4

**Table 2:** The comparison of patients' variables regarding the calcitonin levels

	Normal calcitonin	Elevated calcitonin
Number (%)	4(26.7%)	11(73.3%)
Age average (years)	45.5 $\pm$ 5.4	38.1 $\pm$ 4.5
Age range (years)	40-53	17-68
Duration of the disease (years)	3.7 $\pm$ 2	4.5 $\pm$ 2.67
Male number (%)	3(75%)	3(27.3%)
The frequent age (Number)	-	37 (2 cases)
Right/Left sided disease	2(50%)/2(50%)	6(54.5%)/5(45.5%)
↑ CEA	2(50%)	7(81.8%)
Positive CT scan	1(25%)	9(81.8%)
Positive DMSA scan	1(25%)	10(90.9%)

The difference between CEA-normal and CEA-high groups (Table 3) about age (PV=0.776), duration of disease (PV=1), the number of positive CT scan (PV=0.689), and the number of positive [<sup>99m</sup>Tc-DMSA (V)] scan (PV=0.181) was not significant.

The difference between two sex groups regarding the number of positive CT scan (PV=0.689) and the number of positive [<sup>99m</sup>Tc-DMSA (V)] scan (PV= 0.181) was not significant (Table 4, Table 5).

The specificity and sensitivity of calcitonin test was 100% and the relation between the high calcitonin levels (>1000pg/ml) and metastasis

was significant (PV=0.001) but according to the Table 6, there was not significant relation between metastasis and high CEA (PV=0.538). The sensitivity and specificity of this test were 63.6% and 50% respectively.

**Table 3:** The comparison of patients' variables regarding the CEA levels

	Normal CEA	Elevated CEA
Number (%)	6(40%)	9(60%)
Age average (years)	40±18.3	40.1±6
Age range (years)	17-68	30-49
Duration of the disease (years)	4.3±2.7	4.2±2.4
Male number (%)	2(33.3%)	4(44.4%)
The frequent age (Number)	-	37 (2 cases)
Right/Left sided disease	3(50%)/2(50%)	5(55.6%)/4(44.4%)
↑ Calcitonin	4(66.7%)	7(77.8%)
Positive CT scan	3(50%)	?(? %)
Positive DMSA scan	5(83.3%)	6(66.7%)

**Table 4:** The comparison of patients' variables regarding the [<sup>99m</sup>Tc-DMSA (V)] results

	Negative DMSA	Positive DMSA
Number (%)	4(26.7%)	11(73.3%)
Age average (years)	46±4.8	37.9±13
Age range (years)	42-53	17-68
Duration of the disease (years)	5.7±2.3	3.7±2.4
Male number (%)	3(75%)	3(27.3%)
The frequent age (Number)	-	37 (2 cases)
Right/Left sided disease	1(25%)/3(75%)	7(63.6%)/4(36.4%)
↑ Calcitonin	1(25%)	10(90.9%)
Positive CT scan	1(25%)	9(81.8%)
↑ CEA	3(75%)	6(54.5%)

The relation between metastasis and [<sup>99m</sup>Tc-DMSA (V)] scan was significant (PV=0.033). The sensitivity and specificity of this test were 90.9% and 75% respectively. There was not significant relation between CT scan result and metastasis (PV=0.077). The sensitivity and specificity of this test was 81.8% and 75% respectively.

When CEA is positive, the consistency ratio in detection of true positive and true negative [<sup>99m</sup>Tc-DMSA (V)] cases is 85.7% and 100%

respectively; also, the consistency ratio in detection of true positive and true negative CT results is 85.7% and 50% respectively (Table 7).

**Table 5:** The comparison of patients' variables regarding the CT scan results

	Negative CT	Positive CT
Number (%)	5(23.3%)	10(66.7%)
Age average (years)	41.2±9.3	39.5±13.3
Age range (years)	27-53	17-68
Duration of the disease (years)	4.4±3.2	4.2±2.1
Male number (%)	4(80%)	2(20%)
The frequent age (Number)	-	37 (2 cases)
Right/Left sided disease	2(40%)/3(60%)	6(60%)/4(40%)
↑ Calcitonin	2(40%)	9(90%)
Positive DMSA	2(40%)	9(90%)
↑ CEA	2(40%)	7(70%)

**Table 6:** The distribution of patients regarding the results of each diagnostic modality and presence or absence of metastasis

Metastasis		+	-
CEA	↑	7(46.7%)	2(13.3%)
	N	4(26.7%)	2(13.3%)
DMSA	+	10(66.7%)	1(6.7%)
	-	1(6.7%)	3(20%)
CT scan	+	9(60%)	1(6.7%)
	-	2(13.3%)	3(20%)

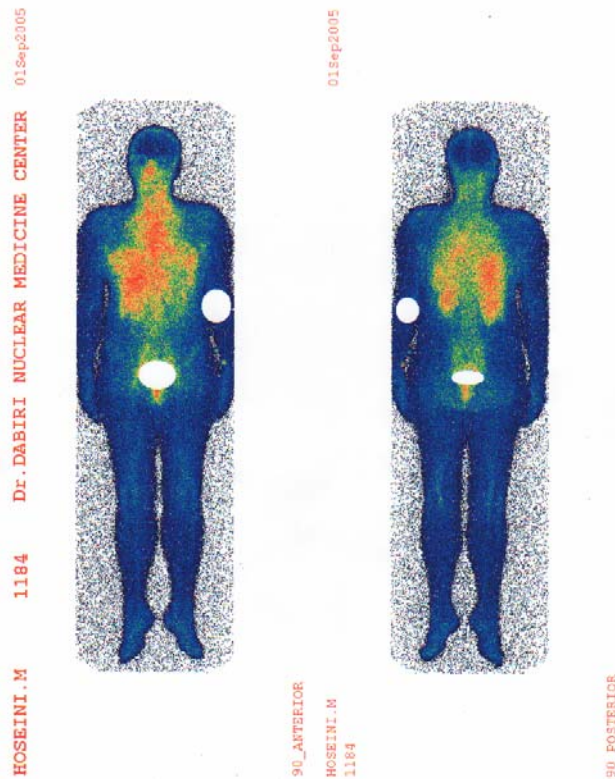
When the CEA is normal, the consistency ratio in detection of true positive and true negative [<sup>99m</sup>Tc-DMSA (V)] cases is 100% and 50% respectively; also, the consistency ratio in detection of true positive and true negative CT results is 75% and 100% respectively (Table 7). When the [<sup>99m</sup>Tc-DMSA (V)] is positive, the consistency ratio in detection of true positive and true negative CEA cases is 100% and 50% respectively; also, the consistency ratio in detection of true positive and true negative CT results is 90% and 100% respectively (Table 7). When the [<sup>99m</sup>Tc-DMSA (V)] is negative, the consistency ratio in detection of true positive and true negative CEA cases is 100% and 33.3% respectively; also, the consistency ratio in detection of true positive and true negative CT results is 0% and 66.7% respectively (Table 7). When the CT results is positive, the consistency ratio in detection of true positive and true negative CEA cases is 66.7% and 0%

respectively; also, When the CT results is negative, the consistency ratio in detection of

true positive and true negative CEA results is 50% and 66.7% respectively (Table 7).

**Table 7:** The distribution of patients with considering the results of the combinations of two diagnostic modalities

Metastasis		+	-			+	-
CEA (↑)	DMSA (+)	6(66.7%)	0	CT scan (+)	6(66.7%)	0	
	DMSA (-)	1(11.1%)	2(22.2%)	CT scan (-)	1(11.1%)	2(22.2%)	
CEA (N)	DMSA (+)	4(66.7%)	1(16.7%)	CT scan (+)	3(50%)	0	
	DMSA (-)	0	1(16.7%)	CT scan (-)	1(16.7%)	1(33.3%)	
DMSA (+)	CEA (↑)	6(54.5%)	0	CT scan (+)	9(81.0%)	0	
	CEA (N)	4(36.4%)	1(9.1%)	CT scan (-)	1(9.1%)	1(9.1%)	
DMSA (-)	CEA (↑)	1(25%)	2(50%)	CT scan (+)	0	1(25%)	
	CEA (N)	0	1(25%)	CT scan (-)	1(25%)	2(50%)	
CT scan (+)	CEA (↑)	6(60%)	1(10%)				
	CEA (N)	3(30%)	0				
CT scan (-)	CEA (↑)	1(20%)	1(20%)				
	CEA (N)	1(20%)	2(40%)				



**Figure 1:** Mediastinal lymph node involvement on WBS with [<sup>99m</sup>Tc-DMSA (V)]



We also determined the sensitivity and specificity of the combination of these modalities:

In the case of positive CT and Positive CEA result, the both sensitivity and specificity are 100%. The sensitivity and specificity of negative CT in association of negative CEA result are 100% and 50% respectively. When both CT and [<sup>99m</sup>Tc-DMSA (V)] scans have negative results, the sensitivity and specificity are 100% and 50% respectively. In the presence of positive [<sup>99m</sup>Tc-DMSA (V)] and positive CEA, the sensitivity and specificity of CT is 100% (Fig 1). When both [<sup>99m</sup>Tc-DMSA (V)] and CEA results are negative, the specificity is 100%.

### DISCUSSION

Horiuchi et al considered the development of medullary thyroid carcinoma (MTC) bearing mouse model to search for the tumor localization mechanism of [<sup>99m</sup>Tc-DMSA (V)]. High radioactivity uptake in the tumor tissue was observed, and this accumulation showed a direct correlation with tumor growth and calcitonin secretion, the MTC marker detectable in the blood serum. The gathered data implicated some calcitonin-related factors as the mediator in the [<sup>99m</sup>Tc-DMSA (V)] localization (20). In our study also, there was significant relation between elevated levels of calcitonin and positive [<sup>99m</sup>Tc-DMSA (V)] scans.

The sensitivity and specificity of [<sup>99m</sup>Tc-DMSA (V)] has been reported various in different studies. In a study by Verga et al on 12 patients with proven MTC, the diagnostic value of 123/131I meta-iodo-benzylguanidine (MIBG) and <sup>99m</sup>Tc (V) dimercaptosuccinic acid (<sup>99m</sup>Tc-DMSA-V) was compared. In proven primary or recurrent disease, [<sup>99m</sup>Tc-DMSA (V)] sensitivity was 50% and MIBG sensitivity was 25% (21). In our study there was 11 cases of metastases of which [<sup>99m</sup>Tc-DMSA (V)] could diagnose 10 cases with sensitivity of 90.9%. Another study has compared the efficacy of [<sup>99m</sup>Tc-DMSA (V)] with other imaging modalities such as <sup>99m</sup>Tc MIBI and ultrasonography in the detection of malignant axillary lymph node metastases. The sensitivity and specificity of [<sup>99m</sup>Tc-DMSA (V)] were achieved 53% and 95% respectively (22).

A prospective study compared the detectability of metastatic lesions in MTC by <sup>99m</sup>Tc-tetrofosmin, [<sup>99m</sup>Tc-DMSA (V)] and thallium-201 (<sup>201</sup>Tl). Thirty-four metastatic sites were detected in 12 patients on the basis clinical, radiologic, and histopathologic findings which all of them had elevated calcitonin level. Whole body scan was performed in all patients. Among 34 metastatic sites, 30 could be detected by [<sup>99m</sup>Tc-DMSA (V)]. Only 21 and 20 metastatic sites could be visualized with <sup>201</sup>Tl and tetrofosmin, respectively. Patients with elevated calcitonin levels and normal scintigraphic findings were accepted to have micrometastases. Patients with normal scintigraphic findings and normal calcitonin levels were considered without metastases. These results show that [<sup>99m</sup>Tc-DMSA (V)] is clearly superior to <sup>201</sup>Tl and tetrofosmin in the detection and localization of metastases in patients with MTC (23).

In our study, among 11 patients with elevated calcitonin levels, 10 showed intense [<sup>99m</sup>Tc-DMSA (V)] uptake (metastatic). One of these patients had normal [<sup>99m</sup>Tc-DMSA (V)] scan and considered to have micrometastases. Also, among 11 cases with metastatic lesion, 9 could be detected by CT scan.

Another study by Mallin et al has compared the efficacy of <sup>201</sup>Tl, <sup>99m</sup>Tc-sestamibi, and [<sup>99m</sup>Tc-DMSA (V)] in detection of metastatic lesions in MTC and concluded that thallium-201 and [<sup>99m</sup>Tc-DMSA (V)] provide adequate sensitivity in detection of metastatic lesions in MTC (24). We didn't use Tl-201, but in our study, the [<sup>99m</sup>Tc-DMSA (V)] scan had higher sensitivity than other imaging modalities.

In a study by Udelsman et al, Whole body scintigraphy with [<sup>99m</sup>Tc-DMSA (V)] was performed in seven patients with histologically confirmed medullary carcinoma of the thyroid (MTC). The patients had persistent elevations in their plasma calcitonin levels. The [<sup>99m</sup>Tc-DMSA (V)] scintigram demonstrated local neck recurrence in 3 patients and distant metastases in 2 patients. These data demonstrate [<sup>99m</sup>Tc-DMSA (V)] is a sensitive localizing agent in the evaluation of asymptomatic MTC patients with hypercalcitonemia (25). In our study, the sensitivity and specificity of calcitonin were considered 100% because it used as a tumor

marker for determination of metastases. The sensitivity and specificity of  $[^{99m}\text{Tc-DMSA (V)}]$  in both elevated and normal levels of calcitonin were the same.

In the study of Mojiminiyi et al, 10 patients with suspected primary, recurrent or metastatic medullary carcinoma of the thyroid (MTC) were studied prospectively with  $[^{99m}\text{Tc-DMSA (V)}]$ . Scintigraphy was considered positive in 7 patients and equivocal in one. The 2 patients with primary disease had increased uptake before but not after thyroidectomy. Distant metastases in soft tissue (9 patients) and bone (1 patient) were detected in these patients (26). We did not determine the involvement of lymph nodes, soft tissue, or bone separately, but also we evaluated the presence or absence of enhanced uptake in whole body scan.  $[^{99m}\text{Tc-DMSA (V)}]$  scan had 11 cases of enhanced uptake of which 10 were metastatic and 1 was non-metastatic.

Clarke et al conducted a study in order to assess the role of  $[^{99m}\text{Tc-DMSA (V)}]$  scanning in the management of patients with medullary carcinoma of the thyroid, in which they imaged 10 patients with histologically proven disease. In 8 of the 10 patients  $[^{99m}\text{Tc-DMSA (V)}]$  scan successfully identified tumor deposits, and they concluded that  $[^{99m}\text{Tc-DMSA (V)}]$  scan is a cheap, convenient radiopharmaceutical for studying this group of patients, producing high-quality images with low radiation doses (27).

In our study the sensitivity and specificity of  $[^{99m}\text{Tc-DMSA (V)}]$  scan in cases with elevated calcitonin were 90.9% and 75% respectively. In the study of Celentano et al, local and lymphnodal recurrences of MTC were related with elevated plasma levels of calcitonin. The role of conventional imaging techniques (X-rays, US, CT scan, and MRI) in the follow-up after thyroidectomy is controversial. This study evaluated  $^{111}\text{In-pentetreotide}$  and  $[^{99m}\text{Tc-DMSA (V)}]$  scintigraphy performed in 13 patients with a histologic diagnosis of MTC and in one with MEN 2A, all of whom had undergone thyroidectomy between 3 months and 15 years before.  $^{111}\text{In-pentetreotide}$  scintigraphy was positive in 9/14 patients (64%); the  $[^{99m}\text{Tc-DMSA (V)}]$  was positive in 5/14 patients (35%). In conclusion,  $[^{99m}\text{Tc-DMSA (V)}]$  has lower

sensitivity than  $^{111}\text{In-pentetreotide}$  scintigraphy, to detect MTC recurrences in patient follow-up post-thyroidectomy (28).

In the study of Adams et al, lesion detection sensitivities in patients with MTC for computed tomography,  $^{111}\text{In-pentetreotide}$ , and  $[^{99m}\text{Tc-DMSA (V)}]$  were 32%, 34%, and 65%, respectively (29).

Yen et al reported a case of metastatic insular carcinoma of the thyroid evaluated with  $^{201}\text{Tl}$ ,  $^{99m}\text{Tc-MIBI}$ ,  $[^{99m}\text{Tc-DMSA (V)}]$ ,  $^{99m}\text{Tc-MDP}$  and  $^{131}\text{I}$  whole-body scans, which were obtained after total thyroidectomy. Technetium-99m-MDP images were considered better than  $[^{99m}\text{Tc-DMSA (V)}]$  images in showing bone lesions but not soft-tissue lesions. Furthermore, in this patient with various metastases from insular carcinoma of the thyroid,  $[^{99m}\text{Tc-DMSA (V)}]$  seemed to be the tracer of choice for whole-body imaging (30).

15 patients with proved medullary carcinoma and 6 patients with other differentiated thyroid carcinoma were evaluated for metastatic lesions by  $[^{99m}\text{Tc-DMSA (V)}]$ . Amongst the 15 patients with medullary carcinoma, 12 (80%) showed positive localization either in the primary or one or more metastatic sites. None of the six patients with carcinoma other than medullary showed increased concentration of  $[^{99m}\text{Tc-DMSA (V)}]$  (31). The sensitivity of  $[^{99m}\text{Tc-DMSA (V)}]$  in this study was the same as our findings.

Ugur et al undertook a study in 14 MTC patients to determine the comparative imaging potential of  $^{201}\text{Tl}$ ,  $^{99m}\text{Tc-MIBI}$  and  $[^{99m}\text{Tc-DMSA (V)}]$  in the detection of recurrent or metastatic MTC. All patients underwent total thyroidectomy and had persistently elevated serum calcitonin levels after the surgery. All scintigraphic findings were correlated with contemporaneous CT or MRI studies. CT, MRI and bone scans showed 42 (26 bone, 16 soft tissue) metastatic sites in 11 of the 14 patients.  $[^{99m}\text{Tc-DMSA (V)}]$  showed all of the soft tissue metastases but could not show two bone lesions. Overall, lesion detection sensitivities for  $[^{99m}\text{Tc-DMSA (V)}]$ , MIBI and  $^{201}\text{Tl}$  were 95%, 47% and 19% respectively. They conclude that  $[^{99m}\text{Tc-DMSA (V)}]$  is clearly superior to MIBI and  $^{201}\text{Tl}$  in the follow-up of MTC patients (32).

Adams et al conducted a study in 18 MTC patients with persistently elevated tumor marker (calcitonin, CEA) levels to determine the comparative imaging potential of <sup>111</sup>In-pentetreotide and [<sup>99m</sup>Tc-DMSA (V)] in comparison with histopathological findings. All patients underwent somatostatin receptor scintigraphy using <sup>111</sup>In-pentetreotide whole-body scans and single-photon emission tomography (SPET) imaging. Overall, lesion detection sensitivities for [<sup>99m</sup>Tc-DMSA (V)] and <sup>111</sup>In-pentetreotide were 69% and 29%, respectively. These preliminary results suggest that the combination of metabolic [<sup>99m</sup>Tc-DMSA (V)] and receptor [<sup>111</sup>In-pentetreotide] imaging is more sensitive for tumor localization in patients with recurrent MTC than the use of only one radiopharmaceutical (33).

Adalet et al performed whole-body scanning to establish the pathology of MTC using <sup>201</sup>Tl, [<sup>99m</sup>Tc-DMSA (V)] and <sup>99</sup>Tcm-MIBI in 14 patients, and found average sensitivities of 73%, 82% and 81%, respectively, which are compatible with our study. The sensitivities of <sup>201</sup>Tl, [<sup>99m</sup>Tc-DMSA (V)] and <sup>99</sup>Tcm-MIBI were 100%, 100% and 85% in identifying lymphadenopathies; 40%, 50% and 71% for soft tissue foci; 100% and 100% for foci in pulmonary parenchyma; and 100%, 66% and 100% for recurrences in thyroid gland. So, they had different sensitivities in different tissues (34).

In a retrospective study, Arslan et al evaluated the utility of <sup>111</sup>In-octreotide (OctreoScan) and [<sup>99m</sup>Tc-DMSA (V)] scintigraphy for the localization of recurrent metastatic tumor foci in patients with MTC and compared the findings with those of conventional radiologic imaging methods. The scintigraphic images were compared with CT scan, MRI, and ultrasonography (US) in 14 patients with elevated calcitonin and CEA levels after total thyroidectomy. <sup>111</sup>In-octreotide may be superior to [<sup>99m</sup>Tc-DMSA (V)] for the detection of tumor foci of patients with MTC (78.5% versus 57.1%). They suggest that <sup>111</sup>In-octreotide is superior to [<sup>99m</sup>Tc-DMSA (V)] and has a similar sensitivity rate to CT and MRI for the diagnosis of recurrent or metastatic MTC. Although the combined use of <sup>111</sup>In-octreotide and [<sup>99m</sup>Tc-

DMSA (V)] was most sensitive (85.7%), the combined use of CT and MRI with radionuclide imaging methods may better detect more metastatic tumor foci (35).

Calcitonin (CT) is the most sensitive and specific tumor marker for MTC (5). Bugalho et al conducted a study on 91 MTC patients to compare the sensitivity of fine needle aspiration cytology (FNAC) with serum calcitonin measurement. FNAC was performed in 67 patients (87%) with a sensitivity of 63%; serum calcitonin was measured in 56 patients (73%) with a sensitivity of 98%. This study showed the higher sensitivity of serum calcitonin measurement, as compared with FNAC to diagnose MTC (36).

## CONCLUSION

In our study the serum calcitonin level has considered as a gold standard for diagnosis of metastases of MTC but it can not localize the sites of metastases.

[<sup>99m</sup>Tc-DMSA (V)] scan with the sensitivity and specificity of 90.9% and 75% is a suitable imaging modality, and regarding the possibility of whole body scanning with the minimum radiation exposure, it is superior to CT scan for diagnosis of metastases of medullary thyroid carcinoma.

CT scan with the sensitivity and specificity of 81.8% and 75% in this study, has the second importance after [<sup>99m</sup>Tc-DMSA (V)] scan; especially that the detection of metastatic foci in different sites by CT scan requires the more cost and the more radiation exposure by patient.

## REFERENCES

1. Favia G, Iacobone M. Medullary thyroid carcinoma: state of the art. *G Chir.* 2005; Nov-Dec;26 (11-12):405-9.
2. Raue F German medullary thyroid carcinoma/multiple endocrine neoplasia registry. German MTC/MEN Study Group. *Medullary Thyroid Carcinoma/Multiple Endocrine Neoplasia Type 2.* *Langenbecks Arch Surg.* 1998; 383:334-336.
3. M. Engelbach, R. Görges, T. Forst, A. Pfützner, R. Dawood, S. Heerdt, T. Kunt, A. Bockisch and



- J. Beyer. Improved Diagnostic Methods in the Follow-Up of Medullary Thyroid Carcinoma by Highly Specific Calcitonin Measurements. *The Journal of Clinical Endocrinology & Metabolism* 2000; 85(5): 1890-94.
4. Kameyama K, Takami H. Medullary thyroid carcinoma: nationwide Japanese survey of 634 cases in 1996 and 271 cases in 2002. *Endocr J*. 2004; Oct; 51(5):453-6.
  5. Punales MK, Rocha AP, Gross JL, Maia AL. Medullary thyroid carcinoma: clinical and oncological features and treatment. *Arq Bras Endocrinol Metabol*. 2004 Feb; 48(1):137-46. Epub 2004 Jun 1.
  6. Rufini V, Salvatori M, Garganese MC, Di Giuda D, Lodovica Maussier M, Troncone L. Role of nuclear medicine in the diagnosis and therapy of medullary thyroid carcinoma. *Rays*. 2000 Apr-Jun; 25(2):273-82.
  7. Ismailov SI, Piulatova NR. Postoperative calcitonin study in medullary thyroid carcinoma. *Endocr Relat Cancer*. 2004 Jun; 11(2):357-63.
  8. Clarke SEM, MaisY MN, Briton KE, Gildy DL. Tumour imaging in Clinical Nuclear Medicine, 2nd ed. 1991; 434-435.
  9. Vierhapper H, Raber W, Bieglmayer C, Kaserer K, Weinhausl A, Niederle B. Routine measurement of plasma calcitonin in nodular thyroid diseases. *J Clin Endocrinol Metab*. 1997; 82:1589-1593.
  10. Moley JF, Debenedetti MK, Dilley WG, Tisell LE, Wells SA. Surgical management of patients with persistent or recurrent medullary thyroid cancer. *J Intern Med*. 1998; 243:521-526.
  11. Tisell LE, Dilley WG, Wells Jr SA. Progression of postoperative residual medullary thyroid carcinoma as monitored by plasma calcitonin levels. *Surgery*. 1996; 119:34-39.
  12. Evans DB, Fleming JB, Lee JE, Cote G, Gagel RF. The surgical treatment of medullary thyroid carcinoma. *Semin Surg Oncol*. 1999; 16:50-63.
  13. Gimm O, Ukkat J, Dralle H. Determinative factors of biochemical cure after primary and reoperative surgery for sporadic medullary thyroid carcinoma. *World J Surg*. 1998; 22:562-567; discussion 567-568.
  14. Kurtaran A, Scheuba C, Kaserer K, Schima W, Czerny C, Angelberger P, Niederle B, Virgolini I. Indium-111-DTPA-D-Phe-1-octreotide and technetium-99m-(V)-dimercaptosuccinic acid scanning in the preoperative staging of medullary thyroid carcinoma. *J Nucl Med*. 1998 Nov; 39(11):1907-9.
  15. Shikare S, Bashir K, Menon PS, Bapat RD, Tilve GH. Detection of medullary carcinoma of thyroid, with liver metastasis, using [<sup>99m</sup>Tc-DMSA (V)] scintigraphy. *Journal of postgraduate medicine*. 1995; 41 (1): 12-3.
  16. Chow SM, Chan JK, Tiu SC, Choi KL, Tang DL, Law SC. Medullary thyroid carcinoma in Hong Kong Chinese patients. *Hong Kong Med J*. 2005 Aug; 11(4):251-8.
  17. Udelsman R, Ball D, Baylin SB, Wong CY, Osterman FA Jr, Sostre S. Preoperative localization of occult medullary carcinoma of the thyroid gland with single-photon emission tomography dimercaptosuccinic acid. *Surgery*. 1993 Dec; 114 (6):1083-9.
  18. Berna L, Cabezas R, Mora J, Torres G, Estorch M, Carrio I. <sup>111</sup>In-octreotide and <sup>99m</sup>Tc(V)-dimercaptosuccinic acid studies in the imaging of recurrent medullary thyroid carcinoma. *J Endocrinol*. 1995 Feb; 144 (2):339-45.
  19. Lebouthillier G, Morais J, Picard M, Picard D, Chartrand R, D'Amour P. Tc-99m sestamibi and other agents in the detection of metastatic medullary carcinoma of the thyroid. *Clin Nucl Med*. 1993 Aug; 18(8):657-61.
  20. Horiuchi K, Yomoda I, Ohta H, Endo K, Yokoyama A. Search for polynuclear pentavalent technetium complex of dimercaptosuccinic acid [Tc(V)-DMS] tumour localization mechanism. I. Medullary thyroid carcinoma animal model. *Eur J Nucl Med*. 1991; 18(10):796-800.
  21. Verga U, Muratori F, Di Sacco G, Banfi F, Libroia A. The role of radiopharmaceuticals MIBG and [<sup>99m</sup>Tc-DMSA (V)] in the diagnosis of medullary thyroid carcinoma. *Henry Ford Hosp Med J*. 1989; 37(3-4):175-7.
  22. Ambrus E, Rajtar M, Ormandi K, Sera T, Toszegi A, Lang J, Pavics L, Csernay L. Value of 99m-Tc MIBI and [<sup>99m</sup>Tc-DMSA (V)] scintigraphy in evaluation of breast mass lesions. *Anticancer Res*. 1997 May-Jun; 17(3B):1599-605.
  23. Adalet I, Demirkale P, Unal S, Ouz H, Alagol F, Cantez S. Disappointing results with Tc-99m tetrofosmin for detecting medullary thyroid carcinoma metastases comparison with [<sup>99m</sup>Tc-DMSA (V)] and TI-201. *Clin Nucl Med*. 1999 Sep; 24(9):678-83.
  24. Mallin WH, Elgazzar AH, Maxon HR 3rd. Imaging modalities in the follow-up of non-iodine avid thyroid carcinoma. *Am J Otolaryngol*. 1994 Nov-Dec; 15(6):417-22.
  25. Udelsman R, Mojiminiyi OA, Soper ND, Buley ID, Shepstone BJ, Dudley NE. Medullary carcinoma of the thyroid: management of persistent hypercalcitonemia utilizing [<sup>99m</sup>Tc]

- (v) dimercaptosuccinic acid scintigraphy. *Br J Surg.* 1989 Dec; 76(12):1278-81.
26. Mojiminiyi OA, Udelsman R, Soper ND, Shepstone BJ, Dudley NE. Pentavalent Tc-99m DMSA scintigraphy. Prospective evaluation of its role in the management of patients with medullary carcinoma of the thyroid. *Clin Nucl Med.* 1991 Apr; 16(4):259-62.
  27. Clarke SE, Lazarus C, Mistry R, Maisey MN. The role of technetium-99m pentavalent DMSA in the management of patients with medullary carcinoma of the thyroid. *Br J Radiol.* 1987 Nov; 60(719):1089-92.
  28. Celentano L, Sullo P, Klain M, Lupoli G, Cascone E, Salvatore M. <sup>111</sup>In-pentetreotide scintigraphy in the post-thyroidectomy follow-up of patients with medullary thyroid carcinoma. *Q J Nucl Med.* 1995 Dec; 39(4 Suppl 1):131-3.
  29. Adams S, Acker P, Lorenz M, Staib-Sebler E, Hor G. Radioisotope-guided surgery in patients with pheochromocytoma and recurrent medullary thyroid carcinoma: a comparison of preoperative and intraoperative tumor localization with histopathologic findings. *Cancer.* 2001 Jul 15; 92(2):263-70.
  30. Yen TC, King KL, Yang AH, Liu RS, Yeh SH. Comparative radionuclide imaging of metastatic insular carcinoma of the thyroid: value of technetium-99m-(V) DMSA. *J Nucl Med.* 1996 Jan; 37(1):78-80.
  31. Patel MC, Patel RB, Ramanathan P, Ramamoorthy N, Krishna BA, Sharma SM. Clinical evaluation of <sup>99m</sup>Tc (V)-dimercapto succinic acid (DMSA) for imaging medullary carcinoma of thyroid and its metastasis. *Eur J Nucl Med.* 1988; 13(10):507-10.
  32. Ugur O, Kostakglu L, Guler N, Caner B, Uysal U, Elahi N, Haliloglu M, Yuksel D, Aras T, Bayhan H, Bekdik C. Comparison of <sup>99m</sup>Tc (V)-DMSA, <sup>201</sup>Tl and <sup>99m</sup>Tc-MIBI imaging in the follow-up of patients with medullary carcinoma of the thyroid. *Eur J Nucl Med.* 1996 Oct; 23(10):1367-71.
  33. Adams S, Baum RP, Hertel A, Schumm-Draeger PM, Usadel KH, Hor G. Comparison of metabolic and receptor imaging in recurrent medullary thyroid carcinoma with histopathological findings. *Eur J Nucl Med.* 1998 Sep; 25(9):1277-83.
  34. Adalet I, Kocak M, Oguz H, Alagol F, Cantez S. Determination of medullary thyroid carcinoma metastases by <sup>201</sup>Tl, [<sup>99m</sup>Tc-DMSA (V)], <sup>99m</sup>Tc-MIBI and <sup>99m</sup>Tc-tetrofosmin. *Nucl Med Commun.* 1999 Apr; 20(4):353-9.
  35. Arslan N, Ilgan S, Yuksel D, Serdengeçti M, Bulakbasi N, Ugur O, Ozguven MA. Comparison of In-111 octreotide and Tc-99m (V) DMSA scintigraphy in the detection of medullary thyroid tumor foci in patients with elevated levels of tumor markers after surgery. *Clin Nucl Med.* 2001 Aug; 26(8):683-8.
  36. Bugalho MJ, Santos JR, Sobrinho L. Preoperative diagnosis of medullary thyroid carcinoma: fine needle aspiration cytology as compared with serum calcitonin measurement. *J Surg Oncol.* 2005 Jul 1; 91(1):56-60.