

Sternal nonunion on bone scintigraphy: a case report

Hamid Javadi¹, Mehdi Moharrabi¹, Gholamreza Pourbehi²,
Ebrahim Shafiee³, Majid Assadi²

¹Golestan Research Center of Gastroenterology and Hepatology (GRCGH),
Golestan University of Medical Sciences (GUOMS), Gorgan, Iran

²The Persian Gulf Nuclear Medicine Research Center,
Bushehr University of Medical Sciences, Bushehr, Iran

³Department of Surgery (division of cardiac surgery), Bushehr Medical Center Hospital,
Bushehr University of Medical Sciences, Bushehr, Iran

(Received 11 January 2013, Revised 7 March 2013, Accepted 16 March 2013)

ABSTRACT

Sternal non-union is a severe complication of sternotomy closure following open heart surgeries. Healing problems typically occur in 0.3% to 5% of patients. Technetium-99m methylene diphosphonate (^{99m}Tc-MDP) bone scintigraphy has been used to assess bone nonunion to predict the healing response for proper management.

In this report, we present the case of a marked sternal nonunion following coronary artery bypass graft (CABG), using radionuclide bone scintigraphy.

Key words: Sternal nonunion; Radionuclide bone scintigraphy; Poststernotomy incisional hernia; Coronary artery bypass graft (CABG)

Iran J Nucl Med 2013;21(1):33-35

Published: June, 2013

<http://irjnm.tums.ac.ir>

Corresponding author: Dr Majid Assadi, The Persian Gulf Nuclear Medicine Research Center, The Persian Gulf Biomedical Sciences Institute, Boostan 19 Alley, Sangi Street, Bushehr, Iran. E-mail: asadi@bpums.ac.ir

INTRODUCTION

Sternal non-union is a severe complication of sternotomy closure following open heart surgeries. In the literature, healing problems have been mentioned in 0.3% to 5% of patients, which might carry 14-47% mortality rate secondary to superimposed infection [1, 2].

Sternal nonunion, primarily described in 1928, was thought to be secondary to infection; nevertheless, in 1978 Stoney et al categorized and defined sterile sternal nonunion as a distinct entity [3].

At present, diagnosis of sternal nonunion necessitates some symptoms such as pain or clicking with objective clinical evidence of instability for more than 3 months despite lack of infection [3, 4].

In this respect, technetium-99m methylene diphosphonate (^{99m}Tc-MDP) bone scintigraphy was used to assess bone nonunion to predict the healing response for further treatment [5-7].

Here, we present a case with marked sternal nonunion following coronary artery bypass graft (CABG), using radionuclide bone scintigraphy.

CASE REPORT

A 52-year-old man who underwent coronary artery bypass graft (CABG) developed high-grade fever and chills; his condition deteriorated gradually. Therefore, following sepsis workup, a course of antibiotic treatment was initiated. In physical examination, a pulsatile protrusion along the mid-sternal line was detected. Diagnosis was sternal nonunion followed by an incisional hernia (Figure 1).

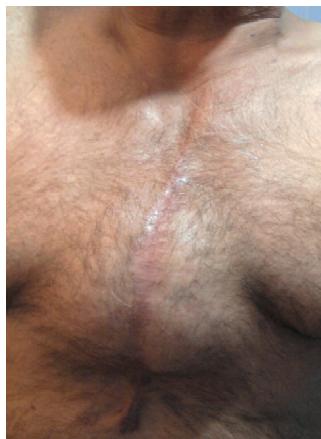

Fig 1. Postoperative photograph at 2 years.

To assess the possibility of bone healing, the patient was referred to the department of nuclear medicine. A radionuclide bone scan showed a complete defect along the sternum (Figure 2). This finding was confirmed in the CT scan images (Figure 3).

DISCUSSION

This case represents a vivid sternal nonunion followed by an incisional hernia. Sternal nonunion is usually categorized as partial or complete [4]. Complete nonunion is classified into four categories based on the existence of transverse fractures or missing bone segments. Type I describes a midline nonunion without any accompanying transverse fractures. Type II is nonunion with a unilateral transverse fracture and type III refers to nonunion with single or multiple bilateral transverse fractures. Type IV nonunions defines several fractures with a missing bone segment along with free-floating bone fragments [4]. Risk factors for sternal nonunion following median sternotomy include extrinsic or intrinsic variables but mostly multifactorial [3].

Sternal dehiscence may cause nonunion if it is not diagnosed in the early postoperative phase. Sternal nonunion, which also infrequently develops even in the lack of dehiscence, may result in further complications. Signs of sternal instability may consist

of a clicking sound or a sensation of grinding of the edges of sternal bone during chest wall movement. Li et al reported 3 patients with remarkable sternal nonunion after coronary artery bypass graft surgery [8].

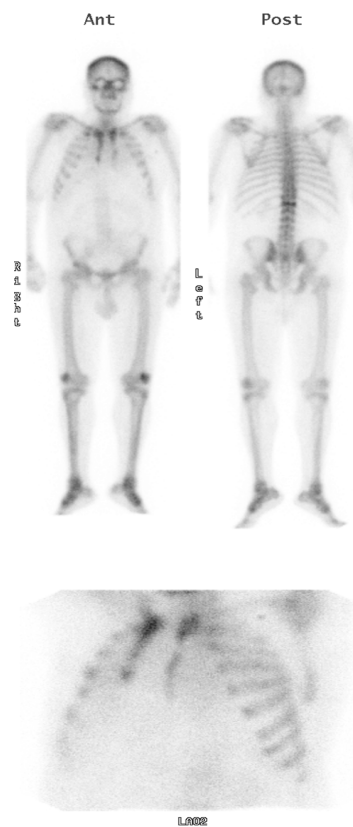


Fig 2. A radionuclide whole body bone scan shows a split sternum with a linear radiotracer uptake in the L1 vertebra.

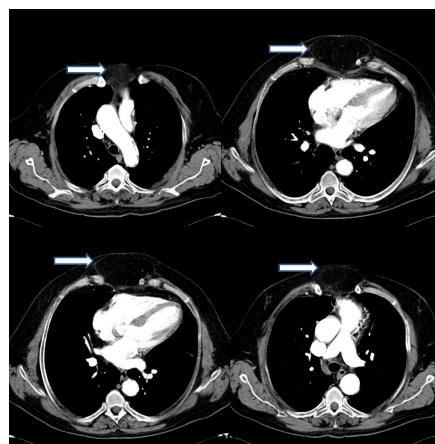


Fig 3. CT scan of the thorax: There is a large protrusion of the heart through the sternum after CABG (arrows).

Although sternal nonunion is not associated with increased mortality, appropriate treatment is critical. Sterile nonunion considerably increases morbidity, and the patients are prone to osteomyelitis, mediastinitis, and deep sternal space infections [9, 10].

Preoperative radiographs or computed tomography (CT) are useful for the determination of the number and location of fractures and wires as well as for surgical planning [11].

The efficacy of technetium-99m methylene diphosphonate (99mTc-MDP) bone scintigraphy in the nonunion assessment has been evaluated in a number of studies [5-7]. Bone scans have demonstrated 3 distinct scintigraphic patterns. The most common pattern is an increased uniform uptake at the non-union site (group 1) [5]. The second most common pattern is described as an increased activity at the bone edges with a photopenic region between the fracture sites (group 2a) or a generalized decrease in the radiotracer uptake in the region of bone fragments (group 2b). When the scintigraphic pattern does not meet either of the two patterns or when the existence of photon-deficient area between the bone fragments could not be interpreted with certainty, the condition is defined as indeterminate (group 3). Therefore, 99mTc bone scintigraphy seems to be a helpful modality in determining complicated non-unions and selecting appropriate mode of therapy [5, 12, 13].

CONCLUSION

In our case, a complete splitting of the sternum on the bone scan was observed. Radionuclide bone scans may be valuable in either distinguishing the healing process or finding any nonunion bone following surgical intervention.

A radionuclide bone scan may be quite helpful in assessing the state of nonunion process, and help the surgeon to have a better idea of the patient's condition before repair is attempted.

REFERENCES

1. Satta J, Lahtinen J, Räisänen L, Salmela E, Juvonen T. Options for the management of poststernotomy mediastinitis. *Scand Cardiovasc J*. 1998;32(1):29-32.
2. El Oakley RM, Wright JE. Postoperative mediastinitis: classification and management. *Ann Thorac Surg*. 1996 Mar;61(3):1030-6.
3. Stoney WS, Alford WC Jr, Burrus GR, Frist RA, Thomas CS Jr. Median sternotomy dehiscence. *Ann Thorac Surg*. 1978 Nov;26(5):421-6.
4. Hendrickson SC, Koger KE, Morea CJ, Aponte RL, Smith PK, Levin LS. Sternal plating for the treatment of sternal nonunion. *Ann Thorac Surg*. 1996 Aug;62(2):512-8.
5. Günalp B, Ozgüven M, Oztürk E, Ercenk B, Bayhan H. Role of bone scanning in the management of non-united fractures: a clinical study. *Eur J Nucl Med*. 1992;19(10):845-7.
6. Desai A, Alavi A, Dalinka M, Brighton C, Esterhai J. Role of bone scintigraphy in the evaluation and treatment of nonunited fractures: concise communication. *J Nucl Med*. 1980 Oct;21(10):931-4.
7. Barros JW, Barbieri CH, Fernandes CD. Scintigraphic evaluation of tibial shaft fracture healing. *Injury*. 2000 Jan;31(1):51-4.
8. Li AE, Fishman EK. Evaluation of complications after sternotomy using single- and multidetector CT with three-dimensional volume rendering. *AJR Am J Roentgenol*. 2003 Oct;181(4):1065-70.
9. Serry C, Bleck PC, Javid H, Hunter JA, Goldin MD, DeLaria GA, Najafi H. Sternal wound complications. Management and results. *J Thorac Cardiovasc Surg*. 1980 Dec;80(6):861-7.
10. Stähle E, Tammelin A, Bergström R, Hambreus A, Nyström SO, Hansson HE. Sternal wound complications--incidence, microbiology and risk factors. *Eur J Cardiothorac Surg*. 1997 Jun;11(6):1146-53.
11. Wu LC, Renucci JD, Song DH. Sternal nonunion: a review of current treatments and a new method of rigid fixation. *Ann Plast Surg*. 2005 Jan;54(1):55-8.
12. Eftekhari M, Assadi M, Fard-Esfahani A, Beiki D, Fallahi B. Dystrophic calcinosis cutis and SLE; the bone scan pattern. *Iran J Nucl Med*. 2004;12(2):1-4.
13. Chepla KJ, Salgado CJ, Tang CJ, Mardini S, Evans KK. Late complications of chest wall reconstruction: management of painful sternal nonunion. *Semin Plast Surg*. 2011 Feb;25(1):98-106.