

^{18}F -FDG PET/CT findings in a possible MELAS syndrome: A case study

**Alireza Emami-Ardekani¹, Sara Harsini^{1,2}, Armaghan Fard-Esfahani¹,
Farzaneh Baseri¹, Mohammad Eftekhari¹**

¹Research Center for Nuclear Medicine, Tehran University of Medical Sciences, Tehran, Iran

²Association of Nuclear Medicine and Molecular Imaging (ANMMI),
Universal Scientific Education and Research Network (USERN), Tehran, Iran

(Received 2 September 2018, Revised 27 October 2018, Accepted 1 November 2018)

ABSTRACT

Mitochondrial myopathy, encephalopathy, lactic acidosis, and stroke-like episodes (MELAS) syndrome is a rare congenital disorder of mitochondrial DNA, presenting a wide range of clinical symptoms comprising headaches, seizures, aphasia, hearing loss, visual defects, and hemiparesis. Herein we report a case of a previously asymptomatic 40-year-old male who presented with recurrent headache, seizures, Wernicke's aphasia, and impaired visual acuity. Investigations included CT, MRI, MR venography, MR spectroscopy, and PET/CT with ^{18}F -fluorodeoxyglucose (^{18}F -FDG-PET) of the brain. PET imaging showed diffuse increased ^{18}F -FDG uptake in the right hemisphere and left temporal lobe; additionally, decreased ^{18}F -FDG uptake was observed in the left frontoparietal lobe. The patient underwent treatment by levetiracetam, co-enzyme Q10, riboflavin, L-carnitine, and lacosamide, followed by improvement of his clinical signs and symptoms indicative of partial response to the therapy.

Key words: MELAS; Seizure; PET; ^{18}F -fluorodeoxyglucose

Iran J Nucl Med 2019;27(1):57-59

Published: January, 2019

<http://ijnm.tums.ac.ir>

Corresponding author: Dr. Sara Harsini, Shariati Hospital, North Kargar Ave. 1411713135, Tehran, Iran. E-mail: sara.harsini@gmail.com

INTRODUCTION

Mitochondrial myopathy, encephalopathy, lactic acidosis and stroke-like episode (MELAS) is a distinct syndrome clinically characterized by focal cerebral lesions and neurological symptoms [1], is known to be the most common type of mitochondrial disease, mainly caused by an A-to-G transition at nucleotide position 3243 (A3243G) in mitochondrial DNA [2]. The clinical features of MELAS syndrome comprise stroke-like episodes (provoking neurological symptoms such as headache, epilepsy, hemiparesis and dementia due to the affected brain lesions), myopathy, lactic acidosis, diabetes mellitus and cardiomyopathy [1]. Clinical studies involving functional imaging techniques have recently provided useful information to understand the pathophysiology of this syndrome, and existence of variations of the disease depending on individual patient or stage of the disease. This however, has not been shown to be detectable by morphological imaging investigations. Such findings underline the importance of functional neuroimaging techniques to investigate the metabolism pattern of MELAS syndrome. In the current report, we present a patient with MELAS syndrome who was examined in his clinical course with positron-emission tomography/computed tomography (PET/CT) as an imaging biomarker in diagnosis of this complex disease entity.

CASE HISTORY

A 40-year-old male presented with sudden development of headache, generalized tonic-clonic seizures, impaired visual acuity, aphasia with predominantly sensory features, and intellectual impairment, was referred to the Neurology department. He was apparently normal until six months prior to the current admission, when he developed headaches and generalized tonic-clonic seizures and was primarily treated with acyclovir with a suspected diagnosis of herpes encephalitis. However, as the cerebrospinal fluid herpes-simplex virus (HSV) polymerase chain reaction (PCR) was found to be negative at that time, methylprednisolone was then administered against suspected acute disseminated encephalomyelitis (ADEM). The patient was clinically improved and experienced no more epileptic seizures. He also underwent left temporal cortical biopsy, suggesting spongiform encephalopathy.

On the current admission, all routine laboratory data were normal, except for a high serum lactate level (24.8 mg/dl, normal range: 4.0-16.0 mg/dl) and pyruvate (0.93 mg/dl, normal range: 0.3-0.9 mg/dl). Initial brain CT depicted bilateral hypodensities in temporo-occipito-parietal lobes, suggestive of either encephalitis or multifocal recent infarcts. The accompanying magnetic resonance imaging (MRI)

demonstrated multifocal cortical and subcortical signal areas located in parietal, parieto-temporal, occipito-temporal, as well as temporal lobes bilaterally. Same findings were observed in the right high parietal, high frontal and along the parahippocampal gyrus (more prominent on the left side) on diffusion-weighted images (DWI). Subacute encephalitis was suggested as the underlying pathology. Brain MR venography demonstrated no evidence of thrombosis. At this time with the assumption of MELAS syndrome he was started on levetiracetam, co-enzyme Q10, riboflavin, L-carnitine, and lacosamide, however, his impaired consciousness did not resolve completely. Follow-up MRI after one week revealed diffuse abnormal high T2/FLAIR signal intensity in cortex and subcortical white matter of right fronto-temporo-parietal and left temporo-parietal as well as swelling of cortex on DWI. MR spectroscopy demonstrated an increased lactate peak in bilateral temporo-parietal lobes. At this time, the patient underwent the ¹⁸F-FDG-PET brain study, revealing diffusely increased ¹⁸F-FDG uptake in the right hemisphere and left temporal lobe together with decreased ¹⁸F-FDG uptake in the left fronto-parietal lobe (Figure 1).

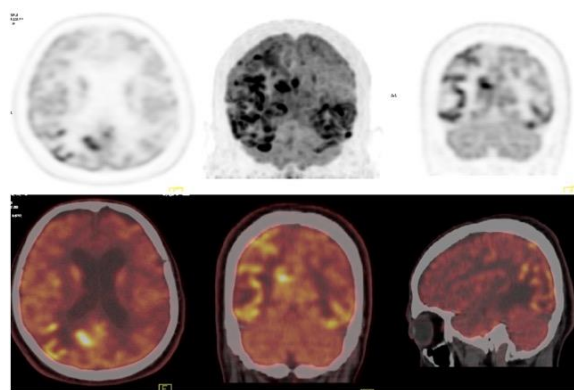


Fig 1. Hybrid ¹⁸F-FDG PET/CT images demonstrating generalized heterogeneous increased ¹⁸F-FDG uptake in the right hemisphere and left temporal lobe as well as decreased ¹⁸F-FDG uptake in the left fronto-parietal lobe.

All the above-mentioned data along with the patient's clinical course were highly suggestive of MELAS syndrome. The definitive diagnosis however, was impossible to reach, since the patient's caregiver did not consent for complementary muscle biopsy and molecular studies.

DISCUSSION

MELAS is a rare and complex neurodegenerative disorder presenting with a wide spectrum of radiological and clinical manifestations, including, headaches, visual loss, neuropsychiatric dysfunction,

seizures, gastrointestinal, and cardiac rhythm abnormalities, which could pose diagnostic challenges. Such presentations may result in the misdiagnosis of MELAS as encephalitis, myasthenia gravis, gastrointestinal or cardiac diseases, epilepsy, and cerebral infarction [3]. With regard to the imaging findings, it is known that characteristic stroke-like episodes and stroke-like lesions, which are typically not restricted to single vascular territories, have a tendency to vary over time, involving the cortical locations with sparing of deep white matter, gradually leading to atrophy over time. As a result, the evaluation and diagnosis of MELAS syndrome may be an easy task. Clinical and radiological findings may pose a challenge to initially differentiate from cerebral ischemia; however, neuroimaging supplements the clinical history and further delineates stroke-like lesions from ischemic stroke. Nevertheless, certain radiological mimickers, comprising Creutzfeldt-Jacob disease, herpes encephalitis, gliomatosis cerebri [4], and lymphoma need to be ruled out in MELAS patients [5]. Several imaging modalities have emerged providing supplementary details of involved cerebral tissue, among which MRI is the most preferred one. PET imaging allows non-invasive visualization of several pathophysiologic conditions related to disease mechanism as oxidative stress (⁶²Cu-ATSM), alterations of glucose metabolism (¹⁸F-FDG) and regional cerebral blood flow (¹⁵O₂) [6-8]. Pathogenesis of MELAS syndrome may be explained by a combination of several interacting mechanisms including neuronal and/or glial injury as direct consequence of mitochondrial energy failure, microvasculature angiopathy resulting in dysregulated cerebral perfusion, and nitric oxide (NO) deficiency [6]. The energy deficit in the neural tissue leads to hyper-perfusion to increase delivery of energy substrates, but hyperemia may depend on dysregulated blood vessel tone from mitochondrial angiopathy [9]. The overloading of oxygen and enhanced glucose metabolism in the neurons and glial cells through hyperemia play crucial roles in the pathogenesis of MELAS stroke-like episodes. ¹⁸F-FDG-PET may allow to characterize metabolic feature of MELAS syndrome. In the study of Ikawa et al. acute stroke-like lesions exhibited mild accumulations of ¹⁸F-FDG and ⁶²Cu-ATSM in the early (reflecting CBF) and delayed (reflecting oxidative stress) phases. Subacute stroke-like lesions (1 month after the episodes) showed slightly decreased accumulations of ¹⁸F-FDG and ⁶²Cu-ATSM. Chronic stroke-like lesions (1 year after stroke-like episodes) showed insubstantial accumulations of both tracers [6]. Moreover, impaired cerebral glucose uptake in temporal and parietal lobes have been detected in MELAS patients previously [10]. In keeping with all the above-mentioned findings, together with the PET imaging results to conclude MELAS syndrome in this

patient, future investigations are expected to involve multimodality imaging studies to focus over both the diagnostic and prognostic aspects of this complex disorder in greater details.

REFERENCES

1. Pavlakis SG, Phillips PC, DiMauro S, De Vivo DC, Rowland LP. Mitochondrial myopathy, encephalopathy, lactic acidosis, and stroke-like episodes: a distinctive clinical syndrome. *Ann Neurol*. 1984 Oct;16(4):481-8.
2. Goto Y, Nonaka I, Horai S. A mutation in the tRNA(Leu)(UUR) gene associated with the MELAS subgroup of mitochondrial encephalomyopathies. *Nature*. 1990 Dec 13;348(6302):651-3.
3. Wang YX, Le WD. Progress in diagnosing mitochondrial myopathy, encephalopathy, lactic acidosis, and stroke-like episodes. *Chin Med J (Engl)*. 2015 Jul 5;128(13):1820-5.
4. Ramanathan RS, Malhotra K, Scott T. Teaching NeuroImages: diffuse cerebral neurosarcoidosis mimicking gliomatosis cerebri. *Neurology*. 2013 Aug 13;81(7):e46.
5. Malhotra K, Liebeskind DS. Imaging of MELAS. *Curr Pain Headache Rep*. 2016 Sep;20(9):54.
6. Ikawa M, Okazawa H, Arakawa K, Kudo T, Kimura H, Fujibayashi Y, Kuriyama M, Yoneda M. PET imaging of redox and energy states in stroke-like episodes of MELAS. *Mitochondrion*. 2009 Apr;9(2):144-8.
7. Yoneda M, Ikawa M, Arakawa K, Kudo T, Kimura H, Fujibayashi Y, Okazawa H. In vivo functional brain imaging and a therapeutic trial of L-arginine in MELAS patients. *Biochim Biophys Acta*. 2012 May;1820(5):615-8.
8. Yoshii Y, Yoneda M, Ikawa M, Furukawa T, Kiyono Y, Mori T, Yoshii H, Oyama N, Okazawa H, Saga T, Fujibayashi Y. Radiolabeled Cu-ATSM as a novel indicator of overreduced intracellular state due to mitochondrial dysfunction: studies with mitochondrial DNA-less ρ0 cells and cybrids carrying MELAS mitochondrial DNA mutation. *Nucl Med Biol*. 2012 Feb;39(2):177-85.
9. Rodan LH, Poublanc J, Fisher JA, Sobczyk O, Wong T, Hlasny E, Mikulis D, Tein I. Cerebral hyperperfusion and decreased cerebrovascular reactivity correlate with neurologic disease severity in MELAS. *Mitochondrion*. 2015 May;22:66-74.
10. Molnár MJ, Valikovic A, Molnár S, Trón L, Diószeghy P, Mechler F, Gulyás B. Cerebral blood flow and glucose metabolism in mitochondrial disorders. *Neurology*. 2000 Aug 22;55(4):544-8.