

The truncation artifact in a skinny patient following myocardial perfusion SPECT

Elahe Pirayesh

Department of Nuclear Medicine, Shohada-e-Tajrish Medical Center, School of Medicine,
Shahid Beheshti University of Medical Sciences, Tehran, Iran

(Received 15 May 2020, Revised 26 August 2020, Accepted 31 August 2020)

ABSTRACT

Myocardial perfusion SPECT is one of the most common imaging techniques performed in nuclear medicine departments. To avoid misleading interpretation, it is necessary to address the quality control and technical problems. The truncation artifact occurs when the patient size is large relative to the field of view of the camera, causing false perfusion defects in the LV myocardium, misinterpreted as myocardial perfusion abnormality. It usually happens in obese patients, who may deviate from the detector field. Here, we present a skinny patient showing myocardial truncation artifact, proved to be because of technical issues.

Key words: Artifacts; Myocardial perfusion imaging; SPECT; Truncation

Iran J Nucl Med 2021;29(1):35-37

Published: January, 2021

<http://irjnm.tums.ac.ir>

Corresponding author: Dr. Elahe Pirayesh, Department of Nuclear Medicine, Shohada-e-Tajrish Medical Center, School of Medicine, Shahid Beheshti University of Medical Sciences, Tehran, Iran. E-mail: elahe_pirayesh@yahoo.com

INTRODUCTION

Understanding imaging artifacts is a very important issue in myocardial perfusion scans. To avoid misleading imaging interpretation, it is essential to recognize and follow standard quality control and technical protocols. The truncation artifact occurs when the patient is larger than the field of view of the camera, causing false perfusion defect in the LV myocardium, misinterpreted as myocardial infarction, hibernated myocardium or ischemia [1]. It usually happens in obese patients, who may deviate from the detector field [2]. Here, we present a skinny patient with truncation artifact, caused by technical shortcoming.

CASE PRESENTATION

A 28 years old man with history of recent atypical chest pain was referred to our nuclear medicine department for myocardial perfusion imaging. He had no risk factor, his height and weight were 182 cm and 68 kg, respectively.

He underwent a two-day rest/stress protocol of myocardial imaging, receiving 555 MBq and 925 MBq of ^{99m}Tc -sestamibi for rest and stress phase,

respectively. Stress test was done according to the Bruce protocol, achieving 95% of maximal age-predicted heart rate. All images were acquired in auto-contour non-circular mode using a dual head gamma camera (Siemens, e.cam dual head, Germany) equipped with low energy, high-resolution collimator fitted at 90° . Projection images were obtained from the 45° right anterior oblique to 45° left posterior oblique in step and shoot mode (32 projections, 25sec per projection; matrix 64×64 and zoom 1.4). Images were processed with ordered subset expectation maximization (OSEM). Reconstructed tomographic images (Figure 1: stress in the top and rest in the bottom) showed relatively homogeneous distribution of radiotracer uptake throughout the LV myocardium in the stress phase. However, in the rest images, a severe perfusion defect in the apex and anteroseptal wall was noted, unexpectedly. Careful reviewing of the rotating projection images (Figure 2) demonstrated temporary incomplete visualization of the apex between frames 24 to 31 during the rest acquisition, which had not been recognized by the imaging technologist.

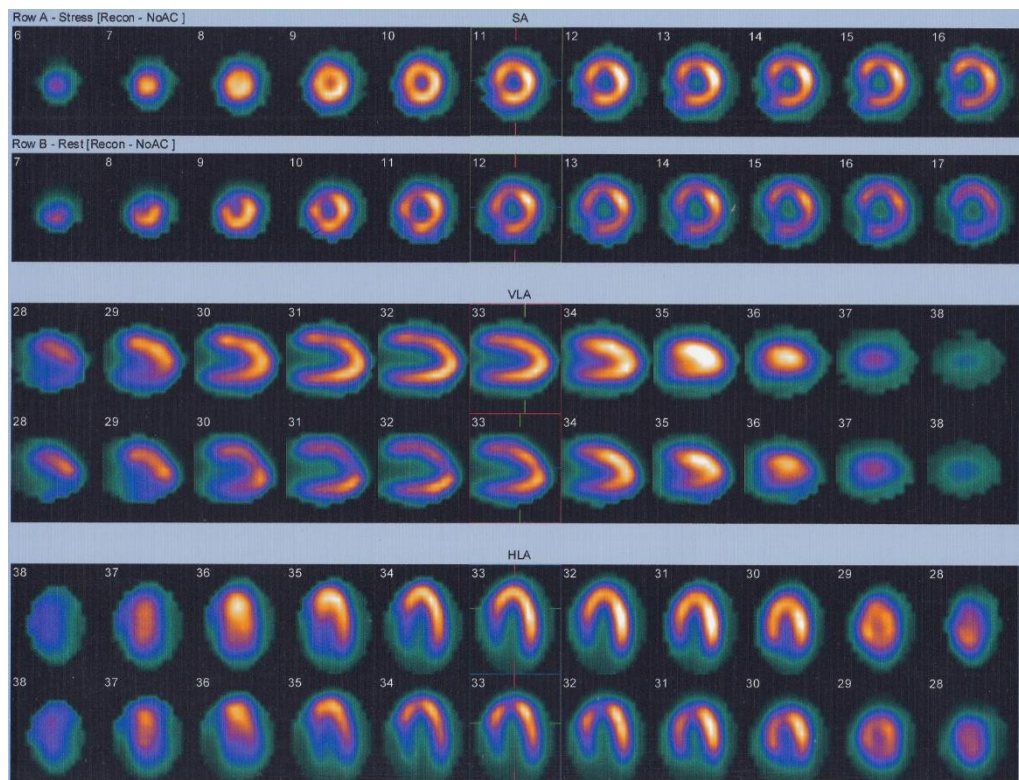


Fig 1. Reconstructed tomographic images (stress on the top and rest on the below) demonstrate Homogeneous tracer distribution throughout the entire left ventricular myocardium in stress phase. However, in rest images, heterogeneous uptake with a perfusion defect in the apical anteroseptal wall is noted.

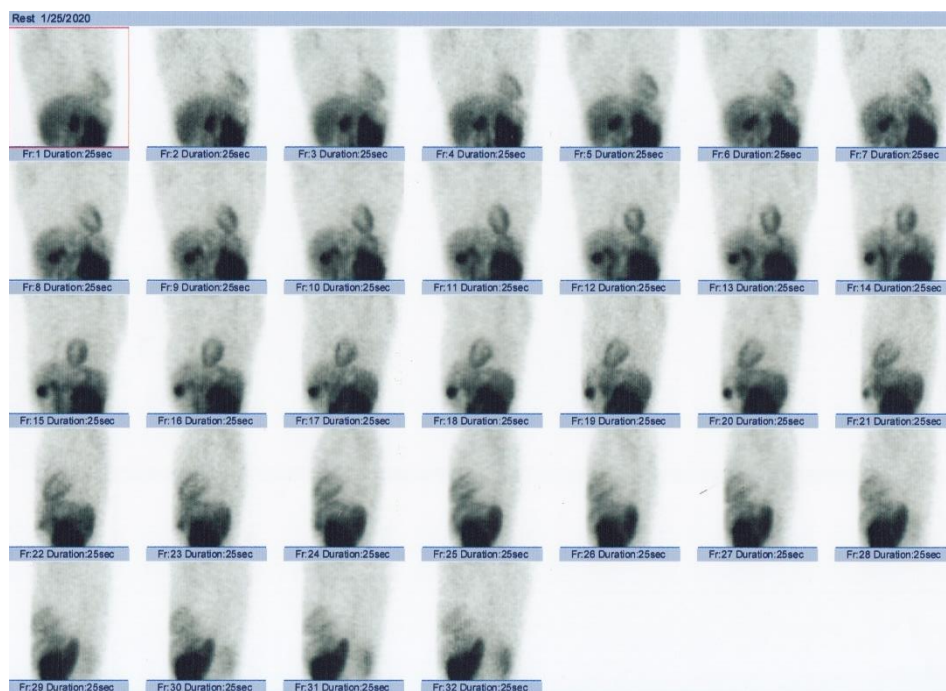

Fig 2. Rotating planar projection images reveal truncation of the apex between frames of 24 to 31 during the rest acquisition.

DISCUSSION

Truncation artifact occurs when part of the patient's body is outside of the imaging field and can cause false perfusion defects in the reconstructed tomographic images. Understanding the potential causes is the key factor to prevent the artifact. Body habitus characteristic is the most well known cause and obese patients who may deviate from the detector field are at higher risk for the artifact [2]. Several other factors including small field of view and fan beam collimator can cause this artifact, as well [1, 3]. During auto-contouring acquisition with 90 degree angled dual head detectors, due to extremely closed position of one detector to the patient's chest wall, the other detector cannot cover the full patient's body, causes the truncation artifact. It will be more prominent if a zoom factor is used, additionally [4, 5]. Keeping in mind that false perfusion defects caused by pitfalls and artifacts (including attenuations, low count images, patient motion...) can lead to misleading results, the quality control of raw projections is the first step of image interpretation. By careful reviewing of raw data truncation of the heart or body could be recognized easily. In addition, while in normal conditions body contour has an elliptical shape in the reconstructed axial image, non-uniformity and abnormal shape of raw projection field could be suggestive of the artifact [2].

Surprisingly, in our patient truncation artifact did not happen during the stress study, which could be explained by the presence of wires on the chest wall during the stress-gated acquisition. It has been

suggested that by placing a thin pillow or folded blanket on the chest wall this artifact could be avoided in slim patients [5]. Our patient highlights the importance of reviewing the rotating planar images before the interpretation. Interestingly, wires on the chest wall could be an alternative solution to prevent this artifact in slim patients.

In conclusion, truncation artifact is not limited to obese patient and it can occur in skinny patient. Selection of individualized acquisition parameters should be considered to prevent the artifact.

REFERENCES

1. Wosnitzer B, Gadiraju R, Depuey G. The truncation artifact. *J Nucl Cardiol*. 2011 Feb;18(1):187-91.
2. Matsumoto N, Suzuki Y, Yoda S, Hirayama A. The truncation artefact in patients with a high body mass index on myocardial perfusion SPECT. *BMJ Case Rep*. 2014 Jul 15;2014. pii: bcr2014205407.
3. Xiao J, Verzijlbergen FJ, Viergever MA, Beekman FJ. Small field-of-view dedicated cardiac SPECT systems: Impact of projection truncation. *Eur J Nucl Med Mol Imaging*. 2010 Mar;37(3):528-36.
4. Tsougos I, Alexiou S, Theodorou K, Valotassiou V, Georgoulas P. The prevalence of a false-positive myocardial perfusion stress SPET test in a skinny patient, induced by projection truncation. *Hell J Nucl Med*. 2015 Jan-Apr;18(1):79-80.
5. Yapici O, Baris S, Alic T, Basoglu T. Auto-contouring at 90 degrees dual head fitting angle: a potential cause of a myocardial perfusion SPET artifact in slim patients. *Hell J Nucl Med*. 2009 Sep-Dec;12(3):289-90.