

## Chronic recurrent multifocal osteomyelitis; manifestation, imaging and diagnosis

Mohammadhassan Aelami<sup>1</sup>, Hamid Ahanchian<sup>1</sup>, Reza Jafarzadeh Esfehani<sup>2</sup>,  
Yasmin Davoudi<sup>3</sup>, Mohammad Gharedaghi<sup>4</sup>, Vahid Reza Dabbagh Kakhki<sup>5</sup>

<sup>1</sup>Department of Pediatrics, Faculty of Medicine, Mashhad University of Medical Sciences, Mashhad, Iran

<sup>2</sup>Sabzevar University of Medical Sciences, Sabzevar, Iran

<sup>3</sup>Department of Radiology, Faculty of Medicine, Mashhad University of Medical Sciences, Mashhad, Iran

<sup>4</sup>Department of Orthopedics, Faculty of Medicine, Mashhad University of Medical Sciences, Mashhad, Iran

<sup>5</sup>Nuclear Medicine Research Center, Ghaem Hospital, Faculty of Medicine, Mashhad University of  
Medical Sciences, Mashhad, Iran

(Received 28 May 2013, Revised 6 June 2013, Accepted 8 June 2013)

### ABSTRACT

Chronic recurrent multifocal osteomyelitis (CRMO) is an inflammatory bone disease usually affecting children. A 9-year old boy presented with recurrent lower extremities pain and discomfort lasting for two years. In every time, symptoms vanished after several weeks. The patient received antibiotics only in one period of bone pain. In other occasions the patient didn't receive any antibiotics. In last episode of bone pain, symptoms disappeared by use of naproxen. In patient's X-rays, there were multifocal areas of sclerosis with a wide transitional zone accompanied by a fine periosteal reaction. Regarding his history and MRI, bone scan findings were more in favor of active inflammatory process in the involved regions. In needle biopsy and bone curetting of left & right tibiae, osteonecrosis, mild inflammatory fibrosis, and scattered chronic inflammatory cells consistent with chronic osteomyelitis were noticed. No malignant neoplastic tissue was identified. In 2-year follow-up, diagnosis of CRMO was confirmed by serial laboratory tests, three-phase bone scan, CT and MRI findings. This diagnosis was proved by pathology evaluation following needle bone biopsy.

**Key words:** Chronic recurrent multifocal osteomyelitis; Bone pain; Bone Scan

**Iran J Nucl Med 2014;22(1):29-32**

Published: December, 2013

<http://irjnm.tums.ac.ir>

**Corresponding author:** Dr. Vahid Reza Dabbagh Kakhki, Nuclear Medicine Research Center, Ghaem Hospital, Mashhad University of Medical Sciences, Mashhad, Iran. E-mail: [dabbaghvr@mums.ac.ir](mailto:dabbaghvr@mums.ac.ir)

## INTRODUCTION

Chronic recurrent multifocal osteomyelitis (CRMO), is a very rare bone disease usually presented in early life [1-3]. This illness is well known by its exacerbations and spontaneous remissions [4]. Diagnosis is mainly based on excluding radiological, pathological and clinical conditions [1]. Common clinical manifestations are swelling with gradual onset and local pains with or without fever [1, 3]. The most commonly affected bones are clavicle, sternum, ribs, pelvis, spine and peripheral long bones [5]. Skeletal features of sclerosis, long bone deformity, premature epiphyseal fusion and growth arrest are also some of the known complications [4]. We present a case of a young boy presenting with chronic onset of lower extremities' pain.

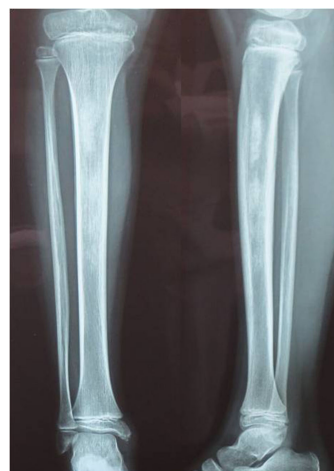## CASE PRESENTATION

A 9-year-old boy presented with a history of recurrent pain in his lower extremities since 2 years ago. At the first visit his pain was in both legs and after several weeks these symptoms relieved without any medications. After a year the pain returned in his left leg which was worse at night, waking him up but in day time the pain had moderate intensity. In physical examination there was a local tender area below the knee centered in the mid portion of the left tibial diaphysis. Otherwise the patient had no history of fevers, chills, or weight loss. His appetite and growth was normal. There was no history of previous surgeries, bone or joint abnormalities, and tumors or any predisposing factors. Laboratory tests including white blood count (WBC) count, erythrocyte sedimentation rate (ESR), C-reactive protein (CRP), serum rheumatoid factor, C3, C4, IgG, IgM and IgA were all within normal limits. His calcium and alkaline phosphatase were normal while his phosphate level was slightly higher than normal (7.3, upper normal limit 7.0). His HLA B27 was negative and his ANA level was 0.2 (normal limit up to 1). For a short period in the two-year, he was placed on antibiotics.

His X-rays demonstrated multifocal areas of sclerosis with a wide transitional zone accompanied by a fine periosteal reaction (Figure 1). His CT scan revealed the same findings: large segmental medullary sclerotic lesion in mid diaphyseal portion of the left tibia. There was no cortical destruction or soft tissue mass, edema or swelling.

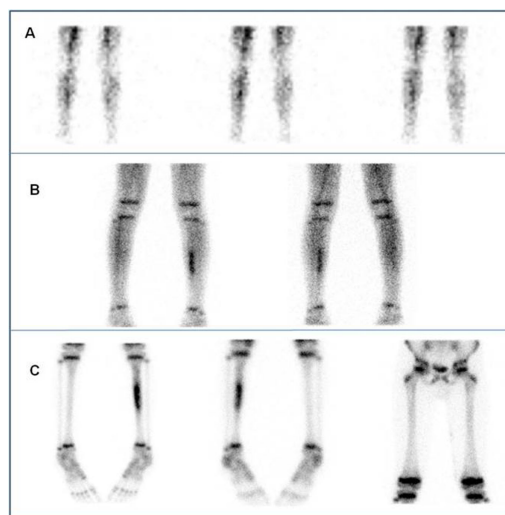
In first year of presentation, patient underwent three-phase bone scintigraphy (Figure 2). The scan showed slightly increased flow to his right shin; however, in blood pool images linear increased activity was noted in the middle third of his left leg and delayed views showed moderate to high increased activity in mid-

shaft of the left tibia. A year later, the patient underwent bone scintigraphy again (Figure 3a and 3b).

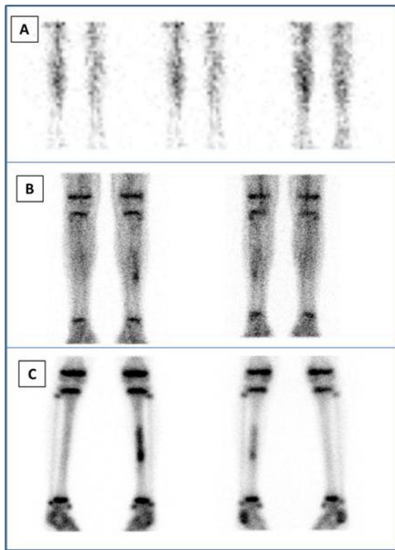


**Fig 1.** Radiographs of the left leg showed ill-defined zones of diaphyseal sclerosis in the left tibia as well as fine periosteal reaction.

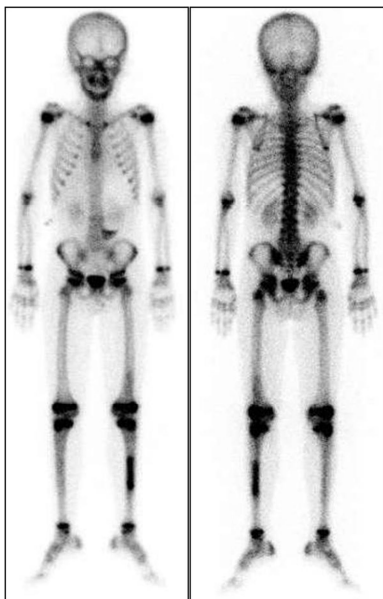
His last three-phase bone scan showed bony lesion in the middle portion of left tibia as well as mildly increased tracer uptake in the distal portion of the left femur. His whole body scan by Tc99m-Ubiquidine showed asymmetric accumulation of radiotracer in the right tibia as well as small zone of faint uptake in left tibia. However there was no increased tracer accumulation from 10-minute till 2-hours images.



**Fig 2.** Three-phase bone scan from the legs: Upper row(A): anterior images of the perfusion phase showed mildly more tracer activity in the right leg. Middle row (B): anterior (left) and posterior (right) blood pool images showed linear increased tracer activity in the middle portion of the left tibial diaphysis. C: Delayed anterior (left & right), and posterior (middle) images showed increased tracer uptake only in the middle portion of the left tibial diaphysis.



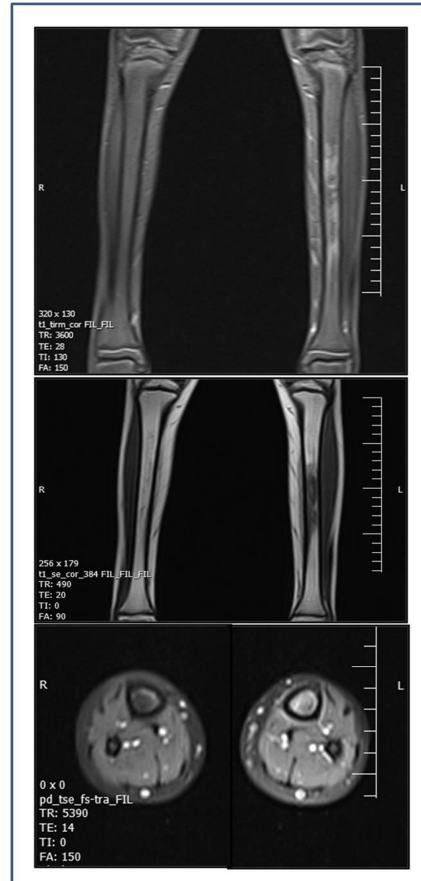
**Fig 3a.** Three-phase bone scan from the legs: Upper row (A): anterior images of the perfusion phase showed mildly more tracer activity in the right leg. Middle row (B): anterior (left) and posterior (right) blood pool images showed increased tracer activity in the middle portion of the left tibial diaphysis. C: Delayed anterior (left) and posterior (right) images showed increased tracer uptake in the middle portion of the left tibial diaphysis.



**Fig 3b.** Whole body images (the same scintigraphy in the Figure 3a) showed mildly increased tracer uptake in the distal portion of the left femur in addition to the left tibial diaphysis.

In his MRI (Figure 4), there was an area of abnormal signal intensity in the medulla of the left tibial diaphysis with signal loss in T1-W images and heterogenous signal intensity in PD images consistent

with bone marrow edema/ infiltration. There was also a mild periosteal reaction around the lesion.



**Fig 4.** MRI PD image showed bone marrow edema with high signal intensity in the left tibial diaphysis (Upper Row). MRI T1 images showed bone marrow edema with low signal intensity in the middle portion of the left tibial shaft (Middle Row). Axial MRI Proton density with fat saturation images showed bone marrow edema with periosteal reaction (Lower Row).

Regarding his history and MRI, bone scan findings were more in favor of active inflammatory process in mentioned regions. In needle biopsy and bone curetting of left and right tibiae, osteonecrosis, mild inflammatory fibrosis, and scattered chronic inflammatory cells consistent with chronic osteomyelitis were reported. No malignant neoplastic tissue was seen.

Patient had frequent periods of bone pain. In every period, symptoms vanished after several weeks. The patient received antibiotics once during these periods. In other occasions, the patient did not receive any antibiotics. In the context of his history osteomyelitis was more probable. In last episode of bone pain,

however, symptoms disappeared by the use of naproxen.

## DISCUSSION

CRMO is a rare type of osteomyelitis, indeed, is an idiopathic inflammatory disorder of bone [6, 7]. It is seen mainly in children and adolescents. It presents with recurrent episodes of symptoms with courses of exacerbation and remissions in different bone locations [6]. Although the etiology of the CRMO is unknown, genetic or autoimmune factors may play a role [6, 8]. Based on many previous bacteriologic investigations, the inflammatory process in CRMO is independent of the bacterial infection [6].

As in the presented case, CRMO involves typically long bones. The clinical presentation is often long-lasting episodes of bone pain, tenderness, and swelling in the region of involvement. Systemic symptoms such as low grade fever and weight loss may be rarely present [7]. There may be nonspecific inflammatory laboratory findings such as mild elevated ESR and CRP [8]. Majority of the lesions in patients with CRMO resolved without complication, however, sometimes it may last for many years [8].

At first, radiographic evaluation of symptomatic site of the bone should be considered [7]. If there is no remarkable abnormality in the X-rays, MRI or bone scintigraphy should be followed. Bone scan is a sensitive method to detect focal pathology in the skeletal system, but may be normal or ambiguous if there is a low activity of inflammatory process [6, 7]. Whole body Bone scan is useful for identifying nearly all symptomatic or silent lesions. It can confirm the multifocal nature of disease and is useful for diagnosis of CRMO [7, 8].

The X-ray findings can be suggestive of CRMO but not pathognomonic [8]. The most common sites of disease involvement are metaphyses of long bones specially tibiae [7]. As in our case, the lesions can also involve the diaphysis.

In early stage of the CRMO, decalcification or osteolytic lesions and in a later stage bone sclerosis can be seen [6]. Periosteal reactions may be seen as well [8]. If bone scan or X-ray findings were unremarkable in the presence of clinical symptoms, we need further diagnostic imaging [6].

CT findings are similar to the radiographic assessment, but it is useful in anatomically difficult locations such as spine, and pelvis [8]. MRI as a choice method is useful for assessment of the bone marrow inflammation extension [6]. Bone marrow edema appears hypointense on T1-weighted images and hyperintense on T2-weighted images [8]. Because of inflammatory process, normal bright signal of the fat containing marrow decreased with

low signal intensity. On T2-weighted images with fat saturation, the signal is bright [6]. Cortical thickening and periosteal reaction may be seen. MRI is useful for assessment of concomitant soft tissue inflammation and determines best location for bone biopsy. MRI is a useful method for the investigation and follow-up in children because of no radiation exposure [6, 8].

Bilateral and symmetric involvement of extremities is a rare finding. In our presented case, bilateral involvement of tibiae was seen. The differential diagnoses are Ewing sarcoma, osteosarcoma, histiocytosis X, neuroblastoma, osteoid osteoma, osteoblastoma and leukemia [6, 8].

Because of overlap of the clinical and imaging findings, CRMO diagnosis is based on exclusion of infectious osteomyelitis and neoplasms [8]. In this case, infectious osteomyelitis was less likely because of the absence of abscess or sinus tract formation. In bone biopsy, there was no finding in favor of neoplastic lesions such as Ewing's sarcoma.

Nonsteroidal anti-inflammatory drugs (NSAIDs) are the best treatment in CRMO [8]. Corticosteroids have some useful effect, but because of their side effects are not used.

## REFERENCES

1. Sadeghi E, Kadivar MR, Ghadimi Moghadam AK, Pooladfar GR, Sadeghi N. Chronic recurrent multifocal osteomyelitis: a case report. *Iran Red Crescent Med J*. 2011 Jan;13(1):47-51.
2. Chiu CK, Singh VA. Chronic recurrent multifocal osteomyelitis of the first metatarsal bone: a case report. *J Orthop Surg (Hong Kong)*. 2009 Apr;17(1):119-22.
3. Tsitsami E, Dermentzoglou V, Moschovi M, Chrousos GP. Chronic recurrent multifocal osteomyelitis with concomitant features of juvenile idiopathic arthritis. *Case Rep Rheumatol*. 2011;2011:210795.
4. Deogaonkar K, Ghandour A, Jones A, Ahuja S, Lyons K. Chronic recurrent multifocal osteomyelitis presenting as acute scoliosis: a case report and review of literature. *Eur Spine J*. 2008 Sep;17 Suppl 2:S248-52.
5. Paim LB, Liphau BL, Rocha AC, Castellanos AL, Silva CA. Chronic recurrent multifocal osteomyelitis of the mandible: report of three cases. *J Pediatr (Rio J)*. 2003 Sep-Oct;79(5):467-70.
6. Buck FM, Treumann TC, Winiker H, Strobel K. Chronic recurrent multifocal osteomyelitis (CRMO) with symmetric involvement of both femora: X-ray, bone scintigram, and MR imaging findings in one case. *J Magn Reson Imaging*. 2007 Aug;26(2):422-6.
7. Khanna G, Sato TS, Ferguson P. Imaging of chronic recurrent multifocal osteomyelitis. *Radiographics*. 2009 Jul-Aug;29(4):1159-77.
8. Quon JS, Dzus AK, Leswick DA. Case study: chronic recurrent multifocal osteomyelitis in the femoral diaphysis of a young female. *Case Rep Radiol*. 2012;2012:515761.