

The comparison between ultrasonography and ^{99m}Tc -DMSA renal scan in estimation of kidney size

Sousan Shafiei, Vahid-Reza Dabbagh, Hamideh Sadra,
Ramin Sadeghi, Seyed Mohsen Seyedi, Narjess Ayati

Nuclear Medicine Research Center, School of Medicine, Mashhad University of Medical Sciences, Mashhad, Iran

(Received 6 April 2015, Revised 19 August 2015, Accepted 20 August 2015)

ABSTRACT

Introduction: Renal length measurement is an important diagnostic clue in several urinary tract abnormalities. Although ultra sonography is the most frequent used modality for renal size estimation, renal diameter assessment by ^{99m}Tc -DMSA scintigraphy is of great value. By now, pointing to the renal size in the ^{99m}Tc -DMSA scintigraphy report has not been recommended by guidelines. If the validity of ^{99m}Tc -DMSA scan for renal size assessment would be established and reported in routine clinical practice, it might be more helpful for diagnostic purposes obviating further modality use in kidney diameter assessment.

Methods: 70 patients (25 males and 45 females) with the age range of 1 month to 78 years old (Mean \pm SD = 18.1 \pm 19.3) were included in the study. The longest axis diameter of each kidney was calculated by ultra sonography and planar ^{99m}Tc -DMSA scintigraphy. The difference in renal size estimation between US and different projections of ^{99m}Tc -DMSA scan was assessed using generalized linear model repeated measurement, pair wise comparison in Post Hoc and Bland-Altman analysis.

Results: 16 (22.9%) reports were interpreted as normal study, while 54 patients had abnormality at least in one kidney. No significant difference was noticed between the kidney diameters in US as compared to the all views of ^{99m}Tc -DMSA scan. Only in the estimation of left kidney size using ^{99m}Tc -DMSA scan, there was significant difference between anterior and posterior oblique views as well as between lateral and posterior oblique views. Mean value of the differences (estimated bias) doesn't differ significantly from 0 on the basis of 1-sample t-test.

Conclusion: ^{99m}Tc -DMSA scintigraphy is an accurate method for renal length measurement with excellent agreement with ultra sonography. Kidney length can be easily measured as a routine processing procedure of a ^{99m}Tc -DMSA scan and not only used for more accurate interpretation of the images but also added to the final report as valuable incremental information.

Key words: ^{99m}Tc -DMSA; Renal scintigraphy; Ultrasonography; Kidney diameter; Renal size

Iran J Nucl Med 2016;24(1):23-28

Published: January, 2016

<http://irjnm.tums.ac.ir>

Corresponding author: Dr. Narjess Ayati, Nuclear Medicine Research Center, Ghaem Hospital, Mashhad University of Medical Sciences, Mashhad, Iran. E-mail: ayatin@mums.ac.ir

INTRODUCTION

Several imaging modalities have been introduced for urinary tract evaluation including plain radiography, ultrasonography (US), intravenous pyelography (IVP), computerized tomography (CT), magnetic resonance imaging (MRI) and renal scintigraphy. Each one has its specific advantages and limitations. An essential part of kidney evaluation is renal size assessment [1]. Some investigators have chosen renal length as a surrogate of organ growth in growing children [2].

US is the initial technique for renal length measurement. It has numerous advantages as a renal assessment tool including availability, safety, non-invasive nature and absence of any ionizing radiation exposure. Also, the ability for examination in real time, tridimensionality, and independency to organ function and respiration phase is the other advantages of this inexpensive modality [3]. Despite these valuable attributes, US has some disadvantages. It is a person dependent instrument without ability to provide a quantitative assessment of renal function, and not sensitive enough to detect all renal scars [4].

^{99m}Tc-dimercaptosuccinic acid (^{99m}Tc-DMSA) scintigraphy is the method of choice for renal cortex imaging, assessing acute renal inflammation, establishing parenchymal injury, evaluation of renal scars (especially in children with Urinary Tract Infection), and estimating the volume of functioning renal mass [2, 4, 5]. It has the potential to estimate renal size with acceptable reproducibility [1]. As this modality is performed in multiple spot views, it would be useful to find the most accurate view for renal diameter assessment.

By now, pointing to the renal size in the ^{99m}Tc-DMSA scintigraphy report has not been recommended by guidelines [6]. Validation of ^{99m}Tc-DMSA scan for renal size assessment has two advantages. It could be used for more accurate ^{99m}Tc-DMSA scintigraphy interpretation. Also it could be added to the ^{99m}Tc-DMSA scan report as valuable incremental information and obviate further modality use for kidney diameter assessment.

This study was conducting to compare renal sizes estimated by ^{99m}Tc-DMSA and US and to find the best view of ^{99m}Tc-DMSA renal study for diameter measurement.

METHODS

This is a cross sectional study on seventy patients data who were referred for ^{99m}Tc-DMSA renal scan to our department from October 2012 to March 2013. Medical records were reviewed retrospectively; when the result of both renal US and ^{99m}Tc-DMSA scan were available, epidemiologic data including age and

sex were obtained. All patients with more than one month gap between US and ^{99m}Tc-DMSA scan were excluded from the study.

The longest axis diameter of each kidney on US was recorded. ^{99m}Tc-DMSA study was undertaken by a dual-head gamma camera (Siemens) 3 hours after tracer injection (Low Energy High Resolution Collimator, 128X128 matrix, 1.26 Zoom factor) in multiple spot views with at least 300000 counts per image.

The administered dose of ^{99m}Tc-DMSA was 0.05 mCi/kg (1.85 MBq/kg) with a dose range of 0.5 to 3 mCi (18.5-111 MBq). The acquisition consisted of 8 planar projections including anterior, posterior, left and right anterior and posterior oblique as well as lateral views. Differential renal function was calculated using geometric mean count of the kidneys in anterior and posterior projections. Renal length was measured on the planar ^{99m}Tc-DMSA images by a nuclear medicine specialist who was blind to renal size on US.

Statistical analysis: All data were recorded in SPSS software (version: 11.5). The difference in renal size estimation between US and different projections of ^{99m}Tc-DMSA scan was assessed by using generalized linear model repeated measurement, pair wise comparison in Post Hoc and Bland-Altman analysis.

RESULTS

70 patients (25 males and 45 females) with the age range of 1 month to 78 years old (Mean \pm SD = 18.1 \pm 19.3) were included in the study.

From 70 patients, 16 (22.9%) reports were interpreted as normal study, while 54 patients had abnormality at least in one kidney.

The mean differential renal function was (57 \pm 27.2) and (52.2 \pm 27.0) for the right and left kidneys respectively. Table 1 showed size of the kidneys in US and different projections of ^{99m}Tc-DMSA scan. Using generalized linear model repeated measurement, pairwise comparison in Post Hoc analysis, no significant difference was noticed between left kidney and right kidney size in US as compared to the all views of ^{99m}Tc-DMSA scan: anterior, posterior, lateral and posterior oblique projections. Only in the estimation of left kidney size using ^{99m}Tc-DMSA scan, there was significant difference between anterior and posterior oblique views as well as between lateral and posterior oblique views.

The differences of US and ^{99m}Tc-DMSA kidney size assessments by Bland-Altman analyses are shown in Figures 1 and 2. Mean value of the differences (estimated bias) doesn't differ significantly from 0 on the basis of 1-sample t-test.

Table 1: Size of right and left kidneys (RK, LK) in ultrasonography (US) and ^{99m}Tc-DMSA renal scan in millimeters.

Imaging Procedure	Abnormal Kidneys		Normal Kidneys		All		
	LK (Mean±SD)	RK (Mean±SD)	LK (Mean±SD)	RK (Mean±SD)	LK (Mean±SD)	RK (Mean±SD)	
US	37-130 (80.5±25.4)	37-130 (80.0±24.0)	48-115 (75.2±19.0)	48-117 (73.8±17.8)	37-130 (82.6±24.3)	37-133 (85/0±24.1)	
DMSA Renal Scan	Posterior view	30.3-124.9 (78.6±26.1)	41.9-152.6 (79.1±25.4)	59.4-117.0 (77.4±16.8)	55.3-103.0 (73.5±14.8)	30.3-127.7 (83.0±23.5)	41.9-152.6 (85.9±24.9)
	Anterior view	42.0-127.5 (80.7±23.8)	42.8-148.8 (78.6±25.6)	58.5-108.8 (75.9±15.6)	55.4-103.9 (74.9±15.0)	42.0-129.8 (83.4±21.7)	42.8-148.8 (86.2±25.1)
	Posterior oblique view	30.9-124.2 (81.0±27.2)	42.0-151.4 (79.6±25.2)	61.9-110.0 (78.9±15.0)	59.3-101.7 (76.2±14.3)	30.9-131.0 (85.0±23.7)	42.0-151.4 (87.3±25.2)
	Lateral view	33.8-120.4 (85.9±23.8)	58.0-151.9 (83.7±23.4)	58.4-107.2 (77.1±15.6)	58-105.8 (75.9±14.5)	33.8-124.5 (86.1±21.0)	58.0-151.9 (87.9±22.8)

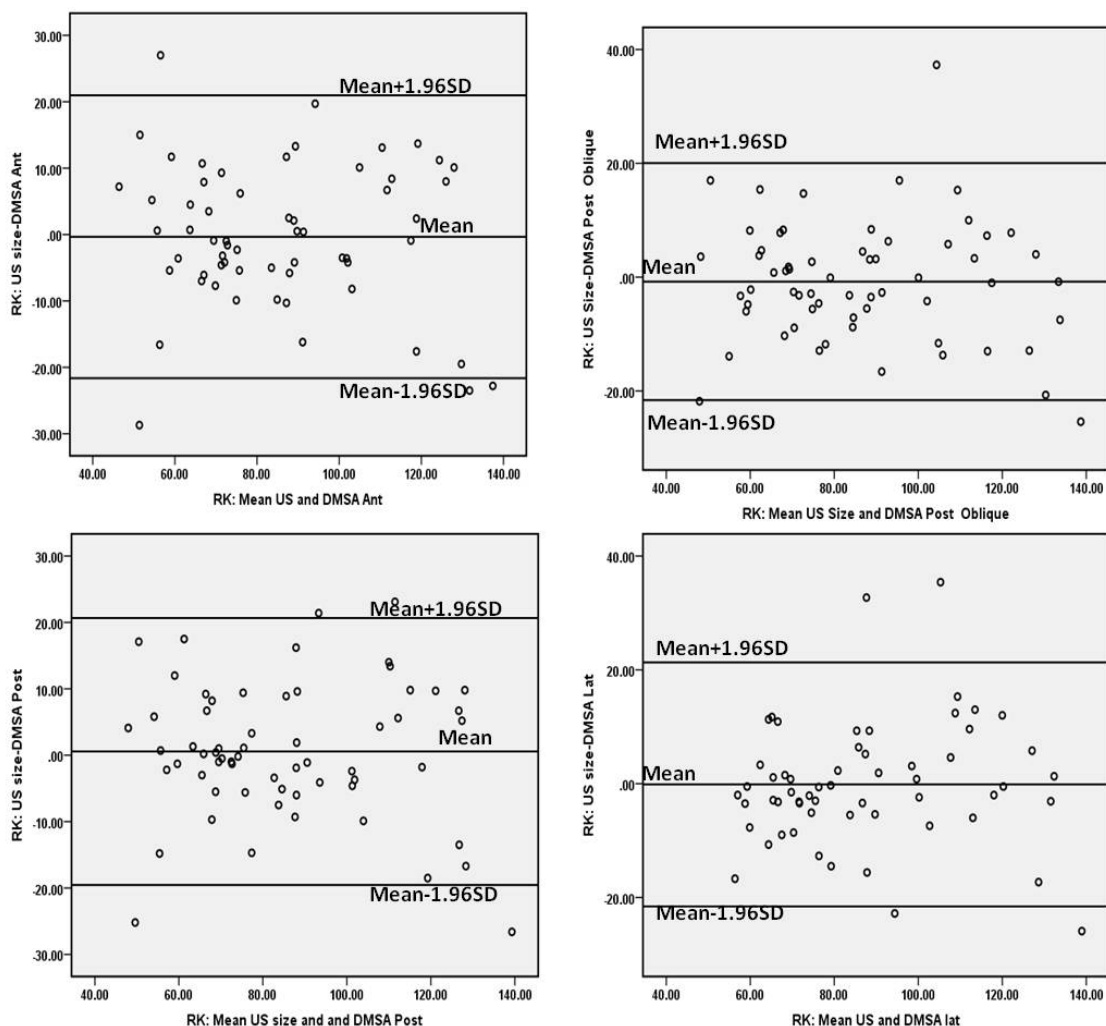


Fig 1. Bland-Altman analysis between US and different DMSA views (Ant: Anterior, Post: Posterior, Lat: lateral) in estimation of right kidney size.

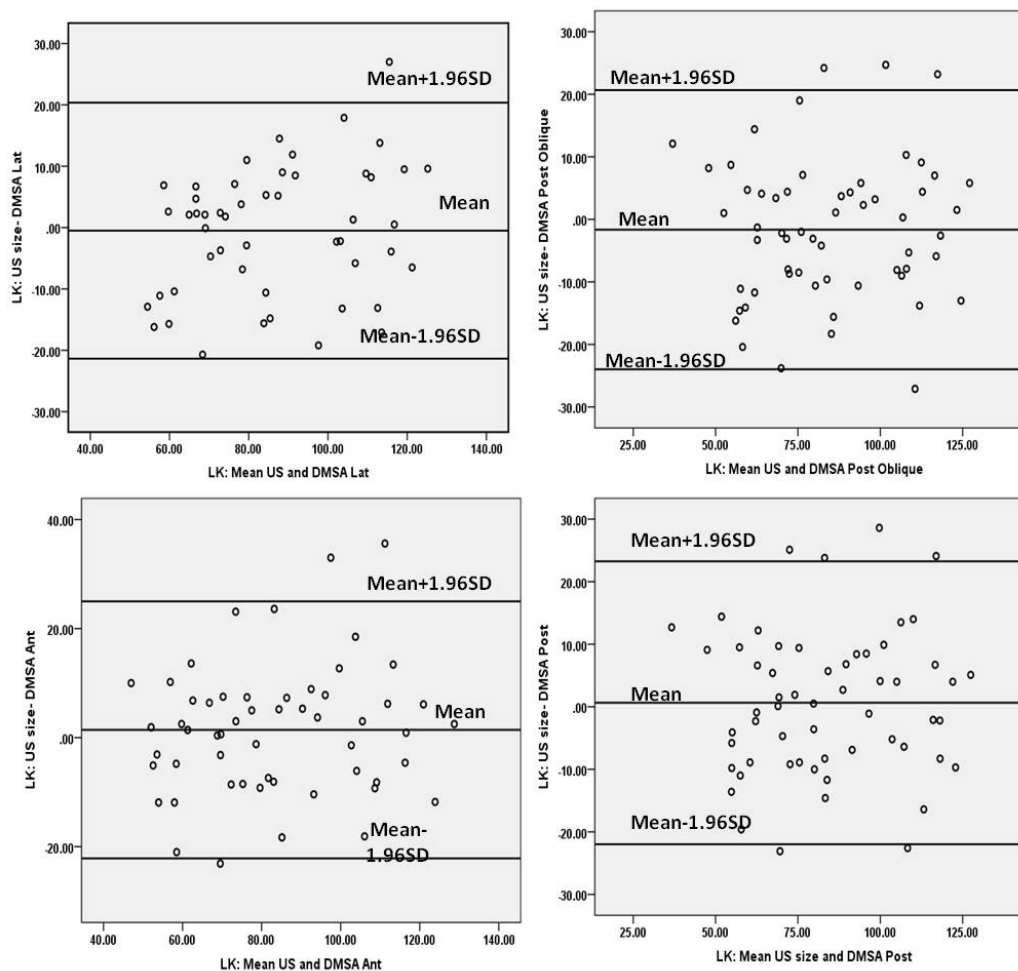


Fig 2. Bland-Altman analysis between US and different DMSA views (Ant: Anterior, Post: Posterior, Lat: lateral) in estimation of left kidney size.

Table 2: Differences (estimated bias) between US and DMSA scan views (1-sample t-test for differences with 0).

Kidney	Difference between US and DMSA Views	Mean	Standard deviation	Limits of agreement (Mean±1.96SD)	P value
Right Kidney	US and Anterior	-0.33	10.87	-21.64 - 20.97	0.81
	US and Posterior	0.57	10.26	-19.54 - 20.68	0.66
	US and Posterior Oblique	-0.78	10.62	-21.60 - 20.04	0.56
	US and Lateral	-0.13	10.94	-21.57 - 21.31	0.92
Left Kidney	US and Anterior	1.42	12.02	-22.15 - 24.99	0.38
	US and Posterior	0.64	11.54	-21.97 - 23.25	0.67
	US and Posterior Oblique	-1.65	11.38	-23.96 - 20.66	0.27
	US and Lateral	-0.50	10.65	-21.37- 20.37	0.74

Table 2 shows Bias (mean difference), Precision (SD) and 95% limits of agreement (mean \pm 1.96SD).

DISCUSSION

Renal length measurement is an important diagnostic clue in several urinary tract abnormalities. By now,

mentioning the renal size in the ^{99m}Tc-DMSA scintigraphy report has not been recommended by guidelines [6]. The current study showed that ^{99m}Tc-DMSA scintigraphy has an acceptable accuracy for renal size estimation with excellent agreement of its all routine projections with ultra sonography. Because of many favorable attributes of

Ultrasonography, it is the initial diagnostic tool in many urinary tract scenarios and the most frequent used modality for renal size estimation. Also in the setting of a segmental defect or a well-defined non-functioning intrarenal lesion, measurement of renal size is not accurate; however, renal diameter assessment by ^{99m}Tc-DMSA scintigraphy is of great value considering following two different indices. First, defining the kidneys length can help to interpret the scan more accurately. Secondly decreased relative ^{99m}Tc-DMSA uptake can be a consequence of abnormal kidney size even in the absence of any functional impairment [7]. The literature review showed that the relative ^{99m}Tc-DMSA uptake corrected for renal size is more accurate in renal function assessment [7]. The other study suggested that longer right kidney than the left, even with less than 10 millimeters difference is a strong predictor of ^{99m}Tc-DMSA scan abnormality [8]. DMSA could be the first option in some indications including urinary tract infection and consequently, renal scar evaluation. If the validity of ^{99m}Tc-DMSA scan for renal size assessment would be established in routine clinical practice, it could be more helpful for diagnostic purposes in comparison to other more objective modalities.

The common imaging protocol for ^{99m}Tc-DMSA imaging is acquisition in multiple planar projections. A study compared renal size in normal ^{99m}Tc-DMSA scan and US in 253 children and found no significant difference between these two modalities in size estimation accuracy [5]. Our result was comparable with this study as we performed the routine planar scans and found high validity of scintigraphic size measurement in comparison with US. However, some studies suggested ^{99m}Tc-DMSA SPECT to measure renal length, volume, and 2D/3D split renal functions with excellent accuracy and high observer reproducibility [9]. Wallin et al. measured the kidney size with planar and SPECT ^{99m}Tc-DMSA scan and compared the results with excised and *in vivo* kidneys. Their results showed that despite about 1.7% overestimation in renal length, renal diameter measurement by scintigraphy (either by planar or SPECT technique) is extremely reliable [10]. The previous studies did not show any remarkable difference between planar and SPECT ^{99m}Tc-DMSA imaging in renal length estimation, so it is suggested using planar technique which is more available, less time consuming and easier to perform as a routine procedure in a nuclear medicine clinic. Reproducibility of a diagnostic test is the other concerning issue. Lin et al. showed that the variability in renal length measurements obtained by ^{99m}Tc-DMSA scan was similar to US with high between observers' correlation [1].

A large group study on 266 patients tried to establish nomograms of renal length in children and found 1

centimeter overestimation of average reported kidney size in ^{99m}Tc-DMSA scan as compared with US [11]. The authors believed that the responsible factor is respiration effect and renal motion during acquisition.

To the extent of our knowledge, there has been no published study comparing the accuracy of different projections of ^{99m}Tc-DMSA scan for renal length estimation. Our data showed that all planar views of ^{99m}Tc-DMSA scan have excellent agreement with US estimated renal size (Figures 1 & 2). However posterior and lateral projections showed better precision in renal length estimation (Table 2)

Rossleigh et al. in a well designed study induced reflux nephropathy in twenty pigs and compared the cortical scar detection and renal length measurement by ^{99m}Tc-DMSA scan, US and pathology examination. According to their data, ^{99m}Tc-DMSA overestimates and US underestimates real pathology size on average 6% and 22%, respectively. Their results showed that ^{99m}Tc-DMSA not only have a significantly higher accuracy for cortical scar detection, but also because of better maximum longitudinal renal axis assessment, is more accurate than US for renal size measurement [12].

By now, pointing to the renal size in the ^{99m}Tc-DMSA scintigraphy report has not been recommended by guidelines [6]. High accuracy, excellent precision and reproducibility of ^{99m}Tc-DMSA scan in renal diameter assessment, makes this modality an excellent alternative for kidney length measure as a routine processing procedure not only used for more accurate interpretation of the images but also to be included to report as a valuable incremental information.

There are some limitations in this retrospective study. We compared the renal length in ^{99m}Tc-DMSA scan to US. US is the most common but not a perfect tool for renal size assessment. Also the USs had been done by different radiologists so our sonographic data may have inter-observer variability bias.

CONCLUSION

^{99m}Tc-DMSA scintigraphy is an accurate method for renal length measurement with excellent agreement with ultra sonography. This method could not challenge the ultrasound however can provide additional data on renal ^{99m}Tc-DMSA scan. Kidney length can be easily measured as a routine processing procedure of a ^{99m}Tc-DMSA scan not only used for more accurate interpretation but also to be added to the final report as valuable incremental information.

REFERENCES

1. Lin E, Connolly LP, Zurakowski D, DiCanzio J, Drubach L, Mitchell K, Tetrault T, Laffin SP, Treves

- ST. Reproducibility of renal length measurements with ^{99m}Tc-DMSA SPECT. *J Nucl Med.* 2000 Oct;41(10):1632-5.
- Kim BW, Song MK, Chung S, Kim KS. Evaluation of kidney size in children: a pilot study of renal length as a surrogate of organ growth. *Korean J Pediatr.* 2012 Feb;55(2):54-7.
 - Otiv A, Mehta K, Ali U, Nadkarni M. Sonographic measurement of renal size in normal Indian children. *Indian Pediatr.* 2012 Jul;49(7):533-6.
 - Prasad MM, Cheng EY. Radiographic evaluation of children with febrile urinary tract infection: bottom-up, top-down, or none of the above? *Adv Urol.* 2012;2012:716739.
 - Lobo Sotomayor G, Ladrón de Guevara Hernández D, Arnello Viveros F, Pérez Rivera A, Jiménez Jorquera C. Renal size in children with normal renal ^{99m}Tc-DMSA scan: building a nomogram with scintigraphic length. *Rev Esp Med Nucl.* 2004 Mar-Apr;23(2):102-5.
 - Piepsz A, Colarinha P, Gordon I, Hahn K, Olivier P, Roca I, Sixt R, van Velzen J; Paediatric Committee of the European Association of Nuclear Medicine. Guidelines for ^{99m}Tc-DMSA scintigraphy in children. *Eur J Nucl Med.* 2001 Mar;28(3):BP37-41.
 - Estorch M, Torres G, Camacho V, Tembl A, Prat L, Mena E, Flotats A, Carrió I. Individual renal function based on ^{99m}Tc dimercaptosuccinic acid uptake corrected for renal size. *Nucl Med Commun.* 2004 Feb;25(2):167-70.
 - Khazaei MR, Mackie F, Rosenberg AR, Kainer G. Renal length discrepancy by ultrasound is a reliable predictor of an abnormal DMSA scan in children. *Pediatr Nephrol.* 2008 Jan;23(1):99-105.
 - Cao X, Zurakowski D, Diamond DA, Treves ST. Automatic measurement of renal volume in children using ^{99m}Tc dimercaptosuccinic acid SPECT: normal ranges with body weight. *Clin Nucl Med.* 2012 Apr;37(4):356-61.
 - Wallin L, Thörne J, Palmer J, Bajc M. Kidney size estimation in piglets using dimercaptosuccinic acid (DMSA) scintigraphy. *Clin Physiol.* 1997 Nov;17(6):591-7.
 - Sisayan RM, Rossleigh MA, Mackey DW. Nomograms of renal length in children obtained from DMSA scintigraphy. *Clin Nucl Med.* 1993 Nov;18(11):970-3.
 - Rossleigh MA, Farnsworth RH, Leighton DM, Yong JL, Rose M, Christian CL. Technetium-99m dimercaptosuccinic acid scintigraphy studies of renal cortical scarring and renal length. *J Nucl Med.* 1998 Jul;39(7):1280-5.