

Sentinel node mapping for early breast cancer patients using ^{99m}Tc -phytate: Single center experience on 165 patients

Vahid Reza Dabbagh Kakhki¹, Ali Jangjoo², Alireza Tavassoli³,
Mahdi Asadi², Keyvan Sadri¹, Asihsadat Fatahi Masoom³,
Mostafa Mehrabibahar², Bahram Memar⁴, Mojtaba Ansari⁵, Ramin Sadeghi¹

¹Nuclear Medicine Research Center, Imam Reza Hospital, Faculty of Medicine, Mashhad University of Medical Sciences, Mashhad, Iran.

²Surgical Oncology Research Center, Imam Reza Hospital, Faculty of Medicine, Mashhad University of Medical Sciences, Mashhad, Iran.

³Endoscopic and Minimally Invasive Surgery Research Center, Faculty of Medicine, Ghaem Hospital, Mashhad University of Medical Sciences, Mashhad, Iran.

⁴Pathology Department, Imam Reza Hospital, Faculty of Medicine, Mashhad University of Medical Sciences, Mashhad, Iran

⁵Nuclear Medicine Department, Imam Hossein Hospital, Shahid Beheshti Medical University, Tehran, Iran.

(Received 29 September 2012, Revised 20 October 2012, Accepted 26 October 2012)

ABSTRACT

Introduction: Several radiotracers are being used for sentinel node mapping in patients with breast cancer. In the current study, we reported our experience with ^{99m}Tc Phytate for sentinel node mapping in Mashhad University of Medical Sciences.

Methods: All breast cancer patients who underwent sentinel node mapping using ^{99m}Tc Phytate were included. All patients received intradermal peri-areolar injection of 0.5 mCi/0.1cc ^{99m}Tc Phytate. Lymphoscintigraphy was performed for 145 patients 5-10 minutes post-injection. The sentinel nodes were found during surgery using a hand-held gamma probe as well as blue dye technique.

Results: In total 165 patients were evaluated. Lymphoscintigraphy showed axillary sentinel nodes in 135 out of 145 patients (93%) following imaging. At least one sentinel node could be detected in all these 135 patients during surgery. In the remaining 10 patients with sentinel node non-visualization, 5 had sentinel node harvesting failure during surgery. Median number of sentinel nodes on the lymphoscintigraphy images was 1. Sentinel node detection rate was 95% (157/165). In the 8 patients with sentinel node harvesting failure, 7 had pathologically involved axilla. Median number of harvested sentinel nodes was 1. Mean sentinel node to background count ratio was 10 ± 2 .

Conclusions: ^{99m}Tc Phytate is an effective and highly successful radiotracer for sentinel node mapping. Sentinel node can be visualized in a short time after ^{99m}Tc Phytate injection on the lymphoscintigraphy images. The sentinel to background count during surgery is high which results in more convenient sentinel node harvesting and high detection rate.

Key words: Tc- 99m Phytate; Lymphoscintigraphy; Breast cancer; Sentinel node; Detection rate

Iran J Nucl Med 2012;20(2):25-29

Corresponding author: Dr Ramin Sadeghi, Nuclear Medicine Research Center, Faculty of Medicine, Mashhad University of Medical Sciences, Mashhad, Iran. E-mail: sadeghir@mums.ac.ir

INTRODUCTION

Sentinel node mapping is considered the preferred method for axillary staging in early stage of breast cancer [1-3]. The sentinel node concept is based on orderly dissemination of tumor cells in a lymphatic basin: the first lymph node (or nodes) receiving the lymph flow from a tumor can be considered representative of the whole basin [4, 5].

Sentinel node mapping can be performed using blue dye or radiotracer alone or in combination. Couple of radiotracers has been used for this purpose with almost comparable results [6, 7]. In Iran, two radiotracers are currently in use: 99m-Tc Phytate [8] and 99m-Tc-Antimony Sulfide Colloid [9]. In Mashhad University of Medical Sciences, we started our validation phase of sentinel node mapping using 99m-Tc Antimony Sulfide Colloid with excellent results in 2002 [10]. For 7 years, we used this radiotracer exclusively for sentinel node mapping. After encountering several labeling shortcoming with this radiotracer [9], we started to use 99m-Tc Phytate.

In the current study, we reported our experience in Mashhad University of Medical Sciences with this radiotracer for sentinel node mapping in patients with breast cancer.

METHODS

All breast cancer patients who underwent sentinel node mapping using 99m-Tc Phytate were included. The time span of the study was from December 2009 till September 2012. Overall sample size of the study was 165 patients. On the day of surgery patients were sent to Nuclear Medicine Department for radiotracer injection. All patients received intradermal peri-areolar injection of 0.5 mCi 99m-Tc Phytate in 0.1cc volume.

After injection of the radiotracer, gentle massage was applied for 1 minute. Lymphoscintigraphy was also performed for 145 patients (with a dual head E.CAM Siemens gamma camera using 140 KeV photopeak and low energy high resolution collimator). Imaging

was performed in Lateral and Anterior views (5 min/image) 5 to 15 minutes post injection. Outline of the patients was imaged using the Scatterogram method as described by Momennezhad et al [11].

The sentinel nodes were found during surgery using a hand-held gamma probe (RMD navigator or Europrobe) as well as blue dye technique. The time of surgery was 1-4 hours post injection of the radiotracer. For blue dye method patients were injected with Methylene blue (in 143 patients) after induction of anesthesia with sub-dermal injection. Harvested sentinel nodes were sent to the pathologist for frozen section. Axillary lymph node dissection was performed in patients with positive sentinel nodes.

Detection (success) rate of sentinel node mapping was evaluated in different groups of patients. Continuous variables were expressed as mean \pm SD. Chi-square test (or corresponding exact test) was used for comparison between groups. All statistical analyses were performed by SPSS 11.5 and p-values less than 0.05 were considered statistically significant.

RESULTS

Overall 170 early breast cancer patients were injected with 99m-Tc Phytate. Due to defective labeling in the first five patients, sentinel node mapping was not successful by radiotracer method. We excluded these five patients from the final analysis. In total 165 patients were evaluated. Table 1 shows the characteristics of the patients.

Lymphoscintigraphy showed axillary sentinel nodes in 135 out of 145 patients (93%) following imaging. Figure 1 and 2 show lymphoscintigraphy images of one of our patients. At least one sentinel node could be detected in all these 135 patients during surgery. In the remaining 10 patients with sentinel node non-visualization, 5 had sentinel node harvesting failure during surgery. Median number of sentinel nodes on the lymphoscintigraphy images was 1 (range 1-3).

Table 1. Characteristics of the included patients.

Number of patients	Age of the patients	Histology	Type of biopsy	Tumor size
165	45 \pm 14	Ductal: 121 Lobular: 32 Other: 12	Core needle: 112 Excisional: 53	2.1 \pm 1.4

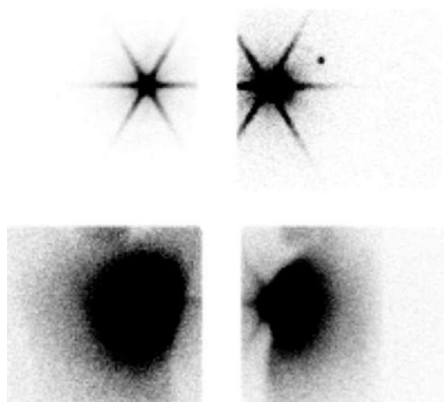


Figure 1. Anterior (right) and Lateral (left) lymphoscintigraphy images of a patient performed 5 minutes after radiotracer injection. Images in the bottom are scattergrams of the corresponding lymphoscintigraphy images. Note the sentinel node on the lateral image which is not apparent on the anterior view due to superimposition of the injection site.

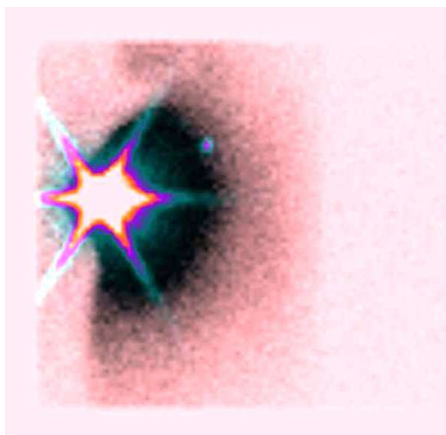


Figure 2. Overlaid lymphoscintigraphy and scattergram images of the patient presented in Figure 1(Lateral view).

Sentinel node detection rate was 95% (157 out of 165 patients). In the 8 patients with sentinel node harvesting failure 7 had pathologically involved axilla. Median number of harvested sentinel nodes was 1 (range 1-3). Mean sentinel node to background count ratio was 10 ± 2 (range 5.5 to 15). Sentinel nodes were pathologically involved in 45 patients in whom axillary dissection was performed.

There were statistically significant differences between successful and unsuccessful sentinel node

mapping surgeries and axillary involvement as well as sentinel node visualization ($p < 0.001$).

DISCUSSION

Various radiotracers are currently in use for sentinel node mapping of the patients with breast cancer. These radiotracers are different in particle size [12]. ^{99m}Tc Phytate has been used for reticulo-endothelial system imaging, forming colloid in vivo after reaction with calcium ions [13]. This radiotracer has been used for lymphoscintigraphy too. The ability to image lymphatic system was attributed to formation of colloid upon contact with calcium in the lymphatics [14]. It has also been used for sentinel node mapping in various cancers including breast cancer, melanoma, and gynecological malignancies [8, 15]. An interesting characteristics of ^{99m}Tc Phytate which is very desirable for sentinel node mapping is trapping of this tracer in the first echelon nodes and little progress into the distal lymph nodes [16]. Our result was also consistent with this concept as the median number of sentinel nodes in our patients was 1.

The particle size of ^{99m}Tc Phytate after interaction with ionized Calcium is reported to be 100-200 nm [17]. This particle size is much larger than ^{99m}Tc Antimony Sulfide Colloid. Considering this fact, it could be anticipated that movement of ^{99m}Tc phytate in the lymphatic system to be slow. However, we found very high sentinel node visualization rate on the lymphoscintigraphy imaging (conducted 5-10 minutes after radiotracer injection) which was fairly rapid compared to ^{99m}Tc Antimony Sulfide Colloid [10, 18]. Tavares et al also reported their experience with ^{99m}Tc Phytate for sentinel node mapping and had similar results. They suggested rapid migration of low molecular weight molecules before interaction with ionized Calcium as the reason for rapid visualization of sentinel nodes [16].

We also had very high target to background ratio (sentinel to background count ratio) during surgery. In accordance to our results, Tavares et al also reported very high sentinel to background ratio and attributed this to low concentration of interstitial Calcium ion which can lead to slow formation of colloid and in turn can cause rapid clearance of ^{99m}Tc Phytate from background [16]. This high target to background ratio can be very useful for inexperienced surgeons since finding and harvesting of the sentinel nodes would be easier. Very high detection rate (95%) in our group of patients is in accordance to other groups such as Eftekhari et al (93%) [8], Tavares et al (93%) [15], and Takei et al (95%) [19], also shows the ease of sentinel node detection by surgeons.

Sentinel node non-visualization on the pre-operative lymphoscintigraphy images as well as axillary lymph node involvement was predictors of sentinel node harvesting failure during surgery in the current study. This shows the importance of pre-operative lymphoscintigraphy imaging since the surgeons can be warned about possible sentinel node harvesting failure before surgery. Axillary involvement can cause sentinel node non-visualization due to severe replacement of the sentinel node structure by the tumoral tissues [20, 21].

One of the main advantages of 99m-Tc Phytate over 99m-Tc Antimony Sulfide Colloid is easy preparation of this radiotracer which does not require heating in boiling water. The kit could be prepared in 15 minutes and is highly stable [8, 22]. However, preparation of 99m-Tc Phytate needs extreme caution not to let air in the kit during the labeling process. We experienced defective labeling in five patients with sentinel node detection failure due to presence of air in the kit during labeling. The kits should have negative pressure inside which can be checked by concave shape of the kit cap upon inspection. Another important advantage is low volume of the final labeled 99m-Tc Phytate as compared to 99m-Tc Antimony Sulfide Colloid. Preparation of 99m-Tc Phytate needs only addition of 99m-Tc Perchnetate in to the kit which can decrease the volume of final preparation causing less discomfort for the patient. In contrast, 99m-Tc Antimony Sulfide Colloid needs addition of Phosphate buffer in the volume of at least 1 mL with resulting higher volume of labeled kit solution.

In our study, we didn't evaluate the false negative rate of sentinel node mapping using 99m-Tc Phytate and this can be considered a limitation for our study.

CONCLUSION

99m-Tc Phytate is an effective and highly successful radiotracer for sentinel node mapping. Sentinel node can be visualized in a short time after 99m-Tc Phytate injection by lymphoscintigraphy. The sentinel to background count during surgery is high which results in more convenient sentinel node harvesting and high detection rate.

REFERENCES

1. Wiatrek R, Kruper L. Sentinel lymph node biopsy indications and controversies in breast cancer. *Maturitas*. 2011 May;69(1):7-10.
2. Kaviani A, Noveiry BB, Noaparast M. Sentinel lymph node biopsy in management of early breast cancer: Is it rational to omit blue dye injection? *Surgery*. 2012 Jul;152(1):140.

3. Iida S, Haga S, Yamashita K, Yanagihara K, Kurita T, Murakami R, Kumita S, Tsuchiya S, Furukawa K, Uchida E. Evaluation of sentinel lymph node biopsy in clinically node-negative breast cancer. *J Nippon Med Sch*. 2011;78(2):96-100.
4. Bekker J, Meijer S. The historical perspective of the sentinel lymph node concept. *Ned Tijdschr Geneesk*. 2008 Jan 5;152(1):38-45.
5. Carmon M, Olsha O, Schechter WP, Raveh D, Reinus C, Hershko DD, Beller U, Golomb E. The "Sentinel Chain": a new concept for prediction of axillary node status in breast cancer patients. *Breast Cancer Res Treat*. 2006 Jun;97(3):323-8.
6. Sadeghi R, Zakavi SR, Forghani MN, Aryana K, Kakhki VR, Ayati NK, Shandiz FH, Ghavamnasiri MR, Keshtgar M. The efficacy of Tc-99m sestamibi for sentinel node mapping in breast carcinomas: comparison with Tc-99m antimony sulphide colloid. *Nucl Med Rev Cent East Eur*. 2010;13(1):1-4.
7. Sadeghi R, Forghani MN, Zakavi SR, Jangjoo A, Shabani GA, Kakhki VRD. The need for skin pen marking for sentinel lymph node biopsy: A comparative study. *Iran J Nucl Med*. 2008;16(2):23-7.
8. Eftekhari M, Beiki D, Fallahi B, Arabi M, Memari F, Gholamrezaezhad A, Esmaili J, Akhzari F, Fard-Esfahani A. Assessment the diagnostic accuracy of sentinel lymph nodes lymphoscintigraphy using Technetium-99m phytate in breast cancer. *DARU*. 2009;17(2):83-7.
9. Sadri K, Ayati NK, Shabani G, Zakavi SR, Sadeghi R. Sentinel node detection failure due to defective labeling and large particle size of Tc-99m antimony sulfide colloid. *Iran J Nucl Med*. 2011;19(1):6-11.
10. Aliakbarian M, Memar B, Jangjoo A, Zakavi SR, Reza Dabbagh Kakhki V, Aryana K, Forghani MN, Sadeghi R. Factors influencing the time of sentinel node visualization in breast cancer patients using intradermal injection of the radiotracer. *Am J Surg*. 2011 Aug;202(2):199-202.
11. Momenzad M, Zakavi SR, Dabbagh Kakhki VR, Jangjoo A, Ghavamnasiri MR, Sadeghi R. Scatterogram: a method for outlining the body during lymphoscintigraphy without using external flood source. *Radiol Oncol*. 2011 Sep;45(3):184-8.
12. Eshima D, Fauconnier T, Eshima L, Thornback JR. Radiopharmaceuticals for lymphoscintigraphy: including dosimetry and radiation considerations. *Semin Nucl Med*. 2000 Jan;30(1):25-32.
13. Subramanian G, McAfee JG, Mehta A, Blair RJ, Thomas ED. Tc-99m stannous phytate: a new in vivo colloid for imaging the reticuloendothelial system. *J Nucl Med*. 1973;14:459.
14. Alavi A, Staum MM, Shesol BF, Bloch PH. Technetium-99m stannous phytate as an imaging agent for lymph nodes. *J Nucl Med*. 1978 Apr;19(4):422-6.
15. Tavares MG, Sapienza MT, Galeb NA Jr, Belfort FA, Costa RR, Osório CA, Góes JC, Endo IS, Soares J Jr, Lewin S, Marone MM. The use of 99mTc-phytate for sentinel node mapping in melanoma, breast cancer and vulvar cancer: a study of 100 cases. *Eur J Nucl Med*. 2001 Nov;28(11):1597-604.
16. Ege GN, Warbick A. Lymphoscintigraphy: a comparison of 99Tc(m) antimony sulphide colloid and

- 99Tc(m) stannous phytate. *Br J Radiol.* 1979 Feb;52(614):124-9.
17. Campbell J, Bellen JC, Baker RJ, Cook DJ. Technetium-99m calcium phytate--optimization of calcium content for liver and spleen scintigraphy: concise communication. *J Nucl Med.* 1981 Feb;22(2):157-60.
 18. Sadeghi R, Forghani MN, Memar B, Rajabi Mashhadi MT, Dabbagh Kakhki VR, Abdollahi A, Zakavi SR. How long the lymphoscintigraphy imaging should be continued for sentinel lymph node mapping? *Ann Nucl Med.* 2009 Aug;23(6):507-10.
 19. Takei H, Suemasu K, Kurosumi M, Ninomiya J, Horii Y, Inoue K, Tabei T. 99mTc-phytate is better than 99mTc-human serum albumin as a radioactive tracer for sentinel lymph node biopsy in breast cancer. *Surg Today.* 2006;36(3):219-24.
 20. Abdollahi A, Jangjoo A, Dabbagh Kakhki VR, Rasoul Zakavi S, Memar B, Naser Forghani M, Mehrabibahar M, Sadeghi R. Factors affecting sentinel lymph node detection failure in breast cancer patients using intradermal injection of the tracer. *Rev Esp Med Nucl.* 2010 Mar-Apr;29(2):73-7.
 21. Dordea M, Colvin H, Cox P, Pujol Nicolas A, Kanakala V, Iwuchukwu O. Clinical and histopathological factors affecting failed sentinel node localization in axillary staging for breast cancer. *Surgeon.* 2012.
 22. Arzoumanian A, Rosenthal L, Seto H. Clinical comparison of 99mTc-labeled preformed phytate colloid and sulfur colloid: concise communication. *J Nucl Med.* 1977 Feb;18(2):118-20.