

## How to manage patients with undetectable thyroglobulin but thyroid residue after radioiodine ablative therapy in differentiated thyroid carcinoma, retreatment or observation?

Babak Fallahi<sup>1</sup>, Armaghan Fard-Esfahani<sup>1</sup>, Alireza Emami-Ardekani<sup>1</sup>,  
Somayeh Sahari<sup>1</sup>, Davood Beiki<sup>1</sup>, Arman Hassanzadeh-Rad<sup>1</sup>,  
Seyed Mohammad Abedi<sup>2</sup>, Parham Geramifar<sup>1</sup>, Mohammad Eftekhari<sup>1</sup>

<sup>1</sup>Research Center for Nuclear Medicine, Shariati Hospital, Tehran University of Medical Sciences, Tehran, Iran

<sup>2</sup>Department of Radiology, Faculty of Medicine, Mazandaran University of Medical Sciences, Sari, Iran

(Received 21 May 2016, Revised 6 August 2016, Accepted 8 August 2016)

### ABSTRACT

**Introduction:** Differentiated thyroid carcinoma (DTC) follow-up after thyroidectomy and radioiodine-ablation is performed mainly by thyroglobulin (Tg), diagnostic iodine-131 whole body scan (DxWBS) and sonography. Some patients with undetectable Tg have thyroid-bed uptake after ablation in whom decision making regarding the need for retreatment is still controversial.

**Methods:** In this study, we enrolled DTC patients with undetectable Tg but small thyroid residue in six-month-DxWBS following first radioiodine-ablation. Patients with detectable Tg, high TgAb, suspicious neck lymphadenopathy in sonography and metastasis were excluded. Ninety four patients were placed in two groups of cohort, i.e., radioiodine-retreatment group (n=36) versus observation (untreated) group (n=58). After six months, the clinical outcome was compared by evaluating DxWBS, Tg, TgAb and sonography.

**Results:** DxWBS showed sustained thyroid remnant in 47.2% of retreated patients while 34.5% of untreated group revealed negative DxWBS over the next period of follow-up. Also, only 6 cases (16.7%) in retreatment group and 12 cases (20.7%) in observation group revealed an additional finding other than local faint RAI uptake, including detectable serum Tg, rising TgAb or suspicious ultrasound finding, favoring no significant difference of the outcome as well as relative risk of new finding incidence between treated and untreated patients (CI 95% for relative risk: 0.58-2.41; p=0.630).

**Conclusion:** Regarding sonologic and laboratory follow-up evidences, RAI-retreatment shows no significant advantage over observation in DTC patients with Tg negative, remnant positive DxWBS. In addition, residual thyroid tissue was completely disappeared in about one third of patients without retreatment.

**Key words:** Undetectable thyroglobulin; Differentiated thyroid carcinoma; Retreatment; Thyroid remnant; Radioiodine; Follow-up without treatment

Iran J Nucl Med 2017;25(1):51-59

Published: January, 2017

<http://irjnm.tums.ac.ir>

**Corresponding author:** Dr Armaghan Fard-Esfahani, Research Center for Nuclear Medicine, Shariati Hospital, North Kargar Ave., 1411713135, Tehran, Iran. E-mail: fardesfa@sina.tums.ac.ir

## INTRODUCTION

The goal of treatment in differentiated thyroid carcinoma (DTC) is to eliminate any evidence of disease, documented by absence of visible radioactive iodine (RAI) uptake on subsequent diagnostic whole body I-131 scan (DxWBS) concomitant with undetectable serum thyroglobulin (Tg) level [1, 2].

Thyroglobulin is a thyroid-specific glycoprotein synthesized and secreted by differentiated thyroid tissue. Following thyroidectomy and radioiodine therapy, serum Tg levels provide a sensitive and specific tumor marker for residual and recurrent/metastatic disease [3, 4]. The amount of Tg elevation correlates with the magnitude of residual/metastatic disease and with the tumor subtype [5]. It is frequently proposed that stimulated Tg levels are sufficient as the sole surveillance test and when Tg is undetectable, the disease is usually considered under control [3, 6-10]. It is shown that thyroglobulin is a tumor marker that is valuable even in patients with remnant thyroid tissue [11].

In the management of DTC, it is not unusual to encounter patients with only residual thyroid tissue on post- ablative DxWBS, while Tg is undetectable [12, 13]. Considering that low Tg level is an indicator of good prognosis, and only about 2% of patients with undetectable stimulated Tg may have recurrences over the next 3-5 years [14], delivering unnecessary radiation by repeated I-131 therapy to the patients with only remained thyroid bed uptake despite undetectable Tg level is controversial. There have been very limited studies to fully evaluate this issue [15, 16]. As ablative effect of radioiodine can be achieved over extended months, we designed a cohort with two groups of patients with and without RAI-retreatment scheduling an additional 6-month follow-up to evaluate the efficacy of radioiodine retreatment in patients demonstrating only remnant uptake in the DxWBS with undetectable Tg (Tg<1 ng/ml) at the end of the first 6-month period of follow-up.

## METHODS

### Patients and follow-up management

Ninety four patients, 14 male, 80 female, aged 18-73 years (mean age: 40.4±12.0) with DTC, who underwent radioiodine ablation after thyroidectomy and showed only small thyroid bed remnant on the 6-month-post-ablation DxWBS with undetectable off-T4 serum Tg level and normal sonographic results, were enrolled in the study. Presence of I-131 uptake only in the thyroid bed with activity less than nasopharyngeal region, without any other abnormal activity on DxWBS, was required to include the patient in the study.

The ablation I-131 dose was selected according to the post-operative pathologic findings and risk criteria (100-150 mCi/3700-5550 MBq).

Sonography results were considered normal, if there was no evidence of residual thyroid tissue accompanied by the absence of any lymph node or just the presence of the small lymph nodes showing reactive appearance. The presence of lymph nodes with a number of certain sonographic features (including microcalcifications, hilum infiltration and hypervascularity) was considered suspicious and was candidate for tissue sampling.

Patients with any evidence of active disease including anti-Tg antibody (TgAb) higher than 100 mIU/mL, suspicious neck mass, lymph node or thyroid residue in sonography or evidence of local or distant metastasis including the presence of any focus of abnormal I-131 uptake in the locations other than thyroid bed were excluded from the study. All evaluations were performed while the patient was off-T4 and frankly hypothyroid.

In this cohort study the patients were divided into two groups according to the physician's decision; the first was the retreatment group with additional dose of RAI, while the second group, assigned as observation group, included cases undergoing observation without any additional therapeutic intervention. Retreatment radioiodine dose was 150 mCi (5550 MBq) in all patients.

The patients in both groups were reevaluated after another six months follow-up and the clinical, laboratory and imaging findings, i.e. I-131 DxWBS, serum Tg, TgAb levels and sonography, were compared by expert physicians.

Remission, on the basis of follow-up reevaluations, was defined as an absence of visible RAI uptake on a subsequent DxWBS concomitant with normal sonography, undetectable stimulated serum Tg and normal ranged TgAb.

Our study design was reviewed and approved by Ethics Committee of Tehran University of Medical Sciences. All study participants were briefed on the purpose and methods of the study and were requested to sign the informed consent form prior to enrollment.

### Radioiodine whole-body scan

I-131 DxWBS was performed after adequate withdrawal of thyroid hormone (T4) suppressive therapy in order to stimulate TSH to reach to a level above 30 mIU/mL. For this purpose, T4 was discontinued for one month and was replaced by triiodothyronine (T3) for two weeks (25µg every 12 hours). Subsequently T3 was stopped for the next two weeks and the patients were asked to follow a low-iodine diet for 2 weeks before the DxWBS. 48-72 h

following oral administration of approximately 148-185 MBq (4-5 mCi/148-185 MBq) I-131, whole body scans were obtained using a high-energy parallel-hole collimator centered at 364 keV with a 20% energy window using gamma camera (Dual Head Genesis, ADAC company), and scan speed of 3 cm/min. If required, spot images, 15 minutes per view were also obtained. Interpretation was made by two expert nuclear medicine physicians.

#### Tg, anti-Tg antibody, and TSH measurement

Serum TSH and Tg levels were measured using an immunoradiometric assay (IRMA) kit (IZOTOP, Budapest, Hungary). Antithyroglobulin antibody (Anti-Tg Ab) was measured by a competitive radioimmunoassay (RIA) kit (IZOTOP, Budapest, Hungary) with the functional sensitivity of about 30 IU/ml. The given normal range was less than 100 IU/mL. For the results to be comparable, all the Tg and TgAb monitoring were made by the same laboratory center via the same assays and serum samples. Tg and TgAb values evaluated after first ablative treatment were rechecked to reconfirm the correctness of patients enrollment.

#### Statistical analyses

The statistical software package, SPSS (i.e. version 19.0, Chicago, Illinois, USA), was used for data analyses. To compare quantitative data with normal distribution student t-test was used. The chi-square test was applied to determine an association between qualitative variables in two groups. Also, risk ratio (RR) of positive findings in observation group vs. retreatment group was estimated with 95% confidence interval (CI95%). For all statistical analyses, a P-value of less than 0.05 was considered as statistically significant.

#### RESULTS

From 94 cases, 36 (38.3%) were located in retreatment group including 6 males and 30 females; mean age: 39.22±11.03, and 58 (61.7%) patients including 8 males and 50 females; mean age: 41.19±12.56 were allocated in observation group. Baseline variables including age, sex, tumor size, first ablative RAI dose as well as pathologic type and other characteristics (i.e. the presence of capsular, vascular or lymphatic invasion) were not different in two groups (Table 1).

**Table 1:** Baseline variables in two groups of studied patients.

Variable	Retreatment Group	Observation Group	Statistical Significance
<b>Patients Number</b>	36	58	
<b>Age (yr)</b>	39.22±11.03	41.19±12.56	0.442 NS
<b>Sex</b>	Female	30 (83.3%)	0.704 NS
	Male	6 (16.7%)	
<b>Pathology</b>	Papillary	31 (86.1%)	0.132 NS
	Non-Papillary	5 (13.9%)	
<b>Primary Tumor Size (Cm)</b>	1.81±1.63	2.15±1.30	0.327 NS
<b>Capsular Invasion</b>	9 (25.0%)	17 (29.3%)	0.650 NS
<b>Vascular Invasion</b>	8 (22.2%)	6 (10.3%)	0.116 NS
<b>Lymphatic Invasion</b>	3 (8.3%)	13 (22.4%)	0.077 NS
<b>Stage</b>	Stage I	31 (86.1%)	0.651 NS
	Stage II	4 (11.1%)	
	Stage III	1 (2.8%)	
<b>First ablative I-131 Dose (mCi)</b>	100 (3700 MBq)	21 (58.3%)	0.101 NS
	125 (4625 MBq)	5 (13.9%)	
	150 (5550 MBq)	10 (27.8%)	

NS: Not significant

**Table 2:** Imaging and laboratory findings in retreatment and observation groups of patients after 12 months follow-up.

Follow-up findings	Retreatment Group (N= 36)	Observation Group (N= 58)	RR of Positive Result (95% CI)	Significance	
<b>I-131 DxWBS</b>	Positive	17 (47.2%)	38 (65.5%)	1.58 (0.95-2.62)	0.080 NS
	Negative	19 (52.8%)	20 (34.5%)		
<b>Serum thyroglobulin</b>	≥ 1ng/ml	1 (2.8%)	2 (3.4%)	1.15 (0.23-5.84)	0.857 NS
	< 1ng/ml	35 (97.2%)	56 (96.6%)		
<b>Serum TgAb</b>	≥ 100ng/ml	2 (5.6%)	1 (1.7%)	0.56 (0.24-1.30)	0.304 NS
	< 100ng/ml	34 (94.4%)	57 (98.3%)		
<b>Sonography</b>	Suspicious	4 (11.1%)	9 (15.5%)	1.28 (0.55-3.03)	0.547 NS
	Normal	32 (88.9%)	49 (84.5%)		

DxWBS: Diagnostic whole body scan; TgAb: Anti-Tg Antibody; CI: Confidence interval; NS: Not significant; RR: Risk ratio

Serum Tg, TgAb, DxWBS and neck ultrasonography were reevaluated six-months following second therapeutic-dose in the retreatment group and at the same interval in the untreated observation group, in TSH-stimulated state.

No significant difference was noted between groups regarding laboratory or imaging findings (Table 2). As noted in this table, 20 cases (34.5%) showing faint uptake on DxWBS after the first RAI ablative therapy in observation group, finally revealed negative DxWBS, with no further treatment, over an additional six-month follow-up period. By the end of the second 6-month period of follow-up, 15 cases in retreatment group (41.7%) and 16 individuals in observation group (27.6%) were finally met the full criteria of remission including negative DxWBS concomitant with normal sonographic and laboratory findings ( $p=0.158$ ). Also, only 6 cases (16.7%) in retreatment group and 12 cases (20.7%) in observation group revealed an additional finding, other than local faint RAI uptake, including detectable serum Tg, rising TgAb or suspicious ultrasound finding over an extra- follow up period, favoring no significant difference of the outcome, as well as relative risk of new finding incidence between treated and untreated patients (RR=1.18; CI95%: 0.58-2.41;  $p=0.630$ ).

## DISCUSSION

Differentiated thyroid cancer is the most common endocrine cancer with increasing incidence. Treatment consists of total thyroidectomy followed

by adjuvant radioiodine ablative therapy of thyroid remnants. Successful remnant ablation is usually defined as an absence of visible RAI uptake on a subsequent diagnostic RAI scan accompanied by an undetectable stimulated serum Tg [1]. Thyroglobulin serves as the sensitive and specific tumor marker for detection of persistent or recurrent disease, as it is produced exclusively by thyroid cells. Given the cellular specificity of Tg, its detection provides proof of the thyroid origin of the tissue [1, 17-19]. So the TSH-stimulated Tg is considered a reliable marker to evaluate the presence or absence of residual disease [2, 17, 18]. However, in clinical practice, in patients with DTC, there are occasional cases with undetectable Tg level, but residual thyroid tissue after ablative therapy. Regarding the highly sensitive and specific nature of Tg in follow-up, these patients are therefore a challenge to manage because of uncertainty concerning their disease status. There is some evidence that observation without repeating radioiodine treatment in these patients shows no remarkable difference in clinical outcomes [15, 16].

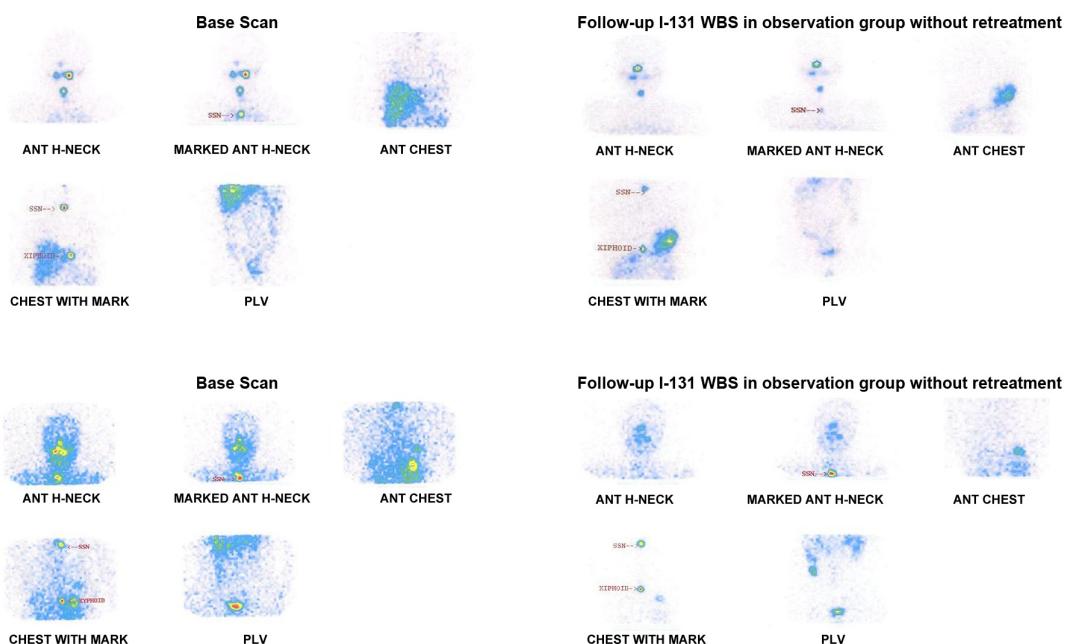
Evaluation of ablative therapy with Tg and WBS is usually performed at 6 month. However, as tumoricidal effect of I-131 in differentiated thyroid tumors could be achieved over extended months, we evaluated the efficacy of RAI ablative therapy over longer time period (12 months), in patients with only remnant uptake in the DxWBS and  $Tg < 1$  ng/ml. Even in these patients with remnant thyroid tissue, Tg is proved to be a valuable tumor marker [11]. Two groups of patients, retreatment and untreated

observation groups were evaluated. DxWBS, Tg, TgAb and sonographic studies six months afterwards, were used for this evaluation.

Our results showed that in 52.8% of the patients who received the second therapeutic dose, the scan became negative, while this rate in the patients who were only followed-up without retreatment was 34.5%. Although rate of negative scan result was apparently higher in patients who were retreated with RAI, the difference was not statistically significant. It should be noted that more than one-third of patients without further RAI dose can achieve complete treatment response (Figure 1). This is especially important in younger patients in whom long survival is expected and delivering lower possible radioiodine dose is crucial. The study by Lim et al also showed no remarkable differences in clinical outcomes between observation and treatment groups of DxWBS positive Tg negative patients [15]. Another study by Kim et al showed that a second ablation was not necessary in patients with very low Tg concentration and radioiodine uptake in DxWBS when neck US showed no evidence of disease [16]. Evidence of continued clinical response after radioiodine therapy is also demonstrated by a decline in Tg levels after cessation of RAI therapy in children with pulmonary metastases [20].

In our study off-T4 assessment of Tg (stimulated Tg) was performed. Tg measurements obtained during

thyroid hormone suppression of TSH might fail to identify patients with relatively small amounts of residual tumor [3, 21]. Tg level increases more notably after discontinuation of thyroid hormone [22], as is the case in our study. Our Tg assays were performed by IRMA method which offers practical advantage of a shorter incubation time, an extended dynamic range for the assay and a more stable labeled antibody reagent that is less prone to labeling damage than RIA [23]. The patients enrolled in our study had undetectable Tg levels after first ablation therapy. However, elevation in Tg level was seen in only one from 36 patients after the second treatment (2.8%) and two from 58 patients (3.4%) in observation group without treatment, representing no significant difference ( $p=0.857$ ). It is mentioned in the literature that only about 2% of patients with undetectable stimulated Tg will have recurrences over the next 3-5 years [14], supporting our finding that undetectable stimulated Tg is a reliable indicator of disease control. Other studies also proposed that low Tg level might warrant a less rigorous management [6-8]. It is shown that in low risk patients who do not undergo postoperative RAI remnant ablation, Tg values drop spontaneously, making it a valuable tool for follow-up even in this category of patients [3, 11, 24].



**Fig 1.** Two cases of I-131 WBS of the observation group (thyroid remnant without radioiodine retreatment) with and without remnant disappearance after observation: The baseline scan on the left side shows thyroid remnant tissue which is still present on the follow-up scan on the right side (above). The baseline scan on the left side shows thyroid remnant tissue, which has disappeared on the follow-up scan on the right side (below).

Even though most patients can be followed by Tg assessments, some thyroid cancer patients ( $\leq 25\%$ ) have antithyroglobulin antibodies in serum, at the time of diagnosis or after treatment. These antibodies interfere technically in the immunological methods for measuring Tg [25].

Any measurement of the serum thyroglobulin must be accompanied by an assay for TgAb, which usually interferes with and might invalidate the serum thyroglobulin assay [17]. IRMA method is especially prone to this interference commonly causing falsely low serum Tg measurements, while interference with RIA has the potential to cause either under- or overestimation of Tg, depending on the characteristics of the patient-specific TgAb and the RIA reagents [1, 26, 27].

For this reason we included only patients with low TgAb levels in our study to prevent the effect of such interference.

As it mentioned in the literature [28] the possibility of falsely undetectable Tg in patients with residual thyroid tissue should be taken into consideration. To avoid such pitfall, in addition to excluding patients with elevated TgAb from our study, Tg and TgAb levels were concomitantly rechecked in follow-up assessment.

The other reasons for false-negative Tg, in addition to TgAb interference, are defective or absent production and secretion of immunoreactive Tg by tumor cells and limited sensitivity of Tg methods to detect small amounts of thyroid tissue [12, 21, 29]. Tg levels should be interpreted in light of the pretest probability of clinically significant residual tumor [1, 12].

It should be noted that elevated TgAb level, apart from its importance in devaluating the Tg assays, is considered as surrogate marker of DTC recurrence or persistence, and has an essential role in disease follow-up as a tumor marker [30-32]. The patients who received repeated treatment in our study showed TgAb tumor marker elevation in only two patients (5.6%) 6 months after second therapeutic dose. This rate was 1.7% in observation group and the difference was statistically insignificant ( $p=0.304$ ).

Comparison of sonographic results also showed no significant difference between RAI retreatment and untreated groups ( $p=0.55$ ).

The first ablative administered dose in our study was empiric fixed dose (100, 125, 150 mCi/3700, 4625, 5550 MBq). The results showed that the dose was not significantly different between retreatment and follow-up groups, hence not affecting the treatment results. A study assessed the ablation outcome after a second ablation dose and compared the low and high doses concluded that there was no significant

difference in ablation rate between low and high doses [33]. Although some studies suggest that higher ablation doses are associated with more successful treatment rate [34-36], others show no beneficial effect from higher doses of radioiodine [37-41].

Rees study also suggested in low risk DTC patients one dose of radioiodine ablation is recommended to avoid over-treatment. Only those with unfavorable localized disease might benefit from an elective second dose [42]. Considering the short as well as long-term side effects and complications associated with exposure to therapeutic I-131, the minimum appropriate activity should be administered only when benefits are expected [43-49].

Our study had several limitations, the most important one being lack of proper patient randomization. Another shortcoming being the limited time of follow-up (6 months after second ablative dose), which is too short to fully evaluate possible tumor recurrence. Phan et al showed some patients with initially negative Tg/ TgAb had shown detectable Tg/ TgAb during follow-up indicative of persistent/recurrent disease [50], emphasizing the value of long-term follow-ups. This is because the risk of recurrence and disease specific mortality can change over time as a function of the clinical course of the disease and the response to therapy [51]. Lack of quantitative assessment of RAI uptake in the thyroid bed was other weakness of our study which may have had deteriorating effect on the accuracy of whole body scan interpretations.

## CONCLUSION

Regarding sonographic findings and serum Tg/TgAb levels during follow-up, no significant advantage was evident for RAI-retreatment in patients with undetectable Tg and positive remnant in DxWBS on the first post-ablation evaluation. Also, more than one-third of Tg negative faintly positive DxWBS demonstrated negative follow-up scan without additional I-131 retreatment. Therefore, avoiding additional radioiodine retreatment might be advisable in certain settings of undetectable Tg level and only small thyroid remnants. This result could be attributed to continued ablative effect of I-131, exerting its maximal effect in a longer period of time. Avoiding extra dose of I-131 is of exceptional value in preventing unnecessary radiation burden to the patient and society, needless to mention the economic significance of this treatment approach.

## Acknowledgments

This research has been part of a nuclear medicine specialty thesis and supported by Tehran University

of Medical Sciences, Tehran, Iran (grant number: 6666). The authors would like to thank Ms. Mansooreh Darvishha for her technical assistance.

## REFERENCES

1. American Thyroid Association (ATA) Guidelines Taskforce on Thyroid Nodules and Differentiated Thyroid Cancer, Cooper DS, Doherty GM, Haugen BR, Kloos RT, Lee SL, Mandel SJ, Mazzaferri EL, McIver B, Pacini F, Schlumberger M, Sherman SI, Steward DL, Tuttle RM. Revised American Thyroid Association management guidelines for patients with thyroid nodules and differentiated thyroid cancer. *Thyroid*. 2009 Nov;19(11):1167-214.
2. Francis GL, Waguespack SG, Bauer AJ, Angelos P, Benvenga S, Cerutti JM, Dinauer CA, Hamilton J, Hay ID, Luster M, Parisi MT, Rachmiel M, Thompson GB, Yamashita S; American Thyroid Association Guidelines Task Force. Management guidelines for children with thyroid nodules and differentiated thyroid cancer. *Thyroid*. 2015 Jul;25(7):716-59.
3. Mazzaferri EL, Robbins RJ, Spencer CA, Braverman LE, Pacini F, Wartofsky L, Haugen BR, Sherman SI, Cooper DS, Braunstein GD, Lee S, Davies TF, Arafah BM, Ladenson PW, Pinchera A. A consensus report of the role of serum thyroglobulin as a monitoring method for low-risk patients with papillary thyroid carcinoma. *J Clin Endocrinol Metab*. 2003 Apr;88(4):1433-41.
4. Kloos RT. Thyroid cancer recurrence in patients clinically free of disease with undetectable or very low serum thyroglobulin values. *J Clin Endocrinol Metab*. 2010 Dec;95(12):5241-8.
5. Robbins RJ, Srivastava S, Shaha A, Ghossein R, Larson SM, Fleisher M, Tuttle RM. Factors influencing the basal and recombinant human thyrotropin-stimulated serum thyroglobulin in patients with metastatic thyroid carcinoma. *J Clin Endocrinol Metab*. 2004 Dec;89(12):6010-6.
6. Giovannella L, Treglia G, Sadeghi R, Trimboli P, Ceriani L, Verburg FA. Unstimulated highly sensitive thyroglobulin in follow-up of differentiated thyroid cancer patients: a meta-analysis. *J Clin Endocrinol Metab*. 2014 Feb;99(2):440-7.
7. Chindris AM, Diehl NN, Crook JE, Fatourehchi V, Smallridge RC. Undetectable sensitive serum thyroglobulin (<0.1 ng/ml) in 163 patients with follicular cell-derived thyroid cancer: results of rTSH stimulation and neck ultrasonography and long-term biochemical and clinical follow-up. *J Clin Endocrinol Metab*. 2012 Aug;97(8):2714-23.
8. Lee JI, Chung YJ, Cho BY, Chong S, Seok JW, Park SJ. Postoperative-stimulated serum thyroglobulin measured at the time of <sup>131</sup>I ablation is useful for the prediction of disease status in patients with differentiated thyroid carcinoma. *Surgery*. 2013 Jun;153(6):828-35.
9. Schlumberger M, Berg G, Cohen O, Duntas L, Jamar F, Jarzab B, Limbert E, Lind P, Pacini F, Reiners C, Sánchez Franco F, Toft A, Wiersinga WM. Follow-up of low-risk patients with differentiated thyroid carcinoma: a European perspective. *Eur J Endocrinol*. 2004 Feb;150(2):105-12.
10. Pacini F, Capezzone M, Elisei R, Ceccarelli C, Taddei D, Pinchera A. Diagnostic <sup>131</sup>I-iodine whole-body scan may be avoided in thyroid cancer patients who have undetectable stimulated serum Tg levels after initial treatment. *J Clin Endocrinol Metab*. 2002 Apr;87(4):1499-501.
11. Durante C, Montesano T, Attard M, Torlontano M, Monzani F, Costante G, Meringolo D, Ferdeghini M, Tumino S, Lamartina L, Paciaroni A, Massa M, Giacomelli L, Ronga G, Filetti S; PTC Study Group. Long-term surveillance of papillary thyroid cancer patients who do not undergo postoperative radioiodine remnant ablation: is there a role for serum thyroglobulin measurement? *J Clin Endocrinol Metab*. 2012 Aug;97(8):2748-53.
12. Ma C, Kuang A, Xie J, Ma T. Possible explanations for patients with discordant findings of serum thyroglobulin and <sup>131</sup>I whole-body scanning. *J Nucl Med*. 2005 Sep;46(9):1473-80.
13. Park EK, Chung JK, Lim IH, Park DJ, Lee DS, Lee MC, Cho BY. Recurrent/metastatic thyroid carcinomas false negative for serum thyroglobulin but positive by posttherapy I-131 whole body scans. *Eur J Nucl Med Mol Imaging*. 2009 Feb;36(2):172-9.
14. Tuttle RM, Haddad RI, Ball DW, Byrd D, Dickson P, Duh QY, Ehya H, Haymart M, Hoh C, Hunt JP, Iagaru A, Kandeel F, Kopp P, Lamonica DM, Lydiatt WM, McCaffrey J, Moley JF, Parks L, Raeburn CD, Ridge JA, Ringel MD, Scheri RP, Shah JP, Sherman SI, Sturgeon C, Waguespack SG, Wang TN, Wirth LJ, Hoffmann KG, Hughes M. Thyroid carcinoma, version 2.2014. *J Natl Compr Canc Netw*. 2014 Dec;12(12):1671-80.
15. Lim DJ, O JH, Kim MH, Kim JH, Kwon HS, Kim SH, Kang MI, Cha BY, Lee KW, Son HY. Clinical significance of observation without repeated radioiodine therapy in differentiated thyroid carcinoma patients with positive surveillance whole-body scans and negative thyroglobulin. *Korean J Intern Med*. 2010 Dec;25(4):408-14.
16. Kim EY, Kim WG, Kim WB, Kim TY, Ryu JS, Gong G, Yoon JH, Hong SJ, Lee JH, Baek JH, Shong YK. Clinical outcomes of persistent radioiodine uptake in the neck shown by diagnostic whole body scan in patients with differentiated thyroid carcinoma after initial surgery and remnant ablation. *Clin Endocrinol (Oxf)*. 2010 Aug;73(2):257-63.
17. Silberstein EB. The treatment of thyroid malignant neoplasms. In: Henkin RE, Bova D, Dillehay GL, Halama JR, Karesh SM, Wagner RH, Zimmer AM, eds. *Nuclear medicine*. Philadelphia: Mosby Elsevier; 2006. p. 1576-88.
18. Tuttle RM, Becker DV, Hurley JR. Radioiodine treatment of thyroid diseases. In: Sandler MP, Coleman RE, Patton JA, Wackers FJ, Gottschalk A, eds. *Diagnostic nuclear medicine*. Philadelphia: Lippincott Williams & Wilkins; 2003. p. 653-70.
19. Whitley RJ, Ain KB. Thyroglobulin: a specific serum marker for the management of thyroid carcinoma. *Clin Lab Med*. 2004 Mar;24(1):29-47.
20. Biko J, Reiners C, Kreissl MC, Verburg FA, Demidchik Y, Drozd V. Favourable course of disease after incomplete remission on (<sup>131</sup>I) therapy in children with pulmonary metastases of papillary thyroid carcinoma: 10 years follow-up. *Eur J Nucl Med Mol Imaging*. 2011 Apr;38(4):651-5.
21. Bachelot A, Leboulleux S, Baudin E, Hartl DM, Caillou B, Travagli JP, Schlumberger M. Neck recurrence from thyroid carcinoma: serum thyroglobulin and high-dose total body scan are not reliable criteria for cure after

- radioiodine treatment. *Clin Endocrinol (Oxf)*. 2005 Mar;62(3):376-9.
22. Ciappuccini R, Hardouin J, Heutte N, Vaur D, Quak E, Rame JP, Blanchard D, de Raucourt D, Bardet S. Stimulated thyroglobulin level at ablation in differentiated thyroid cancer: the impact of treatment preparation modalities and tumor burden. *Eur J Endocrinol*. 2014 Aug;171(2):247-52.
  23. Dai J, Dent W, Atkinson JW, Cox JG, Dembinski TC. Comparison of three immunoassay kits for serum thyroglobulin in patients with thyroid cancer. *Clin Biochem*. 1996 Oct;29(5):461-5.
  24. Nascimento C, Borget I, Troalen F, Al Ghuzlan A, Deandreis D, Hartl D, Lumbroso J, Chougnet CN, Baudin E, Schlumberger M, Leboulloux S. Ultrasensitive serum thyroglobulin measurement is useful for the follow-up of patients treated with total thyroidectomy without radioactive iodine ablation. *Eur J Endocrinol*. 2013 Oct 4;169(5):689-93.
  25. Feldt-Rasmussen U, Verburg FA, Luster M, Cupini C, Chiovato L, Duntas L, Elisei R, Rimmele H, Seregini E, Smit JW, Theimer C, Giovanella L. Thyroglobulin autoantibodies as surrogate biomarkers in the management of patients with differentiated thyroid carcinoma. *Curr Med Chem*. 2014;21(32):3687-92.
  26. Verburg FA, Luster M, Cupini C, Chiovato L, Duntas L, Elisei R, Feldt-Rasmussen U, Rimmele H, Seregini E, Smit JW, Theimer C, Giovanella L. Implications of thyroglobulin antibody positivity in patients with differentiated thyroid cancer: a clinical position statement. *Thyroid*. 2013 Oct;23(10):1211-25.
  27. Spencer CA. Clinical review: Clinical utility of thyroglobulin antibody (TgAb) measurements for patients with differentiated thyroid cancers (DTC). *J Clin Endocrinol Metab*. 2011 Dec;96(12):3615-27.
  28. Giovanella L, Suriano S, Ceriani L, Verburg FA. Undetectable thyroglobulin in patients with differentiated thyroid carcinoma and residual radioiodine uptake on a postablation whole-body scan. *Clin Nucl Med*. 2011 Feb;36(2):109-12.
  29. Torr ns JI, Burch HB. Serum thyroglobulin measurement. Utility in clinical practice. *Endocrinol Metab Clin North Am*. 2001 Jun;30(2):429-67.
  30. Lupoli GA, Okosieme OE, Evans C, Clark PM, Pickett AJ, Premawardhana LD, Lupoli G, Lazarus JH. Prognostic significance of thyroglobulin antibody epitopes in differentiated thyroid cancer. *J Clin Endocrinol Metab*. 2015 Jan;100(1):100-8.
  31. Gianoukakis AG. Thyroglobulin antibody status and differentiated thyroid cancer: what does it mean for prognosis and surveillance? *Curr Opin Oncol*. 2015 Jan;27(1):26-32.
  32. Chung JK, Park YJ, Kim TY, So Y, Kim SK, Park DJ, Lee DS, Lee MC, Cho BY. Clinical significance of elevated level of serum antithyroglobulin antibody in patients with differentiated thyroid cancer after thyroid ablation. *Clin Endocrinol (Oxf)*. 2002 Aug;57(2):215-21.
  33. M El-Refaei S1, W Yassin S, Salman K, Al Munshy T, Al-Ezzi M, M Al-Sayed Y, Abd Elkareem Husseni M. Comparison between low and high radioactive iodine (131I) reablation dose in patients with papillary thyroid cancer. *Nucl Med Commun*. 2015 Feb;36(2):114-9.
  34. Giovanella L, Piccardo A, Paone G, Foppiani L, Treglia G, Ceriani L. Thyroid lobe ablation with iodine- <sup>131</sup>I in patients with differentiated thyroid carcinoma: a randomized comparison between 1.1 and 3.7 GBq activities. *Nucl Med Commun*. 2013 Aug;34(8):767-70.
  35. Fallahi B, Beiki D, Takavar A, Fard-Esfahani A, Gilani KA, Saghari M, Eftekhari M. Low versus high radioiodine dose in postoperative ablation of residual thyroid tissue in patients with differentiated thyroid carcinoma: a large randomized clinical trial. *Nucl Med Commun*. 2012 Mar;33(3):275-82.
  36. Kim EY, Kim TY, Kim WG, Yim JH, Han JM, Ryu JS, Hong SJ, Yoon JH, Gong G, Kim WB, Shong YK. Effects of different doses of radioactive iodine for remnant ablation on successful ablation and on long-term recurrences in patients with differentiated thyroid carcinoma. *Nucl Med Commun*. 2011 Oct;32(10):954-9.
  37. Du P, Jiao X, Zhou Y, Li Y, Kang S, Zhang D, Zhang J, Lv L, Patel R. Low versus high radioiodine activity to ablate the thyroid after thyroidectomy for cancer: a meta-analysis of randomized controlled trials. *Endocrine*. 2015 Feb;48(1):96-105.
  38. Bal C, Chandra P, Kumar A, Dwivedi S. A randomized equivalence trial to determine the optimum dose of iodine-131 for remnant ablation in differentiated thyroid cancer. *Nucl Med Commun*. 2012 Oct;33(10):1039-47.
  39. Han JM, Kim WG, Kim TY, Jeon MJ, Ryu JS, Song DE, Hong SJ, Shong YK, Kim WB. Effects of low-dose and high-dose postoperative radioiodine therapy on the clinical outcome in patients with small differentiated thyroid cancer having microscopic extrathyroidal extension. *Thyroid*. 2014 May;24(5):820-5.
  40. Cheng W, Ma C, Fu H, Li J, Chen S, Wu S, Wang H. Low- or high-dose radioiodine remnant ablation for differentiated thyroid carcinoma: a meta-analysis. *J Clin Endocrinol Metab*. 2013 Apr;98(4):1353-60.
  41. Valachis A, Nearchou A. High versus low radioiodine activity in patients with differentiated thyroid cancer: a meta-analysis. *Acta Oncol*. 2013 Aug;52(6):1055-61.
  42. Rees GJ. Radioiodine ablation for differentiated thyroid cancer—none, one dose or two? *Clin Oncol (R Coll Radiol)*. 2010 Mar;22(2):131-5.
  43. Fard-Esfahani A, Emami-Ardekani A, Fallahi B, Fard-Esfahani P, Beiki D, Hassanzadeh-Rad A, Eftekhari M. Adverse effects of radioactive iodine-131 treatment for differentiated thyroid carcinoma. *Nucl Med Commun*. 2014 Aug;35(8):808-17.
  44. Esfahani AF, Fallahi B, Olamaie R, Eftekhari M, Beiki D, Saghari M. Semi-quantitative assessment of salivary gland function in patients with differentiated thyroid carcinoma after radioiodine-131 treatment. *Hell J Nucl Med*. 2004 Sep-Dec;7(3):206-9.
  45. Esfahani AF, Eftekhari M, Zenooz N, Saghari M. Gonadal function in patients with differentiated thyroid cancer treated with (131)I. *Hell J Nucl Med*. 2004 Jan-Apr;7(1):52-5.
  46. Fard-Esfahani A, Hadifar M, Fallahi B, Beiki D, Eftekhari M, Saghari M, Takavar A. Radioiodine treatment complications to the mother and child in patients with differentiated thyroid carcinoma. *Hell J Nucl Med*. 2009 Jan-Apr;12(1):37-40.
  47. Fard-Esfahani A, Mirshekarpour H, Fallahi B, Eftekhari M, Saghari M, Beiki D, Ansari-Gilani K, Takavar A. The effect of high-dose radioiodine treatment on lacrimal gland function in patients with differentiated thyroid carcinoma. *Clin Nucl Med*. 2007 Sep;32(9):696-9.



48. Fard-Esfahani A, Farzanefar S, Fallahi B, Beiki D, Saghari M, Emami-Ardekani A, Majidi M, Eftekhari M. Nasolacrimal duct obstruction as a complication of iodine-131 therapy in patients with thyroid cancer. *Nucl Med Commun.* 2012 Oct;33(10):1077-80.
49. Fallahi B, Adabi K, Majidi M, Fard-Esfahani A, Heshmat R, Larijani B, Haghpanah V. Incidence of second primary malignancies during a long-term surveillance of patients with differentiated thyroid carcinoma in relation to radioiodine treatment. *Clin Nucl Med.* 2011 Apr;36(4):277-82.
50. Phan HT, Jager PL, van der Wal JE, Sluiter WJ, Plukker JT, Dierckx RA, Wolffenbuttel BH, Links TP. The follow-up of patients with differentiated thyroid cancer and undetectable thyroglobulin (Tg) and Tg antibodies during ablation. *Eur J Endocrinol.* 2008 Jan;158(1):77-83.
51. Haugen BR, Alexander EK, Bible KC, Doherty GM, Mandel SJ, Nikiforov YE, Pacini F, Randolph GW, Sawka AM, Schlumberger M, Schuff KG, Sherman SI, Sosa JA, Steward DL, Tuttle RM, Wartofsky L. 2015 American Thyroid Association Management Guidelines for Adult Patients with Thyroid Nodules and Differentiated Thyroid Cancer: The American Thyroid Association Guidelines Task Force on Thyroid Nodules and Differentiated Thyroid Cancer. *Thyroid.* 2016 Jan;26(1):1-133.