

Radiation induced myocardial perfusion abnormalities in patients with left breast cancer: A prospective study with short and long term follow up

Mohammad Eftekhari¹, Forough Kalantari¹, Alireza Emami-Ardekani¹,
Hamidreza Amini¹, Armaghan Fard-Esfahani¹, Babak Fallahi¹, Davood Beiki¹,
Saeed Farzanefer², Elham Kalantari³, Arman Hasanzadeh-Rad¹, Mehrshad Abbasi²

¹Research Center for Nuclear Medicine, Shariati Hospital, Tehran University of Medical Sciences, Tehran, Iran

²Department of Nuclear Medicine, Vali-Asr Hospital, Tehran University of Medical Sciences, Tehran, Iran

³Department of Internal medicine, Alzahra Hospital, Isfahan University of Medical Sciences, Isfahan, Iran

(Received 9 June 2016, Revised 9 September 2016, Accepted 10 September 2016)

ABSTRACT

Introduction: The external beam radiation therapy for patients with left breast cancer at the mastectomy site may cause myocardial perfusion abnormalities. We intended to study the change of these abnormalities at short and long term post radiotherapy follow up.

Methods: Twenty patients with left and 20 patients with right breast cancer comprised the exposed and control groups, respectively. The patients had low risk for coronary disease. They underwent myocardial perfusion scans (MPS) 3 years after the external beam radiation therapy at the bed of modified radical mastectomy. These subjects were recruited from two bigger cohorts with previously reported data of scans at 6 months. The scans were acquired after injections of about 20 mCi MIBI at peak pharmacologic stress and at rest. The change of the perfusion abnormalities by both visual assessment and quantifications (Autoquant) at the baseline and 3 years follow up time are compared between exposed and control patients.

Results: The exposed patients had more visual perfusion abnormality scores compared to control subjects (1.1 ± 1.3 vs. 0.3 ± 1.0 ; $p=0.03$). The indices of perfusion abnormality normalized in control subjects from baseline to follow up scans ($p=0.05$ for summed difference score and $p=0.04$ for summed stress score). The difference of the perfusion abnormalities between the exposed and unexposed subjects remained unchanged along the 3 years of follow up.

Conclusion: The radiation induced myocardial perfusion abnormalities in patients with left breast cancer could cause permanent coronary disease over time.

Key words: Breast cancer; Radiotherapy; Myocardial perfusion scan; Coronary artery disease

Iran J Nucl Med 2017;25(Suppl 1):21-25

Published: February, 2017

<http://irjnm.tums.ac.ir>

Corresponding author: Dr. Alireza Emami-Ardekani, Research Center for Nuclear Medicine, Shariati Hospital, North Kargar Ave. 1411713135, Tehran, Iran. E-mail: emami_a@sina.tums.ac.ir

INTRODUCTION

The breast cancer is the most commonly diagnosed cancer in women [1, 2]. While the incidence rates were stable, the cancer death rates decreased by 35% during the last couple of decades [1]. The decline in the death rate is due to early diagnosis [3] and use of appropriate radiation and chemotherapy options [4]. The radiation causes free radicals [5] and in contrast to its favorable outcomes it may cause vascular damage in the vasculature of the non-target organs [6-8]. When the surgical bed of the left breast following mastectomy is treated with external beam radiation, utmost caution is required to limit the radiation into the viscera [9]. Despite all effects, cardiac radiation is not negligible and the possibility of coronary damage is considerable [10].

We previously showed that the patients with left breast cancer demonstrate increased incidence of myocardial perfusion abnormalities 6 months after radiation [11]. To confirm whether these findings are temporary or permanent, in the current study we followed two subgroups from the cohorts of our previous study for a longer period of time.

METHODS

We recruited 40 cases from our previous study [11], 20 patients with left and 20 with right breast cancer. In brief all the participants underwent modified radical mastectomy and adjuvant radiotherapy and chemotherapy. The patients had low risk for cardiovascular events based on the Framingham score and none of them had history of diabetes mellitus, hypertension, hyperlipidemia, smoking or CCU admission. At baseline (i.e. 6 month post radiotherapy) myocardial perfusion scans were obtained from all these patients and the results are already reported elsewhere [11]. The patients were recruited for a follow up scan 2.5 years after the baseline scan. MPI was done based on the two day pharmacologic stress and next day rest protocol (Figure 1). For pharmacologic stress 0.56 mg/kg dipyridamole was injected slowly over 4 minutes and about 20 mCi ^{99m}Tc MIBI was injected 4 minutes afterward. The next day same amount of ^{99m}Tc MIBI was administered at rest condition. The imaging was done in cardiac cycle gated SPECT mode by a single head ADAC gamma camera (Argus, ADAC, Milpitas, CA) with 64×64 matrix sizes, 32 stops and about 25 seconds projection times. The visual interpreter had access to all quantifications of Cedars Cardiac Suite (QPS/QGS) and the ischemia was reported based on a 5 scale of 0 to 4 based on the severity of the perfusion defect and reversibility. The scans with any perfusion abnormality (i.e. any score above or equal to 0) was defined as abnormal scans.

The analyses are done in IBM SPSS (v 19) and the p values less than 0.05 were considered significant.

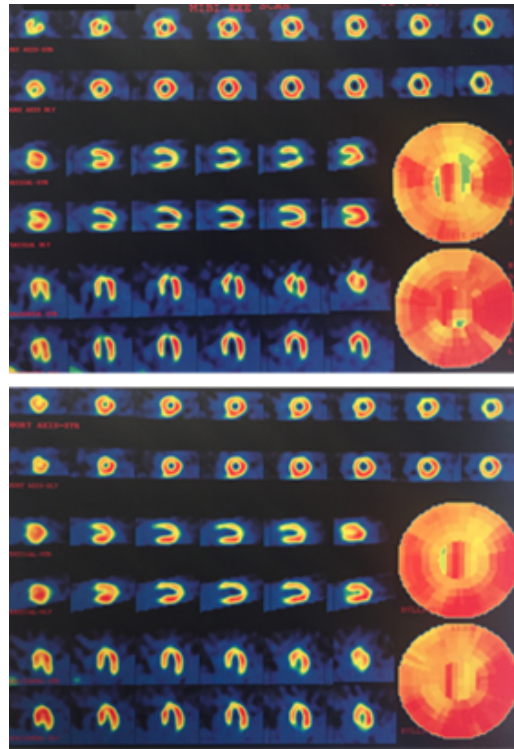


Fig 1. Comparing early (above) and late (below) myocardial perfusion study after left sided mastectomy shows persistence of ischemia in the apex and apical anterior.

RESULTS

Patients aged 45.3 ± 7.0 and 48.8 ± 7.0 at baseline and follow up, respectively. Age at follow up scan were the same in case and control subjects and was respectively 47.9 ± 6.9 and 49.6 ± 7.2 ($p=0.44$). Left ventricular ejection fractions (LVEF) at baseline and follow up are 58.4 ± 3.4 and 58.9 ± 3.0 , respectively. The indices of perfusion defects at baseline and follow up are presented in Table 1.

Among all indices visual scores are different between the exposed and unexposed subjects only at follow up scan ($p=0.03$). The summed stress scores and summed rest scores (indices of perfusion abnormality at stress and ischemia) improved significantly in unexposed subjects from baseline to follow up scan ($p=0.04$ and $p=0.05$, respectively). The general linear model for repeated measurements indicated that there is remarkable difference between the exposed and control subjects at both baseline and follow up scans ($p<0.05$; partial $\eta^2=0.1$) with no significant difference for the trend at these two time intervals ($p=0.6$; Figure 2).

Table 1: The perfusion indices of the patients at baseline and follow up.

	Control	Exposed	Total	<i>P</i> value ^a	<i>P</i> value ^b	<i>P</i> value ^c	
Baseline	Visual Score	0.7(1.5)	1.3(1.7)	1.0(1.6)	0.246	0.260	0.380
	Summed Stress Score	0.9(1.3)	2.2(3.0)	1.6(2.4)	0.091	0.040	0.200
	Summed Rest Score	0.3(0.9)	0.4(1.0)	0.3(0.9)	0.622	0.230	0.690
	Summed Difference Score	0.7(0.9)	1.8(2.8)	1.2(2.1)	0.102	0.050	0.100
Follow up	Visual Score	0.3(1.0)	1.1(1.3)	0.7(1.2)	0.030	-	-
	Summed Stress Score	0.2(0.4)	1.1(2.1)	0.7(1.5)	0.071	-	-
	Summed Rest Score	0.0(0.0)	0.5(1.1)	0.3(0.8)	0.056	-	-
	Summed Difference Score	0.2(0.4)	0.6(1.2)	0.4(0.9)	0.168	-	-

Numbers are mean and standard deviations in parentheses.

^a *P* values less than 0.05 indicate significant differences between exposed and unexposed patients.

^b *P* values less than 0.05 indicate significant change from baseline to follow up scan in control subjects.

^c *P* values less than 0.05 indicate significant change from baseline to follow up scan in exposed subjects.

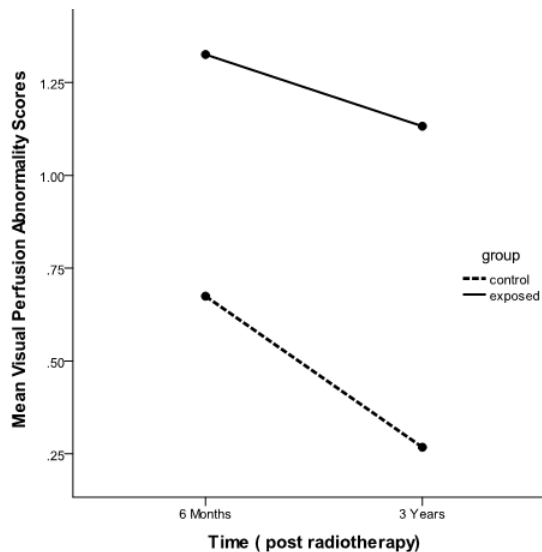


Fig 2. The change of perfusion defect in subjects with and without heart radiation along the time [6 months and 3 years after radiation]. The perfusion abnormalities are more in exposed subjects. General linear model indicates no interaction between the time and the group [exposed and control; $p=0.6$] group membership; model is designed after adjustment for age.

DISCUSSION

The radiotherapy causes damage to all three layers of the coronary arteries [12]. It has been shown that the damage increases concordant with higher absorbed radiation doses in the myocardium [13-15] On the other hand it is considered that the cardiac risk in

these patients is a function of baseline risk of disease [16] and contradictory reports indicate no additional mortality and risk in these patients [17]. We previously documented that the patients with left breast cancer present myocardial perfusion abnormalities shortly after radiotherapy of the mastectomy site [11]. It was postulated that these changes are temporary and the coronary flow may stabilize after the acute phase of radiation. In the current study we documented that this perfusion abnormalities are permanent at the follow up scan of 3 years after the radiotherapy.

In a study, focal or annular myocardial FDG uptake, inconsistent with vascular territory, was seen after radiotherapy of thorax; close follow-up for early diagnosis of possible cardiac events was recommended [18].

In irradiated coronary vessels asymptomatic disease is also prevalent. Marks et al showed increased incidence of myocardial perfusion abnormality (27-42%), 6 to 24 months following radiation therapy in asymptomatic patients with strong correlation of the left ventricle being in the field of radiotherapy [19]. These findings correlate with our study.

In contrast, a review Goethals et al. concluded that the risk of any cardiac disease post radiotherapy is low [20].

Certain chemotherapy agents are correlated with damage of the coronary artery vasculature and the heart [21-23]. The perfusion abnormalities denoted in the control subject who received treatment for right breast cancer may be interpreted as a side effect of this part of therapy [24]. We found improved

perfusion abnormalities in patients with treated right breast cancer after 3 years compared to the baseline scan. This may point out that the abnormalities in these patients have been temporary and reserved afterward. The post chemotherapy changes and the stress of the patients at the time of diagnosis and surgery may contribute into this temporary finding. The permanent perfusion abnormalities in the patients after left breast radiotherapy may illustrate that the unique cause of such remaining perfusion defects are as a consequences of radiation to the myocardium.

Since the process of atherogenesis is considered to take longer than the time limit of this study is longer than the period of this study [25], we may consider the damage to the coronary vasculature after radiation via another different mechanism than atherosclerosis. Fibrosis and tissue necrosis could contribute to the damage and subsequent atherogenesis [26, 27]. A shortcoming of this study is inability to follow the patients for longer time for any possible coronary artery disease. Nevertheless further epidemiological studies in patients following radiation therapy may provide better information. While the radiation to the surgical bed is an inevitable part of the treatment of breast cancer, the radiation to the heart should be minimized. This might be done with optimal dose management in IMRT [28].

CONCLUSION

It was postulated that the noticed changes are temporary and the coronary flow may stabilize after the acute phase of radiation. In the current study we documented that the myocardial perfusion abnormalities are permanent at the follow ups up to 3 years after the radiotherapy. Also we found improved perfusion abnormalities in patients received right breast radiation treatment after 3 years compared to the baseline studies. Regarding the susceptibility of cardiac damage and perfusion abnormalities in patients treated with radiation in left hemithorax and the fact that this changes may result in clinically significant coronary artery disease, it is reasonable to pay special attention to radiation planning as far as the dose and limits of radiation field are concerned. Also it is better to consider periodical follow up even in clinically asymptomatic post radiation patients.

Acknowledgments

This research has been part of a nuclear medicine specialty thesis and supported by Tehran University of Medical Sciences, Tehran, Iran, grant no. 25354.

REFERENCES

1. Siegel RL, Miller KD, Jemal A. Cancer statistics, 2015. *CA Cancer J Clin.* 2015;65(1):5-29.
2. Bray F, Ren JS, Masuyer E, Ferlay J. Global estimates of cancer prevalence for 27 sites in the adult population in 2008. *Int J Cancer.* 2013 Mar 1;132(5):1133-45.
3. Pace LE, Keating NL. A systematic assessment of benefits and risks to guide breast cancer screening decisions. *JAMA.* 2014 Apr 2;311(13):1327-35.
4. Coates AS, Winer EP, Goldhirsch A, Gelber RD, Gnant M, Piccart-Gebhart M, Thürlimann B, Senn HJ; Panel Members. Tailoring therapies—improving the management of early breast cancer: St Gallen International Expert Consensus on the Primary Therapy of Early Breast Cancer 2015. *Ann Oncol.* 2015 Aug;26(8):1533-46.
5. Lomax ME, Folkes LK, O'Neill P. Biological consequences of radiation-induced DNA damage: relevance to radiotherapy. *Clin Oncol (R Coll Radiol).* 2013 Oct;25(10):578-85.
6. Park HJ, Griffin RJ, Hui S, Levitt SH, Song CW. Radiation-induced vascular damage in tumors: implications of vascular damage in ablative hypofractionated radiotherapy (SBRT and SRS). *Radiat Res.* 2012 Mar;177(3):311-27.
7. Sardaro A, Petruzzelli MF, D'Errico MP, Grimaldi L, Pili G, Portaluri M. Radiation-induced cardiac damage in early left breast cancer patients: risk factors, biological mechanisms, radiobiology, and dosimetric constraints. *Radiother Oncol.* 2012 May;103(2):133-42.
8. Lenihan DJ, Cardinale DM. Late cardiac effects of cancer treatment. *J Clin Oncol.* 2012 Oct 20;30(30):3657-64.
9. Shah C, Badiyan S, Berry S, Khan AJ, Goyal S, Schulte K, Nanavati A, Lynch M, Vicini FA. Cardiac dose sparing and avoidance techniques in breast cancer radiotherapy. *Radiother Oncol.* 2014 Jul;112(1):9-16.
10. Taylor CW, Wang Z, Macaulay E, Jaggi R, Duane F, Darby SC. Exposure of the Heart in Breast Cancer Radiation Therapy: A Systematic Review of Heart Doses Published During 2003 to 2013. *Int J Radiat Oncol Biol Phys.* 2015 Nov 15;93(4):845-53.
11. Eftekhari M, Anbiaei R, Zamani H, Fallahi B, Beiki D, Ameri A, Emami-Ardekani A, Fard-Esfahani A, Gholamrezanezhad A, Seid Ratki KR, Roknabadi AM. Radiation-induced myocardial perfusion abnormalities in breast cancer patients following external beam radiation therapy. *Asia Ocean J Nucl Med Biol.* 2015;3(1):3-9.
12. Yusuf SW, Howell RM, Gomez D, Pinnix CC, Ilescu CA, Banchs J. Radiation-related heart and vascular disease. *Future Oncol.* 2015;11(14):2067-76.
13. Darby SC, Ewertz M, McGale P, Bennet AM, Blom-Goldman U, Brønnum D, Correa C, Cutter D, Gagliardi G, Gigante B, Jensen MB, Nisbet A, Peto R, Rahimi K, Taylor C, Hall P. Risk of ischemic heart disease in women after radiotherapy for breast cancer. *N Engl J Med.* 2013 Mar 14;368(11):987-98.
14. Henson KE, McGale P, Taylor C, Darby SC. Radiation-related mortality from heart disease and lung cancer more than 20 years after radiotherapy for breast cancer. *Br J Cancer.* 2013 Jan 15;108(1):179-82.
15. Darby SC, Ewertz M, Hall P. Ischemic heart disease after breast cancer radiotherapy. *N Engl J Med.* 2013 Jun 27;368(26):2527.
16. Brenner DJ, Shuryak I, Jozsef G, Dewyngaert KJ, Formenti SC. Risk and risk reduction of major coronary events associated with contemporary breast radiotherapy. *JAMA Intern Med.* 2014 Jan;174(1):158-60.

17. Rutter CE, Chagpar AB, Evans SB. Breast cancer laterality does not influence survival in a large modern cohort: implications for radiation-related cardiac mortality. *Int J Radiat Oncol Biol Phys*. 2014 Oct 1;90(2):329-34.
18. Unal K, Unlu M, Akdemir O, Akmansu M. 18F-FDG PET/CT findings of radiotherapy-related myocardial changes in patients with thoracic malignancies. *Nucl Med Commun*. 2013 Sep;34(9):855-9.
19. Marks LB, Yu X, Prosnitz RG, Zhou SM, Hardenbergh PH, Blazing M, Hollis D, Lind P, Tisch A, Wong TZ, Borges-Neto S. The incidence and functional consequences of RT-associated cardiac perfusion defects. *Int J Radiat Oncol Biol Phys*. 2005 Sep 1;63(1):214-23.
20. Goethals I, De Winter O, De Bondt P, De Sutter J, Dierckx R, Van De Wiele C. The clinical value of nuclear medicine in the assessment of irradiation-induced and anthracycline-associated cardiac damage. *Ann Oncol*. 2002 Sep;13(9):1331-9.
21. Bowles EJ, Wellman R, Feigelson HS, Onitilo AA, Freedman AN, Delate T, Allen LA, Nekhlyudov L, Goddard KA, Davis RL, Habel LA, Yood MU, McCarty C, Magid DJ, Wagner EH; Pharmacovigilance Study Team. Risk of heart failure in breast cancer patients after anthracycline and trastuzumab treatment: a retrospective cohort study. *J Natl Cancer Inst*. 2012 Sep 5;104(17):1293-305.
22. Murtagh G, Lyons T, O'Connell E, Ballot J, Geraghty L, Fennelly D, Gullo G, Ledwidge M, Crown J, Gallagher J, Watson C, McDonald KM, Walshe JM. Late cardiac effects of chemotherapy in breast cancer survivors treated with adjuvant doxorubicin: 10-year follow-up. *Breast Cancer Res Treat*. 2016 Apr;156(3):501-6.
23. Sandoo A, Kitas GD, Carmichael AR. Breast cancer therapy and cardiovascular risk: focus on trastuzumab. *Vasc Health Risk Manag*. 2015 Apr 7;11:223-8.
24. Curigliano G, Cardinale D, Suter T, Plataniotis G, de Azambuja E, Sandri MT, Criscitiello C, Goldhirsch A, Cipolla C, Roila F; ESMO Guidelines Working Group. Cardiovascular toxicity induced by chemotherapy, targeted agents and radiotherapy: ESMO Clinical Practice Guidelines. *Ann Oncol*. 2012 Oct;23 Suppl 7:vii155-66.
25. Hancock SL, Tucker MA, Hoppe RT. Factors affecting late mortality from heart disease after treatment of Hodgkin's disease. *JAMA*. 1993 Oct 27;270(16):1949-55.
26. Madan R, Benson R, Sharma DN, Julka PK, Rath GK. Radiation induced heart disease: Pathogenesis, management and review literature. *J Egypt Natl Canc Inst*. 2015 Dec;27(4):187-93.
27. Gujral DM, Shah BN, Chahal NS, Senior R, Harrington KJ, Nutting CM. Clinical features of radiation-induced carotid atherosclerosis. *Clin Oncol (R Coll Radiol)*. 2014 Feb;26(2):94-102.
28. Jin GH, Chen LX, Deng XW, Liu XW, Huang Y, Huang XB. A comparative dosimetric study for treating left-sided breast cancer for small breast size using five different radiotherapy techniques: conventional tangential field, filed-in-filed, tangential-IMRT, multi-beam IMRT and VMAT. *Radiat Oncol*. 2013 Apr 15;8:89.