

Hepatobiliary excretion of ^{99m}Tc -EC: A potential source of mistake in the interpretation of renal scintigraphy

Mahdi Haghghatafshar and Tahereh Ghaedian

Nuclear Medicine and Molecular Imaging Research Center,
Namazi Teaching Hospital, Shiraz University of Medical Sciences, Shiraz, Iran

(Received 4 October 2017, Revised 17 April 2018, Accepted 19 April 2018)

ABSTRACT

A 10-year-old boy with a history of bloody discoloration of urine following recent appendectomy was referred to our department for urinary leakage/fistula evaluation. A renal Technetium-99m-L,L-ethylenedicysteine (^{99m}Tc -EC) scintigraphy was performed. After injection of radiotracer, a focus of activity appeared in the supralateral part of the right kidney which was confirmed as accumulation of radiotracer in the gall bladder by SPECT and delayed images. Although it is stated that the biliary excretion of ^{99m}Tc -EC is negligible, in some cases it could be prominent and potential source of misinterpretation.

Key words: ^{99m}Tc -EC; Renal scintigraphy; Hepatobiliary excretion; SPECT

Iran J Nucl Med 2018;26(2):121-123

Published: July, 2018

<http://irjnm.tums.ac.ir>

Corresponding author: Dr Tahereh Ghaedian, Nuclear Medicine and Molecular Imaging Research Center, Namazi Teaching Hospital, Shiraz University of Medical Sciences, Shiraz, Iran. E-mail: tghaedian@gmail.com

CASE REPORT

A 10-year old boy presented with gross bloody discoloration of the urine and stool as described by himself and his mother. Serum creatinine and blood urea nitrogen level were within the normal limits. The patient had a history of appendectomy 2 months before this presentation. Although occult blood test and urinalysis were negative for evidence of blood, the patient was further evaluated by colonoscopy and ^{99m}Tc -red blood cell (RBC) scintigraphy which were negative as well. Due to continuation of the patient's complaint during hospital admission, he was referred for cystoscopy and renal scintigraphy to evaluate the possibility of traumatized urinary tract and fistula. Technetium-99m-L,L-ethylenedicysteine ($^{99m}\text{Tc-EC}$) renal imaging was performed (Figures 1 and 2). Immediately after intravenous injection of 15 mCi $^{99m}\text{Tc-EC}$, dynamic perfusion (2 second/frame) and

function (1 minutes/frame) images were obtained in the anterior and posterior projections. After 25th minute of the study, a focus of activity appeared in the supralateral aspect of the right kidney in anterior projections (Figure 1B) which was confirmed as the accumulation of the radiotracer in the gall bladder by single-photon computed tomography (SPECT) (Figure 2A). Delayed 12-hour images also revealed clear evidence of accumulation of activity in the proximal colon, indicating excretion of radiotracer through the biliary system into the gastrointestinal tract. This case was further followed up and finally diagnosed as malingering in view of negative results in all work-ups. Although biliary excretion of $^{99m}\text{Tc-EC}$ is reported to be negligible, in some cases as ours, could be prominent enough to be misinterpreted as an abnormal collection.




Fig 1. Dynamic images of $^{99m}\text{Tc-EC}$ renal scintigraphy in posterior (A) and anterior (B) projections in a 10 year old boy with a history of gross hematuria. The scan reveals a focus of activity appearing from minute 25 in the supralateral part of the right kidney only seen in the anterior projections (B).

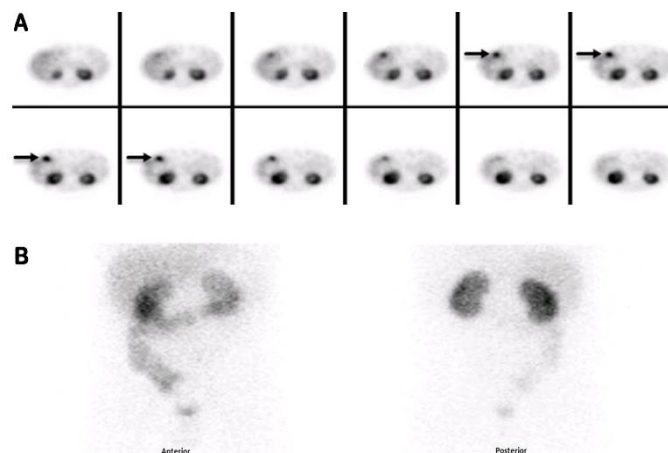


Fig 2. Single-photon emission computed tomography (SPECT) 40 minutes after the injection of radiotracer also shows a zone of accumulation of activity which is apart from the right kidney and is located in the anterior part of the right upper quadrant of the abdomen corresponding to the site of gallbladder (A). Delayed 12 hour static images showed prominent colon activity and confirmed the considerable entrance of activity into the gastrointestinal tract (B) which could be potentially mistaken for the presence of urinary leak or fistula.

DISCUSSION

As compared to other tubular radiotracers, ^{99m}Tc-MAG₃ is known to have about 10% potential biliary excretion, which can potentially mimic urinary leakage [1, 2]. Thus, most studies have suggested that ^{99m}Tc-EC is a better alternative for evaluation of urinary leakage due to lower biliary excretion even in patients with chronic renal failure [3, 6].

Although some animal studies have demonstrated significant hepatic clearance of ^{99m}Tc-EC, especially in pigs [7], most human studies revealed low extra-renal clearance of ^{99m}Tc-EC [8]. Even in anuric patients, ^{99m}Tc-EC showed lower extra-renal clearance as compared to ¹³¹I-ortho-iodohippurate with image quality comparable to ^{99m}Tc-MAG₃ [6, 8].

Zakko et al. found a 0.4% incidence of gall bladder visualization in ^{99m}Tc-EC renal scintigraphy [9]. Similar to ^{99m}Tc-MAG₃, impaired renal function, kit impurities, erroneous kit preparation or drug interaction may lead to higher hepatic clearance of ^{99m}Tc-EC [10, 11]. However, our case had no evidence of renal dysfunction with negative history of any interfering medication. In addition, no kit impurity is suspected, while quality control results were acceptable.

Though it has not been clearly determined, the presence of different isomers of ^{99m}Tc-EC in the kit or interaction with some drugs may be the most responsible cause for gallbladder visualization in some patients [12].

Generally, the possibility of biliary excretion of ^{99m}Tc-EC, despite its rarity, should be considered during interpretation of the scans, especially when urinary leakage or fistula are suspected [11]. In these situations, origin of intestinal activity (biliary/urinary) should be interpreted, cautiously. As shown in Figure 2B, SPECT images can contribute to localization of the gall bladder; we suggest an early SPECT or SPECT/computed tomography (CT) in patients suspicious for urinary leakage [10, 13]. Mechanism of prominent biliary excretion of ^{99m}Tc-EC requires further evaluations.

CONCLUSION

Although it is stated that the biliary excretion of ^{99m}Tc-EC is negligible, in some cases it could be prominent and potential source of misinterpretation.

Acknowledgements

The authors would like to thank the Research Consultation Center (RCC) at Shiraz University of Medical Sciences for their invaluable assistance in editing this manuscript.

REFERENCES

1. Dogan AS, Kirchner PT. Hepatobiliary excretion of MAG₃. Simulation of a urinary leak. *Clin Nucl Med.* 1993 Sep;18(9):746-50.
2. Niederkohr RD, McDougall IR. Incidental gallbladder visualization on nonhepatobiliary nuclear medicine studies: case series and review of the literature. *Clin Nucl Med.* 2007 Dec;32(12):915-9.
3. Beiki D, Eftekhari M, Fallahi B, Gheisari F, Hozhabrosadati M, Fard-Esfahani A, Takavar A, Gholamrezanezhad A, Saghari M, Ansari Gilani K. Comparative scintigraphic study of renal function with ^{99m}Tc-Mercaptoacetyl-triglycine and ^{99m}Tc-Ethylenedicysteine. *DARU J. Pharm. Sci.* 2008;16(1):41-6.
4. Durand E, Chaumet-Riffaud P, Grenier N. Functional renal imaging: new trends in radiology and nuclear medicine. *Semin Nucl Med.* 2011 Jan;41(1):61-72.
5. Kibar M, Noyan A, Anarat A. ^{99m}Tc-N,N-ethylenedicysteine scintigraphy in children with various renal disorders: a comparative study with ^{99m}Tc-MAG₃. *Nucl Med Commun.* 1997 Jan;18(1):44-52.
6. Prvulovich EM, Bomanji JB, Waddington WA, Rudrasingham P, Verbruggen AM, Ell PJ. Clinical evaluation of technetium-99m-L,L-ethylenedicysteine in patients with chronic renal failure. *J Nucl Med.* 1997 May;38(5):809-14.
7. Nielsen SS, Poulsen EU, Marqvorsen J, Nielsen LE, Bacher T, Rehling M. Clearance and renal extraction of technetium-99m-L,L-ethylenedicysteine, ¹³¹I-ortho-iodohippurate and ¹²⁵I-iothalamate in pigs. *Clin Physiol.* 1999 Jul;19(4):338-43.
8. Kabasakal L. Technetium-99m ethylene dicysteine: a new renal tubular function agent. *Eur J Nucl Med.* 2000 Mar;27(3):351-7.
9. Zakko S, Mrhac L, Al-Bahri J, Al-Shamsi H, Lootah S, Benjamin RJ. Biliary excretion of Tc-99m EC in renal studies. *Clin Nucl Med.* 1998 Jul;23(7):417-9.
10. Jain TK, Phulsunga RK, Gupta N, Sood A, Bhattacharya A, Mittal BR. Vicarious liver visualization in solitary functioning kidney with technetium-99m ethylenedicysteine renal scintigraphy. *Indian J Nucl Med.* 2015 Jul-Sep;30(3):272-4.
11. Arora G, Damle NA, Tripathi M, Bal C, Kumar P. Vicarious visualization of gall bladder on Tc-99m ethylene dicysteine renal dynamic study. *Indian J Nucl Med.* 2012 Oct;27(4):257-8.
12. Verbruggen AM, Nosco DL, Van Nerom CG, Bormans GM, Adriaens PJ, De Roo MJ. Technetium-99m-L,L-ethylenedicysteine: a renal imaging agent. I. Labeling and evaluation in animals. *J Nucl Med.* 1992 Apr;33(4):551-7.
13. Ngai S, Stuckey SL. Peri-aortofemoral prosthesis urinoma: diagnosis by Tc-99m MAG₃ SPECT/CT and differentiation from simultaneous hepatobiliary excretion. *Clin Nucl Med.* 2008 May;33(5):337-9.