

A wandering spleen detected by ^{99m}Tc -denatured RBC scan

Somayeh Ghahremani¹, Mahsa Sabour¹, Sara Ghahremani²,
Ahmad Bazrafshan², Ramin Sadeghi¹

¹Nuclear Medicine Research Center, Mashhad University of Medical Sciences, Mashhad, Iran

²Neonatal Research Center, Mashhad University of Medical Sciences, Mashhad, Iran

(Received 18 September 2017, Revised 28 October 2017, Accepted 29 October 2017)

ABSTRACT

A 23 day old infant patient underwent ^{99m}Tc -denatured RBC scanning for locating possible ectopic spleen in our department. The scan showed no tracer activity in normal splenic bed in the left upper quadrant and an ectopic spleen was shown on the right side of abdomen inferior to the liver. ^{99m}Tc -denatured RBC scan is an easy and available method for splenic localization in pediatric patients.

Key words: Spleen; Ectopic; Denatured RBC; Scintigraphy

Iran J Nucl Med 2018;26(1):66-67

Published: January, 2018

<http://irjnm.tums.ac.ir>

Corresponding author: Dr. Ramin Sadeghi, Nuclear Medicine Research Center, Mashhad University of Medical Sciences, Mashhad, Iran. E-mail: sadeghir@mums.ac.ir

CASE REPORT

The patient was a 23 day-old boy who was hospitalized for left congenital diaphragmatic hernia and underwent surgical treatment, during surgical repair of hernia, spleen was not visualized in the left upper quadrant (which is the normal location of the spleen). Ultrasonographic evaluation was performed and although liver, pancreas, kidneys and bladder were reported normal, spleen was not visible.

Therefore patient was referred to nuclear medicine department for ^{99m}Tc -RBC denatured scanning. In our department after RBC labeling with ^{99m}Tc -pertechnetate (Iranian Atomic Energy Organization, Pars Isotope), the vial was placed in 49.5°C water for 15 minutes for denaturation [1-4]. The patient received IV injection of 0.25 mCi labeled tracer as recommended by Ehrlich et al. Static images in anterior view was performed 30 minutes after IV injection of the radiotracer from the abdominal and pelvis regions, using a dual head variable angle gamma camera with Tc-99m photopeak and low energy high resolution collimator (ECAM, Siemens). No tracer activity was noted in the normal splenic bed in the left upper quadrant of the abdomen and tracer activity appeared on the right side of the abdomen inferior to liver. The images have been truncated for spleen activity and bone marrow was not visible (Figure 1). Another ultrasonography showed the spleen in the location found in scintigraphy.

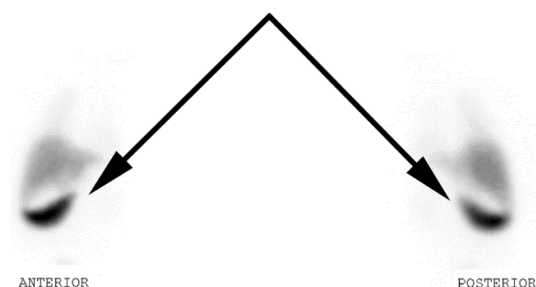


Fig 1. ^{99m}Tc -denatured RBC scintigraphy of the patient. Note the wandering spleen on the right side of the abdomen.

DISCUSSION

Wandering spleen, also known as ectopic spleen is an uncommon congenital disorder [5]. The most common age of diagnose of this situation is in childhood, especially under 1 year of age. Unfortunately it is commonly misdiagnosed until complicated by torsion [6]. This condition is manifested by abdominal pain and abdominal mass due to torsion of the hypermobile spleen [1, 7, 8]. Splenic scintigraphy with ^{99m}Tc -denatured RBC is an excellent method for detection of ectopic spleen [1]. The method of preparation is relatively simple and available and requires small blood volume. Different recommendations can be

found in the literature regarding the time-temperature used for preparation of the radiotracer. The recommended temperature is usually 49.5°C , and the time of preparation varies from 10 minutes to 20 minutes [2]. In these cases ^{99m}Tc -Sulfur Colloid can be performed too, but may interfere with overlapping left hepatic lobe and probable splenic pathology with poor radiocolloid uptake which precludes visualization [3].

CONCLUSION

^{99m}Tc -denatured RBC can be recommended for detection of splenic tissue (ectopic, remnant or a wandering spleen) even in small children.

REFERENCES

1. Ehrlich CP, Papanicolaou N, Treves S, Hurwitz RA, Richards P. Splenic scintigraphy using Tc-99m-labeled heat-denatured red blood cells in pediatric patients: concise communication. *J Nucl Med.* 1982 Mar;23(3):209-13.
2. Burdine JA Jr, Legeay R. Spleen scans with 99mTc-labeled heated erythrocytes. *Radiology.* 1968 Jul;91(1):162-4.
3. Armas RR. Clinical studies with spleen-specific radiolabeled agents. *Semin Nucl Med.* 1985 Jul;15(3):260-75.
4. Daliri M, Shafiei S, Zakavi SR, Dabbagh Kakhki VR, Sadeghi R. Application of 99mTc-denatured red blood cells scintigraphy in the evaluation of post-traumatic spleen auto-transplantation. *Rev Esp Med Nucl Imagen Mol.* 2013 May-Jun;32(3):209-10.
5. Blouhos K, Boulas KA, Salpigktidis I, Baretas N, Hatzigeorgiadis A. Ectopic spleen: An easily identifiable but commonly undiagnosed entity until manifestation of complications. *Int J Surg Case Rep.* 2014;5(8):451-4.
6. Allen KB, Andrews G. Pediatric wandering spleen--the case for splenectomy: review of 35 reported cases in the literature. *J Pediatr Surg.* 1989 May;24(5):432-5.
7. Bhanumathi V, Balkishan B, Masood SV. Torsion of wandering spleen in a woman presenting as emergency. *Indian J Surg.* 2013 Feb;75(1):59-61.
8. King CR, Mansuria S. Pelvic pain in the presence of wandering spleen. *J Minim Invasive Gynecol.* 2013 Sep-Oct;20(5):549-50.