

Unusual false-positive results of whole-body ^{131}I scintigraphy: Four different case scenarios

Alireza Emami-Ardekani¹, Hamidreza Amini¹, Sara Harsini^{1,2,3},
Armaghan Fard-Esfahani¹, Mohammad Eftekhari¹

¹Research Center for Nuclear Medicine, Tehran University of Medical Sciences, Tehran, Iran

²Students' Scientific Research Center (SSRC), Tehran University of Medical Sciences, Tehran, Iran

³Association of Nuclear Medicine and Molecular Imaging (ANMMI), Universal Scientific Education and Research Network (USERN), Tehran, Iran

(Received 16 February 2019, Revised 19 May 2019, Accepted 23 May 2019)

ABSTRACT

Post-treatment or diagnostic whole-body radioiodine scintigraphy is widely used to assess the residual, recurrence, or metastases of differentiated thyroid carcinoma because of the high sensitivity and accuracy that this assessment provides. While bearing in mind all the diagnostic potential of this test, we have to consider its' potential pitfalls, as well. Herein, we present 4 patients with differentiated thyroid carcinoma, who received ^{131}I for ablation therapy after having undergone total thyroidectomy. On post-treatment radioiodine scintigraphy, foci of unusual ^{131}I uptake were noted in facial, axillary, inguinal, and renal regions, which were finally either histologically or anatomically diagnosed as papillary oncocytic cystadenoma, ectopic axillary breast tissue, epididymal cyst, and simple renal cyst, respectively. Such ^{131}I uptake patterns underscore the value of recognizing where and why false-positive uptakes take place and should appreciate the potential causes of false-positive results in whole-body ^{131}I scintigraphy.

Key words: Radioiodine; Differentiated thyroid carcinoma; Whole-body scan

Iran J Nucl Med 2019;27(2):149-153

Published: July, 2019

<http://irjnm.tums.ac.ir>

Corresponding author: Dr. Sara Harsini, Research Center for Nuclear Medicine, Tehran University of Medical Sciences, Tehran, Iran. E-mail: sara.harsini@gmail.com

INTRODUCTION

Differentiated thyroid cancer is a favorable malignant tumor, for the diagnosis and treatment of which, radioiodine has been used for more than five decades according to the fact that trapping, organification, and storage of iodine is notably higher in functioning thyroid tissues than other tissues [1, 2]. Radioiodine whole body scintigraphy (WBS) is an integral part of the decision making in subsequent radioiodine therapy as an adjunct to surgery, for ablation of remnant thyroid tissue or for the treatment of metastatic lesions. The optimal management of patients with thyroid cancer and the avoidance of futile exposure to high-dose radioiodine are dependent on the precise interpretation of radioiodine WBS. The appearance of abnormal focal uptake of ^{131}I in a diagnostic WBS is considered highly specific; however, there are a considerable number of false-positive cases of radioiodine uptakes in several organs. In spite of the fact that the exact mechanism is not fully understood, such unexpected uptakes could be attributed to: (a) functional sodium-iodide symporter expression [the key mechanism of radioiodine uptake in functioning thyroid tissues [3] in normal tissues, including salivary glands, breast, thymus, gastrointestinal tract, or several benign and malignant tumors, (b) contamination by physiologic secretions, (c) retention of radioiodinated body fluids, (d) metabolism of radioiodinated thyroid hormone, (e) retention of radioiodine in inflamed tissue, or 6. other unknown mechanisms [4]. The potential false-positive scan patterns underline the significance of the evaluation of a patient with suspected residual or recurrent thyroid cancer with dedicate attention to clinical history, physical examination, scintigraphic findings, other anatomical imaging, and available biochemical data.

False-positive WBSs are presumed to be infrequent, although their precise prevalence is yet unknown. The following clinical cases demonstrate examples of apparently false-positive scans, some of which have been problematic to diagnose.

CASE PRESENTATION

Case 1

A 72-year-old man presented with a history of papillary thyroid carcinoma and cervical lymph node involvement for which he underwent total thyroidectomy with lymph node dissection and received an ablative dose of 150 mCi of ^{131}I ten years ago. Afterward, he underwent two more courses of radioiodine therapy with 150 mCi of ^{131}I due to the presence of biochemical and structural incomplete responses. Diagnostic WBS was performed 12 months after the third ^{131}I therapy and revealed a focus of intense radiotracer uptake in the right parotid gland, with no evidence of any other regional or distant metastasis (Figure 1). At the same time, increased

serum thyroglobulin (Tg) level (Tg: 32 ng/mL) was noted. The patient was submitted to right parotidectomy and right neck lymph node dissection, with suspicion of parotid involvement by metastatic papillary carcinoma of thyroid, while the pathologic examination demonstrated the presence of papillary oncocytic cystadenoma in a mostly atrophic right parotid gland and right cervical lymph node involvement by metastatic PTC was confirmed. The patient subsequently received 150 mCi of ^{131}I .

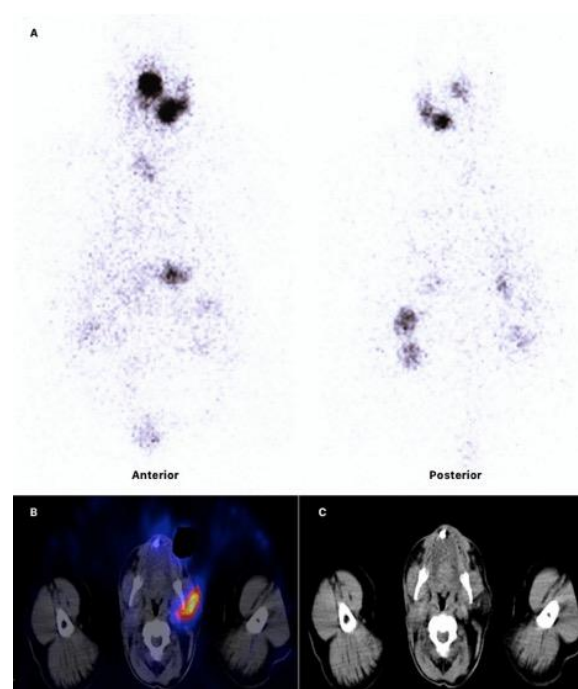


Fig 1. Papillary oncocytic cystadenoma in a mostly atrophic right parotid gland. (A) planar scintigraphy. (B) SPECT/CT. (C) CT. A focus of intensive radiotracer uptake is noted in the right parotid gland (A-C).

Case 2

A 62-year-old man underwent total thyroidectomy with histopathological diagnosis of papillary thyroid carcinoma and received 100 mCi of ^{131}I for ablation (first ^{131}I therapy). He underwent the second and third courses of radioablation with 150 mCi of ^{131}I due to structural incomplete response, as well. The third post-treatment scan was positive in the cervical region, as well as in the left kidney and right hemi-scrotum suggesting the presence of cervical lymph node involvement, metastatic involvement of the left kidney and right hemi-scrotum (Figure 2). However, the ultrasonographic study showed a cortical cyst with the diameter of 74 mm in the lower pole of the left kidney, corresponding to the focus of radioiodine uptake, together with a septated cystic lesion measuring 70*40*56 mm with internal echo on the upper portion of the right testis, corresponding to the right hemi-

scrotum ^{131}I uptake suggesting the existence of an epididymal cyst.

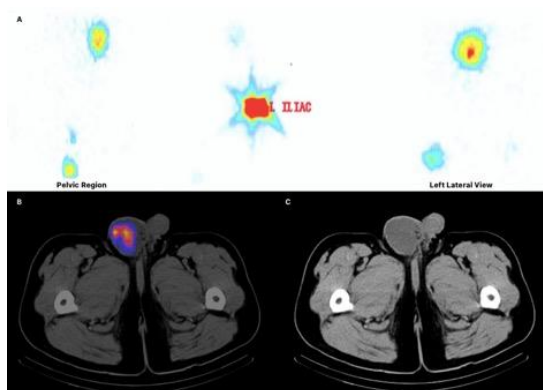


Fig 2. Epididymal cyst on the upper portion of the right testis. (A) planar scintigraphy. (B) SPECT/CT. (C) CT. Images depict increased radio-iodine uptake in the cervical region, left kidney and the right hemi-scrotum.

Case 3

A 40-year-old female, presented with a two-year history of swelling in the neck, underwent total thyroidectomy with histopathology report of papillary thyroid carcinoma with capsular and lymphatic invasion, as well as cervical lymph node metastatic involvement. This was followed by a 150 mCi ablative ^{131}I therapy. The post-therapy scan showed tracer uptake in the right axilla, first suspected to be a subdermal nodule (Figure 3).

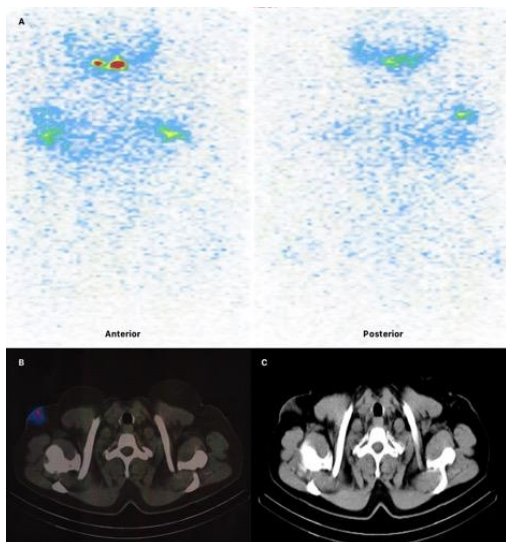


Fig 3. Ectopic axillary breast tissue. (A) planar scintigraphy. (B) SPECT/CT. (C) CT. Images revealed tracer uptake in the right axilla (A-C).

However, additional single photon emission computed tomography (SPECT)-CT imaging suggested this

focus of increased radioiodine activity as breast tissue, which was subsequently confirmed by ultrasonography, demonstrating a hypoechoic focus of 25*10 mm without vascular structures in the right axillary region, verifying the presence of ectopic axillary breast tissue.

Case 4

A 65-year-old female had undergone total thyroidectomy for follicular thyroid carcinoma ten years earlier had received 100 mCi radioiodine for thyroid remnant ablation. She was lost to follow up during the last 10 years. The patient experienced left hip pain and deteriorating claudication within the past 6 months. The serum thyroglobulin level was found to be as high as greater than 500 ng/mL. Ultrasonography demonstrated no remnant thyroid tissue or cervical lymph node involvement. However, the magnetic resonance imaging (MRI) of the left hip depicted an oval-shaped well defined intramedullary lesion in the proximal femoral neck and proximal shaft with maximum diameters of 64*42*35 mm with mild perilesional bone marrow edema. Additionally, the spiral chest CT scan with contrast revealed the presence of a few pulmonary nodules measuring 12 mm, 5 mm and 5 mm in the right lower lobe and 9 mm and 3 mm in the left lower lobe, which were in favor of pulmonary metastases. Thereafter, the patient underwent the left hip mass biopsy, proven to be metastatic follicular carcinoma from thyroid origin. Therefore, 200 mCi ^{131}I was administered and the whole-body ^{131}I scintigraphy was performed after 7 days.

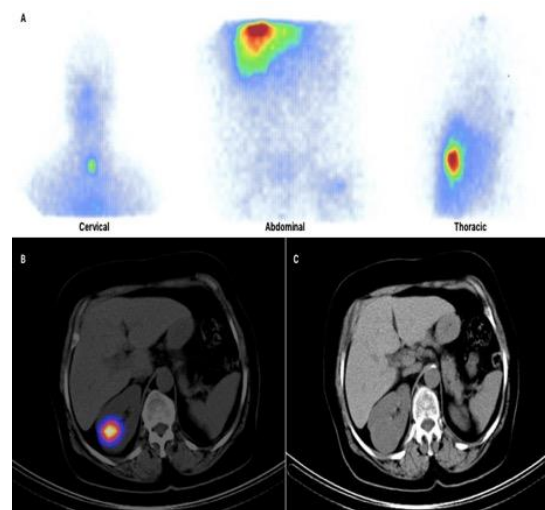


Fig 4. Remnant thyroid tissue in the thyroid bed, metastatic involvement of both lungs and the proximal portion of the left femur were depicted on planar scintigraphy (A). Also, an ill-defined lesion with intense radiotracer uptake was noted in the cortex of the right kidney on SPECT/CT (B) and CT images (C). This intense activity in the cortex of the right kidney corresponds to a cystic lesion of the right kidney with physiologic uptake.

The whole body scan demonstrated remnant thyroid tissue in the thyroid bed, metastatic involvement of both lungs and the proximal portion of the left femur. In addition, as we noticed intense radioiodine uptake in the liver on the planar images, hepatic metastasis was assumed, therefore, subsequent SPECT-CT imaging was carried out. Surprisingly, the liver was found to be intact, while an ill-defined lesion with intense radiotracer uptake in the lateral border of the right kidney (Figure 4), found to be a simple renal cyst, was noted, which was previously overlooked on the planar images.

DISCUSSION

¹³¹I is mainly utilized for proper detection and treatment of thyroid remnants and metastasis of DTC after total thyroidectomy. Together with serum thyroglobulin level, ¹³¹I whole-body imaging is used in the follow-up evaluation of DTC. ¹³¹I uptake outside the normal thyroid bed is commonly considered as metastatic disease. False positive findings in WBS, the incidence of which increases with the dose used for diagnostic scanning following post therapeutic doses [5], do occur, and may pose potential problems in the management of patients with DTC. Recognition of such false-positive scan findings is of utmost significance, so as to hinder costly additional investigation and inappropriate therapy, which may be associated with side effects such as gastritis, sialadenitis, malignancies, and worsening of the pulmonary disease with lung fibrosis [6]. To reach this goal, it is required to interpret ¹³¹I WBS uptakes on the basis of the clinical context, imaging, and laboratory findings (i.e., serum Tg and anti-Tg AB). Any abnormal uptake outside the thyroid bed visualized on the radioiodine scan must be carefully investigated and possible alternative reasons for such finding need special consideration. A systematic approach is needed to analyze the scan thoroughly, and this could help discriminating the physiological radioiodine uptake in the salivary glands, stomach, gastrointestinal, and urinary tracts, as well as the diffuse uptake in the liver in most patients with functioning thyroid at the time of their post-radioiodine ablation scan.

Contamination must also be a consideration specially when the radioiodine uptake are detected outside the physiologic regions [7]. Discordant serum thyroglobulin or clinical history, namely, low-risk thyroid cancer, previous negative imaging, or complete surgical removal, are among the key factors helping to consider a possible false positive uptake. Additional imaging modalities, including bone scintigraphy, CT, MRI, and SPECT-CT are proposed to avoid unnecessary treatment. As outlined in the above-mentioned cases, the incremental value of ¹³¹I SPECT-CT fusion imaging for problem-solving and

the evaluation of unusual radioactivity distributions is unquestionable. The synergistic combination of functional and anatomic data provided by SPECT-CT, applied either selectively or routinely to planar scintigraphy studies, has been shown to exert many advantages over traditional planar imaging in various clinical settings. These advantages include accurate anatomic localization and characterization of radioiodine foci as benign or malignant in cervical nodal or distant metastases. CT-based attenuation correction capacitates the SPECT/CT to disclose more foci of pathologic activity as compared to planar studies. It is also well understood that the iodine avidity and size of metastatic lesions evaluated on SPECT-CT studies, could provide information about the possibility of response to ¹³¹I therapy and facilitate therapeutic decision-making. SPECT-CT is regarded as an excellent diagnostic tool for rapid evaluation of unusual patterns of radioiodine biodistribution and suspected physiologic mimics, such as those attributed to radioiodine distribution in salivary glands, retrosternal goiter, esophageal or airway secretions, bowel diverticula, dental fillings, hiatal hernias, skin contamination, breast and benign uptake related to radioiodine retention in cysts, bronchiectasis, menstruating uterus, benign struma ovarii, thymus and many others outlined in previous reports, which are known to raise a diagnostic dilemma on planar scintigraphy interpretation [8-14].

Confirmed undetectable thyroglobulin levels and the above-mentioned imaging strategies could help support the benign origin of some radioiodine uptake patterns. However, the case is more complicated when such data are not available and when the clinician confronts either an increasing level of serum Tg or previously unfavorable histology of the thyroid carcinoma, history of positive WBSs for metastatic disease or remnant thyroid tissue, the situations similar to our cases, delineating the importance of clinicians' awareness of the potential pitfalls of WBS and of the mechanisms involved. In summary, the spurious images warrants a multidisciplinary approach by nuclear medicine specialists, endocrinologists, and radiologists, and this results in the preclusion of unjustified diagnostic procedures and inappropriate treatments.

In this report we try to outline part of the spectrum of false-positive WBSs, which might be encountered following administration of radioiodine in the management of differentiated thyroid cancers.

REFERENCES

1. Wartofsky L, Van Nostrand D. Thyroid cancer: a comprehensive guide to clinical management: New York: Springer-Verlag; 2016.

2. Ahn BC. Sodium iodide symporter for nuclear molecular imaging and gene therapy: from bedside to bench and back. *Theranostics*. 2012;2(4):392-402.
3. Riesco-Eizaguirre G, Santisteban P. A perspective view of sodium iodide symporter research and its clinical implications. *Eur J Endocrinol*. 2006 Oct;155(4):495-512.
4. Oh J-R, Ahn B-C. False-positive uptake on radioiodine whole-body scintigraphy: physiologic and pathologic variants unrelated to thyroid cancer. *Am J Nucl Med Mol Imaging*. 2012;2(3):362-385.
5. Waxman A, Ramanna L, Chapman N, Chapman D, Brachman M, Tanasescu D, Berman D, Catz B, Braunstein G. The significance of I-131 scan dose in patients with thyroid cancer: determination of ablation: concise communication. *J Nucl Med*. 1981 Oct;22(10):861-5.
6. Triggiani V, Moschetta M, Giagulli VA, Licchelli B, Guastamacchia E. Diffuse ¹³¹I lung uptake in bronchiectasis: a potential pitfall in the follow-up of differentiated thyroid carcinoma. *Thyroid*. 2012 Dec;22(12):1287-90.
7. Carlisle MR, Lu C, McDougall IR. The interpretation of ¹³¹I scans in the evaluation of thyroid cancer, with an emphasis on false positive findings. *Nucl Med Commun*. 2003 Jun;24(6):715-35.
8. Zhao LX, Li L, Li FL, Zhao Z. Rectus abdominis muscle metastasis from papillary thyroid cancer identified by I-131 SPECT/CT. *Clin Nucl Med*. 2010 May;35(5):360-1.
9. von Falck C, Beer G, Gratz KF, Galanski M. Renal metastases from follicular thyroid cancer on SPECT/CT. *Clin Nucl Med*. 2007 Sep;32(9):751-2.
10. Aide N, Lehembre E, Gervais R, Bardet S. Unusual intratracheal metastasis of differentiated thyroid cancer accurately depicted by SPECT/CT acquisition after radioiodine ablation. *Thyroid*. 2007 Dec;17(12):1305-6.
11. Agriantonis DJ, Hall L, Wilson MA. Utility of SPECT/CT as an adjunct to planar whole body I-131 imaging: liver metastasis from papillary thyroid cancer. *Clin Nucl Med*. 2009 Apr;34(4):247-8.
12. Jong I, Taubman K, Schlicht S. Bronchiectasis simulating pulmonary metastases on iodine-131 scintigraphy in well-differentiated thyroid carcinoma. *Clin Nucl Med*. 2005 Oct;30(10):688-9.
13. Rachinsky I, Driedger A. Iodine-131 uptake in a menstruating uterus: value of SPECT/CT in distinguishing benign and metastatic iodine-positive lesions. *Thyroid*. 2007 Sep;17(9):901-2.
14. Avram AM. Radioiodine scintigraphy with SPECT/CT: an important diagnostic tool for thyroid cancer staging and risk stratification. *J Nucl Med*. 2012 May;53(5):754-64.