

Covid-19 manifestation on Tl-201 myocardial perfusion SPECT/CT

Forough Kalantari^{1,2}, Ghasemali Divband¹, Mohsen Beheshti^{1,3},
Elham Kalantari⁴, Nahid Yaghoobi⁵

¹Department of Nuclear Medicine, Jam Hospital, Tehran, Iran

²Department of Nuclear Medicine, Rasoul Akaram Hospital, Iran University of Medical Sciences, Tehran, Iran

³Department of Nuclear Medicine, University Hospital RWTH, Aachen, Germany

⁴Department of Pulmonology, Isfahan University of Medical Science, Isfahan, Iran

⁵Department of Nuclear Medicine, Rajaie Cardiovascular Medical and Research Center,
Iran University of Medical sciences, Tehran, Iran

(Received 15 July 2020, Revised 30 July 2020, Accepted 12 August 2020)

ABSTRACT

A 67 years old woman was referred to nuclear medicine center for myocardial perfusion imaging (MPI) for assessment of ischemic heart diseases (IHD). She had a history of atypical chest pain and dyspnea since about 10 days before admission. The MPI SPECT/CT was performed by stress/redistribution Tl-201 protocol. MPI was interpreted as relatively good coronary flow with no appreciable stress induced ischemia. SPECT-CT images revealed multifocal, bilateral and peripheral ground-glass opacities in lungs with subtle background uptake of Tl-201. Considering Covid-19 outbreak, the first diagnosis based on chest CT was Covid-19. This case emphasizing importance of attention to non-cardiac findings in patients undergoing myocardial perfusion imaging, especially review of lung window images in SPECT/CT protocols in the era of covid-19.

Key words: Covid-19; Myocardial perfusion imaging; Tl-201; SPECT/CT

Iran J Nucl Med 2021;29(1):32-34

Published: January, 2021

<http://irjnm.tums.ac.ir>

Corresponding author: Dr. Forough Kalantari, Department of Nuclear Medicine, Rasoul Akaram Hospital, Iran University of Medical Sciences, Tehran, Iran. E-mail: foroughkalantari@gmail.com

CASE PRESENTATION

A 67 years old woman was referred to our nuclear medicine center for myocardial perfusion imaging (MPI) for assessment of ischemic heart diseases (IHD). She had a history of atypical chest pain and dyspnea since about 10 days before admission. Dyspnea was on exertion at first getting worse gradually being even at rest in the days before admission. Her past medical history was remarkable for history of diabetes and hyperlipidemia since 4 years before and being on anti-hypertensive drugs in the past 15 years. Because the shortage of $^{99}\text{Mo}/^{99\text{m}}\text{Tc}$ -generator during the covid-19 pandemic, the MPI was performed by stress/redistribution Tl-201 protocol. Pharmacologic stress test was done by infusion of 0.56 mg/kg

dipyridamole over a period of 4 min. A dose of 111 MBq (3.0 mCi) of Tl-201 was injected at 7 min, and initial images (stress phase) were obtained immediately with the Siemens Symbia Intevo SPECT/CT dual-head variable angle gamma camera.

MPI was interpreted as relatively good coronary flow with no appreciable stress induced ischemia. There was no wall motion or wall thickening abnormality. Left ventricular ejection fraction (LVEF) derived from MPI was within normal range. SPECT-CT scan images revealed multifocal, bilateral and peripheral ground-glass opacities in lungs with subtle background uptake of Tl-201 (Figures 1 and 2).

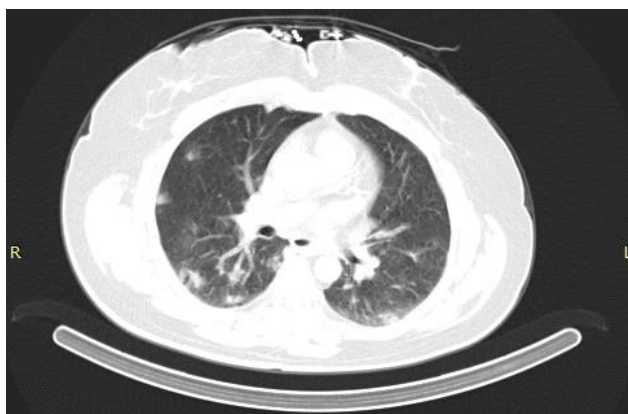

Fig 1. CT images in lung window showed multifocal, bilateral and peripheral ground glass opacities in lungs.

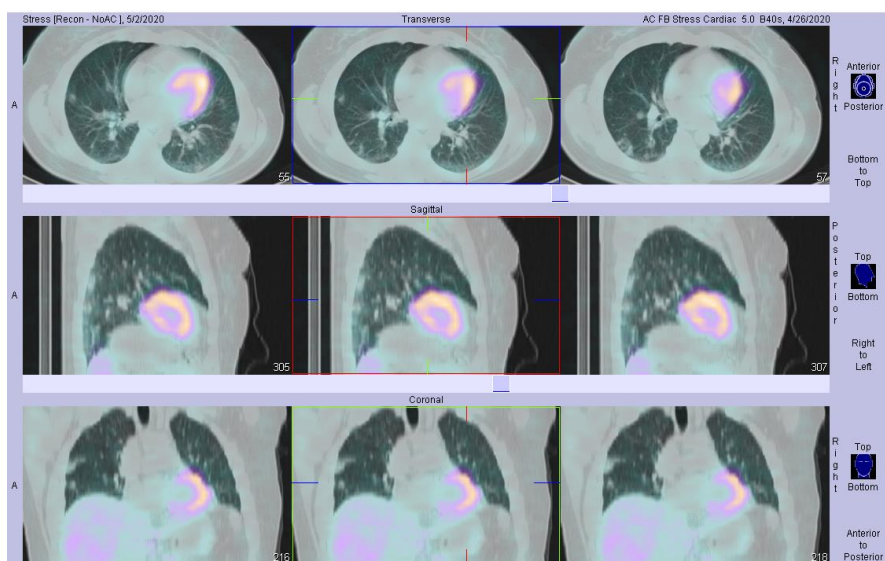


Fig 2. SPECT/CT fused images in lung window showed multifocal, bilateral and peripheral ground glass opacities throughout lungs with subtle background uptake of Tl-201.

After interpreting chest CT, we asked some supplementary questions from the patient. She has complained new onset of dyspnea on exertion and weakness, without cough, fever or coryza symptoms. Considering recent Covid-19 outbreak, the first diagnosis based on chest CT was Covid-19 [1, 2]. In current outbreak some cases had the incubation period approximately four to five days after exposure and most cases presented with no or mild pneumonia [3]. The patient was advised to perform a PCR test for evaluation of Covid-19 infection, but she denied. She was treated with azithromycin for one week by her family physician. However, in one-month follow-up visit, her symptoms were significantly improved.

DISCUSSION

This case emphasizing importance of attention to non-cardiac findings in patients undergoing myocardial perfusion imaging, especially review of lung window images in SPECT/CT protocols in the era of covid-19.

In addition, recent guidance and best practices for nuclear cardiology laboratories during the coronavirus disease 2019 (COVID-19) pandemic, released by ASNC and SNMMI recommended that CT images acquired for attenuation correction should be interpreted in the context of possible COVID-19 pulmonary findings [4]. These images should be reviewed before patient is discharged from nuclear medicine department [5].

REFERENCES

1. Hindle-Katel W, Oen-Hsiao J, Lussnig E, Miller EJ. Incidental finding of COVID-19 pulmonary infiltrates on SPECT/CT attenuation correction CT. *J Nucl Cardiol*. 2020 Aug;27(4):1385-1386.
2. Amini H, Divband G, Montahaei Z, Dehghani T, Kaviani H, Adinehpour Z, Akbarian Aghdam R, Rezaee A, Vali R. A case of COVID-19 lung infection first detected by [18F]FDG PET-CT. *Eur J Nucl Med Mol Imaging*. 2020 Jul;47(7):1771-1772.
3. Kakimoto K, Kamiya H, Yamagishi T, Matsui T, Suzuki M, Wakita T. Initial Investigation of Transmission of COVID-19 Among Crew Members During Quarantine of a Cruise Ship - Yokohama, Japan, February 2020. *MMWR Morb Mortal Wkly Rep*. 2020 Mar 20;69(11):312-313.
4. Skali H, Murthy VL, Al-Mallah MH, Bateman TM, Beanlands R, Better N, Calnon DA, Dilsizian V, Gimelli A, Pagnanelli R, Polk DM, Soman P, Thompson RC, Einstein AJ, Dorbala S. Guidance and best practices for nuclear cardiology laboratories during the coronavirus disease 2019 (COVID-19) pandemic: An Information Statement from ASNC and SNMMI. *J Nucl Cardiol*. 2020 Jun;27(3):1022-1029.
5. Gnanasegaran G, Huang HL, Williams J, Bomanji J. Coronavirus pandemic: what nuclear medicine departments should know. *J Nucl Med Technol*. 2020 Jun;48(2):89-97.