

Incidentally detected inguinal herniation of urinary bladder in whole body skeletal scintigraphy

GS Shagos, S Padma, P Shanmuga Sundaram

Department of Nuclear Medicine & PET/CT, Amrita Institute of Medical Sciences, Cochin, Kerala, India

(Received 11 November 2012, Revised 4 December 2012, Accepted 7 December 2012)

Iran J Nucl Med 2012;20(2):34-36

Corresponding author: Dr Shagos GS, Department of Nuclear Medicine & PET/CT, Amrita Institute of Medical Sciences, Cochin-6802041, Kerala, India. E-mail: shagosgs@aims.amrita.edu

INTRODUCTION

Herniation of urinary bladder is rare [1] and when present, it commonly involves either inguinal or femoral canal accounting for almost 1-3 % of all inguinal hernias [2]. Very often such hernias are asymptomatic and turns out to be an incidental finding in an imaging carried out for some other clinical indications [3]. Inguinal hernias may be direct or indirect. Indirect inguinal hernia protrudes through the inguinal region and is due to the failure of embryonic closure of the internal inguinal ring after the testicle passes through it. Direct inguinal hernia enters through a weak point in the fascia of abdominal wall (Hasselbachs triangle) [2]. Ischiorectal, obturator & abdominal wall, though rare, are the other sites through which urinary bladder can herniated [4]. Inguinal hernias of bladder are classified with regard to their relation to the peritoneum as: a) paraperitoneal hernias where bladder remains extraperitoneal & is medial to the peritoneal herniation. b) intraperitoneal hernia where bladder is completely covered with peritoneum in the hernial sac & c) extraperitoneal hernias where peritoneum remains in the abdomen & the bladder alone herniates [5].

CASE REPORT

72 yr old male who presented to the orthopaedics department with complaints of low back ache of a few months duration was referred for a skeletal scintigraphy to evaluate the cause of his back

ache. Whole body skeletal scintigraphy with ^{99m}Tc MDP was done after intravenous injection of 20 millicurie of ^{99m}Tc MDP. Whole body and other planar static images were acquired 03 hrs later. Whole body images showed an abnormal foci of increased tracer uptake in L5 vertebra (Fig. 1).

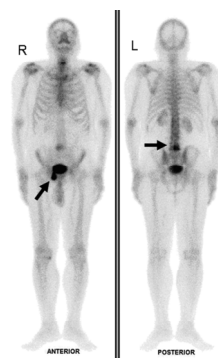

Fig 1. Whole body planar images taken 03 hrs after intravenous Technetium MDP administration showing increased tracer uptake in L5 vertebra. Another abnormal spot of increased MDP uptake is noted in the right pubic region which was initially thought to be due to local urinary contamination.

Another abnormal focus of increased MDP uptake was noted in the right pubic region that was initially thought to be due to local urinary contamination. Static post void images of the pelvis

acquired after thoroughly washing the local area showed persistence of this abnormal focus of MDP uptake which ruled out urinary contamination as the cause of this focal uptake. The pattern of uptake did not correspond to any bony landmark (Fig. 2).

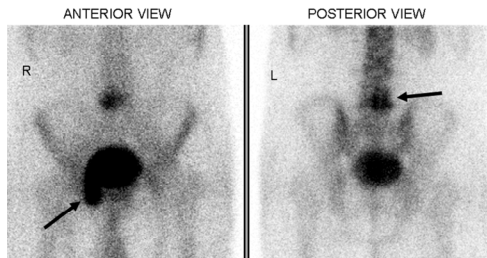


Fig 2. Static post void images of the pelvis after proper washing of the local area showing persistence of abnormal foci of MDP uptake in the pubic region. The pattern of uptake does not correspond to any bony landmark. The increased tracer uptake in the pubic region is seen to be in continuation with the urinary tracer activity in the bladder.

Continuity of this increased tracer uptake in the pubic region with the tracer activity in the bladder prompted us to carry out a SPECT-CT of the pelvis for final confirmation as to the cause of this abnormal MDP uptake. Fused SPECT-CT images of lower lumbar spine demonstrated osteophytes in L5 vertebra due to degenerative changes which was thereby assumed to be the cause for his continuing low back ache (Fig. 3).

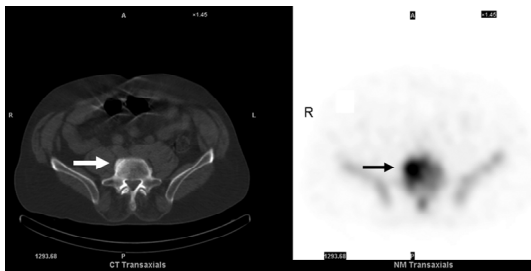


Fig 3. Fused SPECT-CT (axial images) of lower lumbar spine demonstrating osteophytes in L5 vertebra. (The required CT scan is a noncontrast, nondiagnostic, localizing CT with a tube current of 2Ma).

SPECT-CT confirmed that the focal Tc MDP uptake in the pubic region corresponds to the radioactive urine in the herniated urinary bladder in right inguinal canal. Interestingly, herniation of bowel

loops into the left inguinal canal could also be made out in the CT images (Fig. 4).

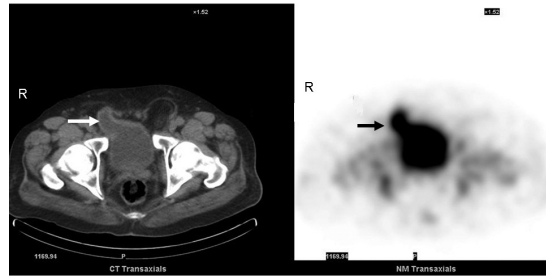


Fig 4. Fused SPECT-CT (axial images) confirms that the focal Tc MDP localization in pubic region corresponds to radioactive urine in the herniated urinary bladder in right inguinal canal. Herniation of bowel loops into the left inguinal canal can also be made out in the CT images.

DISCUSSION

Inguinal herniation of urinary bladder is rare. Often, it turns out to be an incidental finding in a radiological imaging carried out for the evaluation of some other clinical condition. Most of the bladder hernias are either inguinal or femoral, but a distended bladder can even herniate into the pelvis or into the abdominal cavity. Ilgan et al has described a rare case of massive inguinoscrotal herniation of bladder with ureter, causing urinary stasis which was incidentally detected in a bone scintigraphy [6]. Bladder outlet obstruction, intrapelvic mass, benign prostatic hypertrophy or any condition causing an increase in intra abdominal pressure can ultimately lead to herniation of the urinary bladder. Herniation of the urinary bladder may be quite asymptomatic, but some patients may even present with nonspecific symptoms like dysuria, increased frequency of micturition, poor urinary stream, intermittent voiding, nocturia or even as pain at the site of hernia. Stagnation of urine in the bladder in the hernia sac can even predispose to recurrent urinary tract infections. There are rare cases where bladder hernias presenting with renal failure has been reported [7,8]. Few cases of bladder hernias detected during routine nuclear medicine studies have been reported in the literature. Prompt differentiation of this entity is important in such clinical situations as these can mimic bone metastasis in a bone scan or in an FDG PET scan. Even though retrograde cystography is considered to be the best in diagnosing bladder hernias, excretory urography, CECT or even an ultrasound can aid in the diagnosis. In patients with inguinal herniation of bladder who are symptomatic, repair of the inguinal hernia with or without mesh placement is associated with good outcome [8].

Resection of the bladder is considered only in extreme conditions where necrosis is present or if there is a urothelial carcinoma within the herniated bladder [9,10]. In our patient, though initially the uptake in the pubic region was thought to be due to urinary contamination, SPECT-CT of the pelvis helped us to confirm that the uptake corresponds to radioactive urine in the herniated urinary bladder in right inguinal canal. In patients scheduled for repair of inguinal hernias, preoperative knowledge of the contents of hernial sac is vital before a surgical procedure [11] as it can help in preventing inadvertent cystectomy of the bladder ear in a herniated sac [12].

REFERENCES

1. Fisher PC, Hollenbeck BK, Montgomery JS, Underwood W 3rd. Inguinal bladder hernia masking bowel ischemia. *Urology*. 2004 Jan;63(1):175-6.
2. Curry NS. Hernias of the urinary tract. In: Pollack HM, McClennan BL. *Clinical urography*. 3rd ed. Philadelphia, PA: Saunders; 2000. p. 2981-91.
3. Yovchevski P, Kostov K. Acquired nonobstructive urinary bladder diverticulum: a case report. *Cases J*. 2009 Jan 9;2(1):36.
4. Bacigalupo LE, Bertolotto M, Barbiera F, Pavlica P, Lagalla R, Mucelli RS, Derchi LE. Imaging of urinary bladder hernias. *AJR Am J Roentgenol*. 2005 Feb;184(2):546-51.
5. Reardon JV, Lowman RM. Massive herniation of the bladder: "the roentgen findings". *J Urol*. 1967 Jun;97(6):1019-20.
6. Ilgan S, Ozguven M, Emer MO, Karacalioglu AO. Massive inguinoscrotal herniation of the bladder with ureter: incidental demonstration on bone scan. *Ann Nucl Med*. 2007 Aug;21(6):371-3.
7. Abaza R, Rashid MG, Sferra JJ. Obstructive uropathy from giant inguinal bladder and ureteral herniation. *J Am Coll Surg*. 2005 Aug;201(2):314.
8. Wagner AA, Arcand P, Bamberger MH. Acute renal failure resulting from huge inguinal bladder hernia. *Urology*. 2004 Jul;64(1):156-7.
9. Epner SL, Rozenblit A, Gentile R. Direct inguinal hernia containing bladder carcinoma: CT demonstration. *AJR Am J Roentgenol*. 1993 Jul;161(1):97-8.
10. Thompson JE Jr, Taylor JB, Nazarian N, Bennion RS. Massive inguinal scrotal bladder hernias: a review of the literature with 2 new cases. *J Urol*. 1986 Dec;136(6):1299-301.
11. Shepherd FJ. Hernia of the bladder complicating inguinal hernia. *Ann Surg*. 1904 Dec;40(6):921-8.
12. Aygen M, Akduman IE, Osman MM. Bladder Ear: Bladder ear: a potential source of false interpretation on F-18 FDG PET. *Clin Nucl Med*. 2008 Oct;33(10):721-2.