

A pictorial essay on brain perfusion SPECT in various neuro-psychiatric disorders and intoxication: Though practical, it is not very commonly used

Mina Taghizadeh Asl¹, Reza Nemati², Farzaneh Yousefi³,
Hooman Salimipour², Iraj Nabipour⁴, Majid Assadi³

¹Department of Nuclear Medicine, Kasra Hospital, Tehran, Iran

²Department of Neurology, Bushehr Medical University Hospital, Bushehr University of Medical Sciences, Bushehr, Iran

³The Persian Gulf Nuclear Medicine Research Center, The Persian Gulf Biomedical Sciences Institute, Bushehr University of Medical Sciences, Bushehr, Iran

⁴The Persian Gulf Marine Biotechnology Research center, The Persian Gulf Biomedical Sciences Institute, Bushehr University of Medical Sciences, Bushehr, Iran

(Received 14 April 2016, Revised 9 June 2016, Accepted 18 June 2016)

ABSTRACT

Brain single-photon emission computerized tomography (SPECT), in particular, with perfusion agents or with neuroreceptor imaging radiopharmaceuticals, is rapidly becoming a clinical tool in many neurologic and psychiatric conditions. This imaging modality has been used for diagnosis, prognosis assessment, evaluation of response to therapy, risk stratification, detection of benign vs. malignant viable tissue, and the choice of medical or surgical therapy. We will present our institutional experience in this area, formatting a pictorial review of brain perfusion SPECT on more than 20 types of different neurologic and psychiatric diseases, such as dementia, epilepsy, cerebral palsy, head injury, brain tumor, herpes encephalitis, hypoxic brain damage, vacuities, depression, carbon monoxide (CO) poisoning, and cocaine abuse. This is a demanding procedure as far as the need for trained and experienced physicians and personnel as well as advanced equipment are concerned. However, extraordinary useful clinical information achieved by this technology outweighs the existing challenge. More routine use of this procedure which is unfortunately underutilized in many countries including ours should be encouraged.

Key words: Brain perfusion SPECT; Neuro-psychiatric disorders; ^{99m}Tc-ethyl cysteinate dimer (ECD); ^{99m}Tc-hexamethylpropyleneamine oxime (HMPAO)

Iran J Nucl Med 2017;25(Suppl 1):1-14

Published: February, 2017

<http://irjnm.tums.ac.ir>

Corresponding author: Dr. Majid Assadi, The Persian Gulf Nuclear Medicine Research Center, Bushehr University of Medical Sciences, Bushehr 3631, Iran. E-mail: asadi@bpums.ac.ir

INTRODUCTION

Structural and functional images of the brain are powerful adjuncts in the management of an increasing number of neurologic and psychiatric diseases [1]. Brain SPECT, in particular, with perfusion agents or with neuroreceptor imaging radiopharmaceuticals, is rapidly becoming a clinical tool in many clinical situations [1]. For many neurologic and psychiatric conditions, this imaging modality has been used in diagnosis, prognosis assessment, the evaluation of response to therapy, risk stratification, the detection of benign or malignant viable tissue, and the choice of medical or surgical therapy. The radionuclide imaging is a useful technique for evaluation of neurologic and psychiatric diseases such as cerebrovascular disease, dementia, epilepsy, head injury, obsessive-compulsive disorder, Gilles de la Tourette syndrome, schizophrenia, depression, panic disorder, and drug abuse [1].

We review the usage of brain SPECT in different neurologic and psychiatric disorders.

Stroke

Brain SPECT has been used in acute ischemia, transient ischemic attacks (TIAs), stroke, the assessment of late ischemic injuries, the monitoring

of medical or surgical therapy, the assessment of cerebral blood flow (CBF) reserve, the estimation of prognosis, and the assessment of interventional sequelae (e.g., in arterial occlusion). Therefore, this imaging modality can be useful for rapidly diagnosing ischemia in order to prevent irreversible brain damage, identify viable tissue at risk, and screen patients who may benefit from medical and surgical interventions [1, 2].

The brain perfusion imaging agents ^{99m}Tc -HMPAO and ^{99m}Tc -ECD are sensitive indicators of regional cerebral blood flow (rCBF) changes and can detect a reduction in blood flow immediately after an acute event [1].

The cerebral hemodynamic status can be determined by measuring CBF before and after vasodilatory challenge, which can be done using either hypercapnia or acetazolamide. In acute occlusions resulting in cerebral ischemia, areas of hypoperfusion can be detected within minutes on SPECT scans. In the subacute phase of cerebral infarction, hypoperfusion may continue, although luxury perfusion may result in hyperperfusion. Chronic infarction is seen as a hypoperfused area on SPECT brain scans [2]. Resting CBF was not correlated with the degree of ICA stenosis; however, CVR was moderately correlated with the degree of ICA stenosis (Figure 1) [3].

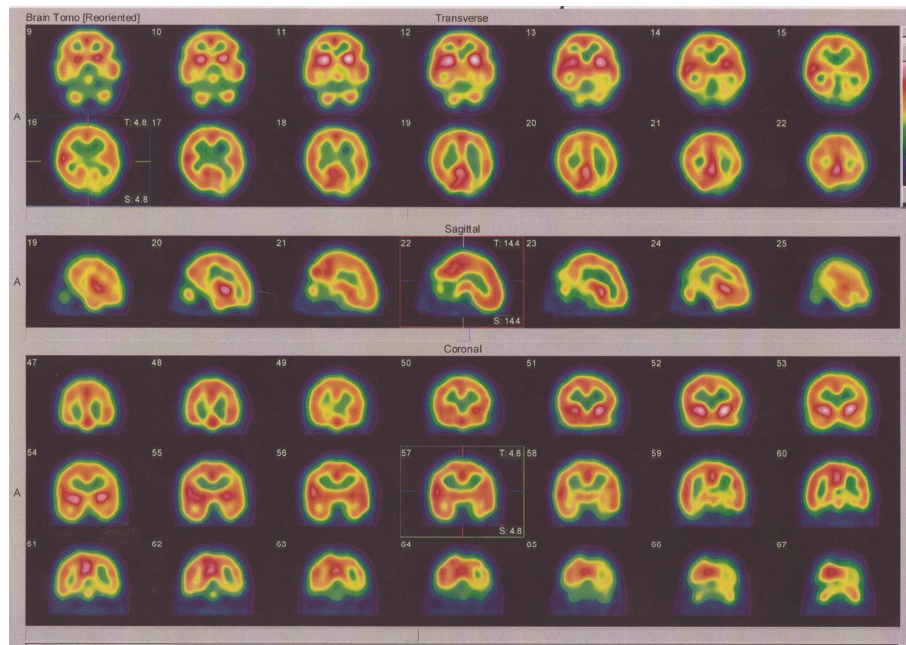


Fig 1. Brain perfusion ^{99m}Tc -ECD SPECT image of a 47-year-old man with a vascular insult demonstrated severe hypoperfusion of the left posterior cortex extending to the visual cortex on the left side. In addition, severe hypoperfusion is found in the posterior, temporal, and occipital regions and in the cerebellum bilaterally, suggesting a vascular insult involving the territory of the basilar arteries and left middle cerebral artery.

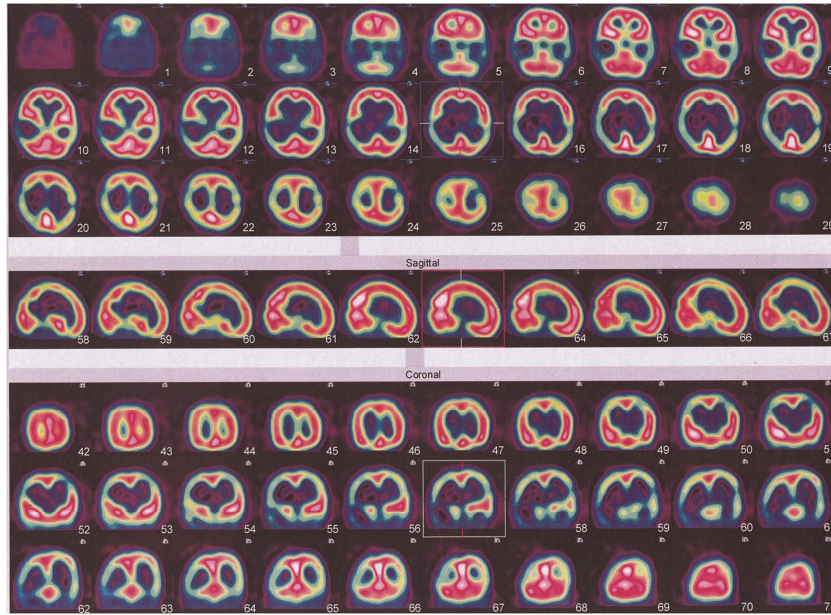


Fig 2. Brain perfusion ^{99m}Tc -ECD SPECT image of an 11-year-old patient with complex partial seizures showed diffuse cortical hypoperfusion especially in the parietal and temporal lobes bilaterally. Marked cortical thinning and central zone widening is representing enlarged lateral ventricles and cortical atrophic changes.

Epilepsy

Ictal perfusion SPECT imaging with ^{99m}Tc -ethyl cysteinate dimer (ECD) or ^{99m}Tc -hexamethylpropyleneamine oxime (HMPAO) enables one to detect the seizure onset zone in a majority of cases, especially in patients with temporal lobe epilepsy. Interictal SPECT imaging, which is more widely available, is unreliable for determining the ictal onset zone and is typically used only for comparison with ictal SPECT images [4].

Ictal SPECT has a poor time resolution. After injection of the tracer, it takes about 30s to reach the brain, and about 70% of the radioligand is taken up during the first pass. An ictal perfusion SPECT image displays both the ictal onset zone and seizure propagation pathways. The region with the largest and most intense hyperperfusion is considered the ictal onset zone. It has been shown that these regions may also represent ictal propagation focus. The rationale for interictal SPECT imaging is to serve as a baseline reference study for the interpretation of ictal SPECT images [1].

However, in approximately 50% of patients with epilepsy, the findings in the interictal period are normal (Figure 2) [1, 5].

Dementia

SPECT can play an important role in the initial diagnosis of dementia and in the differential

diagnosis of the specific dementing disorder. It is also helpful in distinguishing Alzheimer's dementia (AD) from age-matched controls, from frontal lobe dementia (FTD) and vascular dementia (VD), and even from Lewy body dementia [LBD] [6].

Lewy body dementia (LBD)

Dementia with Lewy bodies (DLB), or Lewy body disease, is a neurodegenerative disease associated to the Parkinson's disease (PD) [6]. It accounts as the second most frequent type of neurodegenerative dementia following Alzheimer's disease (AD), about 15-20% of cases at autopsy [6]. Typically presenting with a frontal-type dementia with a bit in the way of memory deficits early in the course of the disease. The main features include fluctuating cognitive destruction particularly in executive function, attention and alertness; visuospatial destruction such as visual hallucinations ; simultaneous parkinsonian symptoms may exist, but is less frequent, more seen years after the onset of dementia. In delayed phases, quadriplegia and/or apallic syndrome may be seen [7].

Functional neuroimaging with the use of CBF SPECT may contribute to the clinical diagnosis of DLB. In four cases, rCBF SPECT images showed bilateral hypoperfusion of the temporal, parietal, and occipital lobes. In two other cases, parietal deficits were observed (Figure 3) [7].

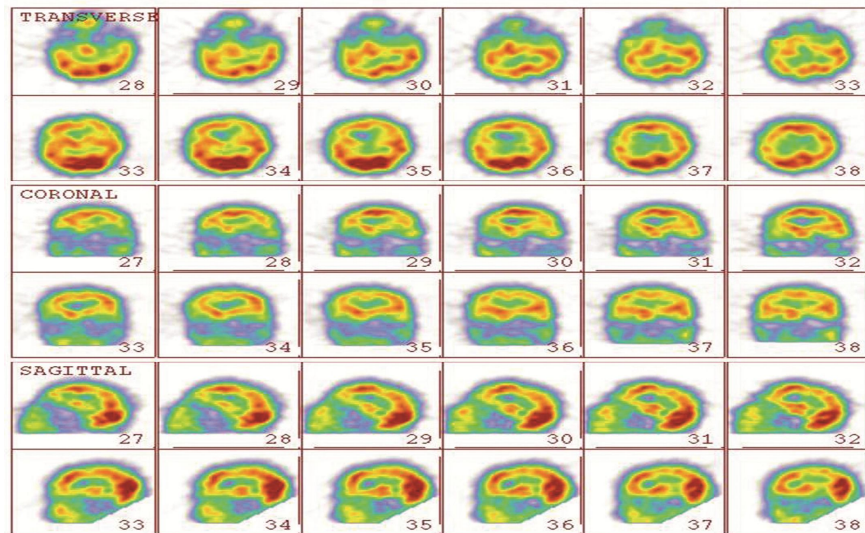


Fig 3. Brain perfusion ^{99m}Tc -ECD SPECT image of a 58-year-old man with LBD depicted decreased radiotracer uptake in both hemispheres.

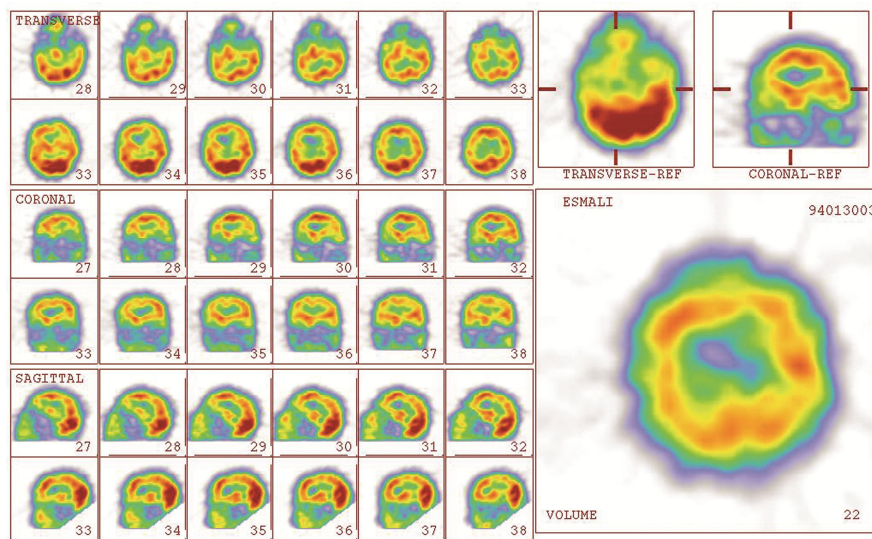


Fig 4. Brain perfusion ^{99m}Tc -ECD SPECT image of a 54-year-old man with MCI showed hypoperfusion in the bilateral parietal lobes.

Mild cognitive impairment (MCI)

MCI is a condition referring to people with significant memory impairment, often accompanied by functional deficits in the attention, language, visuospatial, and psychomotor domains, who do not fulfill the criteria for dementia. Individuals with MCI are at an increased risk of developing dementia, classified as amnesic MCI (aMCI) and non-amnesic MCI [naMCI] [8].

In the naMCI group, reduced volumetric regions of interest (VROI) values were found in the bilateral temporal cortex and right frontal cortex. In the comparison between aMCI and naMCI, the former

had lower values in the left parietal cortex as well as precuneus (Figure 4) [9].

Alzheimer's dementia (AD)

Alzheimer disease is the most frequent type of dementia, and accounts for two thirds of patients of dementia in individuals aged 60-70 years. Its prevalence is highly associated to age, with >1% of 60-64 year old cases being diagnosed with the disease, compared to 20-40% of people over 85-90 years of age. The patients with Alzheimer disease typically present initially with antegrade episodic

memory impairments. Over time the disease develops with eventual involvement of attentional and executive functions, semantic memory, praxis and visuoperceptual capabilities [10]. This is at least partly consistent with previous studies, which showed parietotemporal deficits to be characteristic findings of AD. Significantly decreased rCBF was found in the frontal, parietal, and temporal regions in the patient group, more marked in those patients with severe dementia. Bilateral parietotemporal deficits of

CBF, along with a definite decrease in blood flow in the frontal region, were established in patients with Alzheimer's disease compared with normal controls (Figure 5) [10].

Frontal lobe dementia (FTD)

SPECT demonstrated frontal and temporal hypoperfusion with relative sparing of parietal and occipital blood flow (Figure 6) [11].

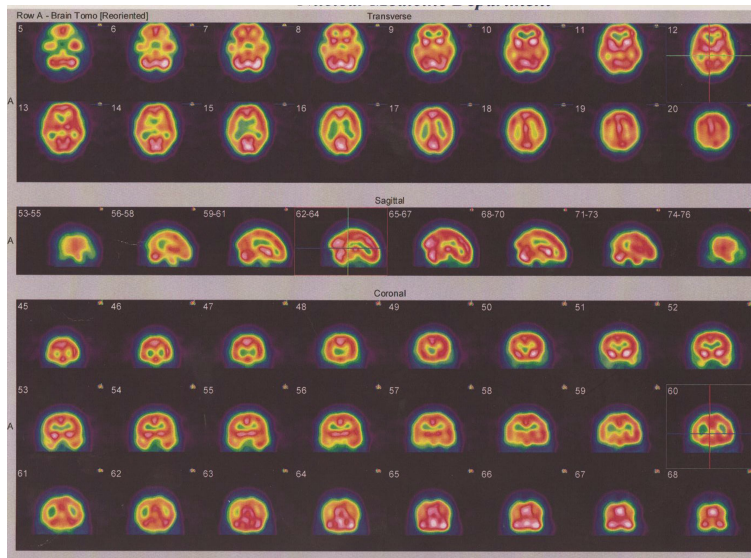


Fig 5. Brain perfusion ^{99m}Tc -ECD brain perfusion SPECT image of a 70-year-old woman with AD showed the bilateral parietal and temporal lobes.

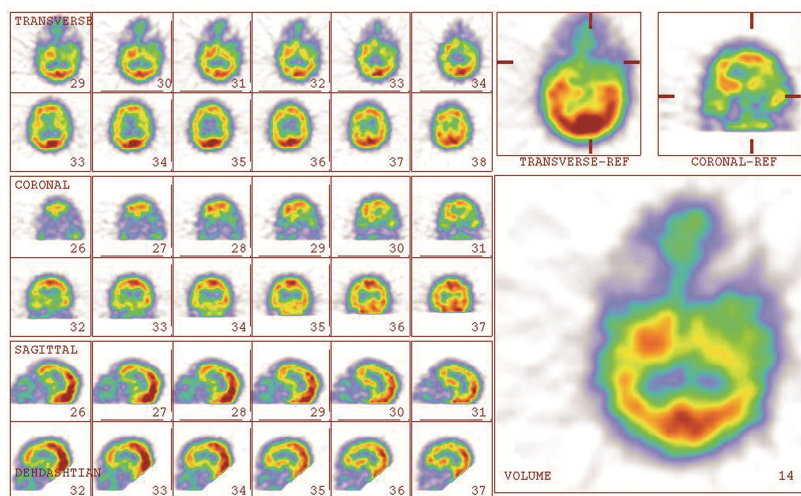


Fig 6. Brain perfusion ^{99m}Tc -ECD SPECT image of a 75-year-old woman with AD with FTD showed bilateral frontal temporal hypoperfusion.

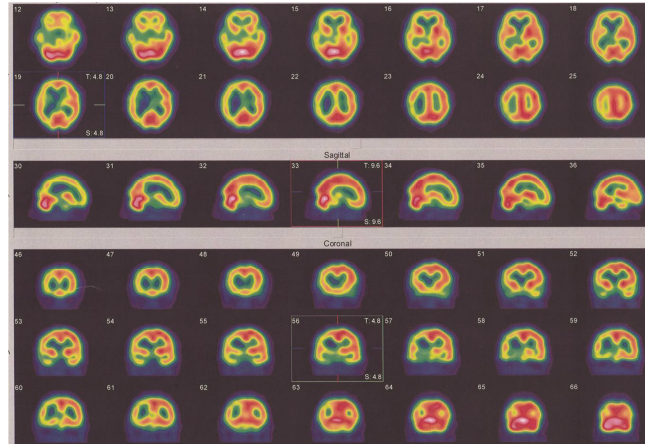


Fig 7. Brain perfusion ^{99m}Tc -ECD SPECT image of a 70-year-old woman with VD showed moderate to severe hypoperfusion parietal and temporal lobes.

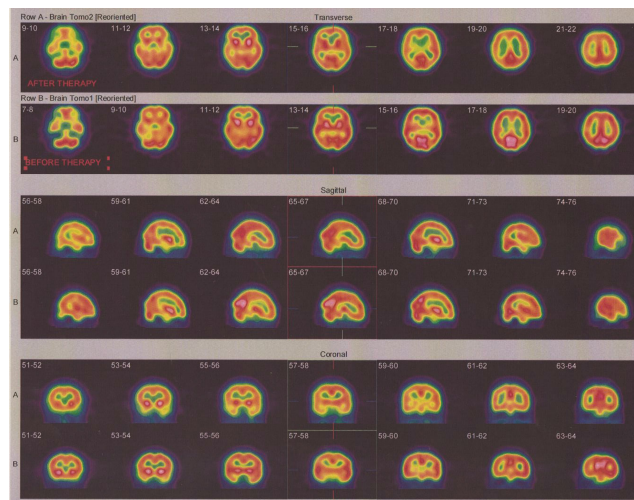


Fig 8. Brain perfusion ^{99m}Tc -ECD SPECT image of a 58-year-old woman with secondary progressive MS since 14 years ago and EDSS 5 moderate decrease perfusion on the right temporal cortex.

Vascular dementia (VD)

Brain SPECT in these patients showed multiple focal areas of hypoperfusion randomly distributed. Again, correlation with anatomic images such as those from CT or magnetic resonance imaging (MRI) is important: Cortical or subcortical infarcts are usually found on CT, and this finding increases the likelihood of the disease. Subcortical infarcts alone, without cortical lesions on CT, can explain nearby cortical perfusion defects via disconnection between cortical and subcortical neurons [1].

The Binswanger type of dementia, a rare variant of VD, is a gradually progressive syndrome caused by diffuse or patchy ischemic events affecting the deep white matter. In neuroimaging studies, in mild type, subcortical leuco-araiosis was localized at the frontal region but scattered diffusely in the severe types.

These results suggest that patients with VDBT have early frontal lobe involvement with posterior progression. Patients with mild VDBT are more likely to show a reduction of frontal CBF, while those with severe VDBT are more likely to have diffuse cerebral hypoperfusion (Figure 7) [12].

Inflammatory cerebral disease

Multiple sclerosis (MS)

Lycke et al. evaluated CBF of an MS patient via brain SPECT and showed CBF to be significantly reduced, particularly in progressive type [13].

In two studies, cerebral perfusion in early stage of MS disease without or with mild disability was normal while in patients with more advanced stage of the disease was abnormal (Figure 8) [14, 15].

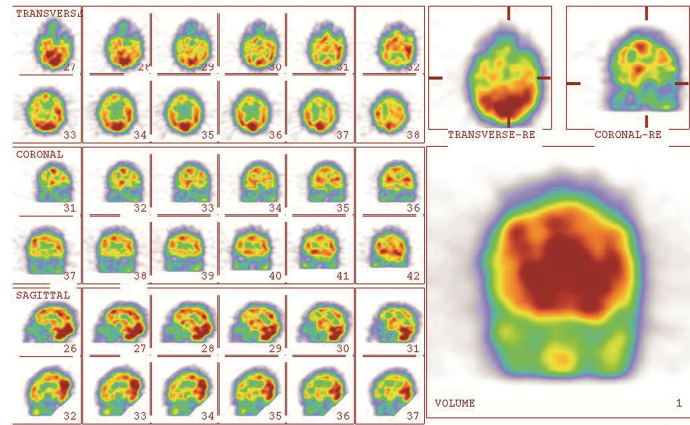


Fig 9. Brain perfusion ^{99m}Tc -ECD SPECT image of a 35-year-old woman with SLE showed hypoperfusion in both hemispheres.

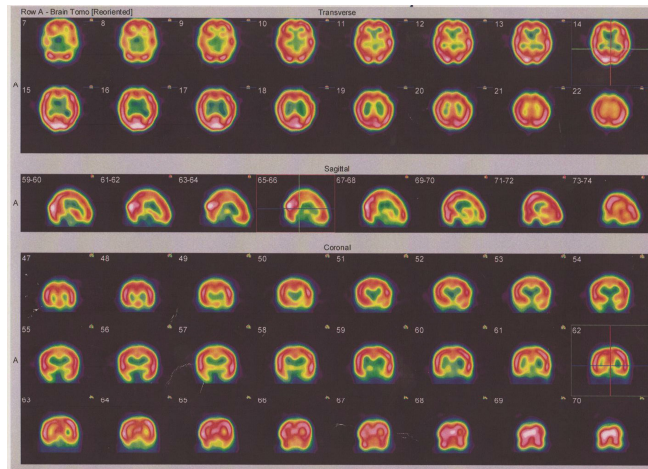


Fig 10. Brain perfusion ^{99m}Tc -ECD SPECT image of a 5-year-old girl with ADHD demonstrated moderate frontal hypo perfusion and bilateral inferior temporal hypoperfusion.

Vasculitis

Several studies have revealed a hypoperfusion area in brain SPECT of connective tissue disease with neurologic manifestation, such as systemic lupus erythematosus, Behcet disease, Sjogren syndrome, and antiphospholipid syndrome [14].

Brain SPECT abnormality was detected in 91% of systemic lupus erythematosus patients, while MRI was abnormal in only 26%. Lass et al. showed the diffuse hypoperfusion of both frontal lobes when compared to HMPAO cerebellar uptake and healthy control subject indices in 30% of systemic lupus erythematosus, 50% of Sjogren's syndrome, and none of the diffuse scleroderma patients (Figure 9) [16].

Acute disseminated encephalomyelitis (ADEM)

SPECT brain perfusion in an ADEM case showed scattered areas of increased and decreased activity in

different areas of the white matter. The increased uptake of HMPAO may represent blood-brain barrier damage and the presence of inflammatory cells and hyperemia. Decreased flow, particularly in the cortical regions, may also reflect cortical deactivation secondary to disconnection from subcortical structures [17].

Attention deficit hyperactivity disorder (ADHD)

Langleben et al. evaluated patients with ADHD who had been free of other comorbid conditions. Their research showed reduced right dorsolateral prefrontal cortical (DLPFC) perfusion and increased left DLPFC perfusion in patients with severe and moderate ADHD (Figure 10) [18].

Depression

Frontal lobe hypometabolism is emerging as a common final pathway for most types of primary and

secondary depression, regardless of the original cause. The severity of depression is often related to the degree of frontal hypometabolism, and preliminary studies indicate that the hypometabolism normalizes after treatment in concert with the patient's improved mood [19]. Our study suggests that adolescent patients with major depressive disorder may have asymmetric regional CBF deficits in frontal regions compared with normal subjects (Figure 11) [20].

Obsessive compulsive disorder (OCD)

Quantitative evaluation of regional CBF revealed that the right thalamus, left frontotemporal cortex, and bilateral orbitofrontal cortex showed significant hyperperfusion in patients with OCD compared with controls. Results of this cross-cultural study may support orbitofrontal and thalamic dysfunction in OCD in a sample of Turkish patients [21].

Carbon monoxide (CO) poisoning

^{99m}Tc -HMPAO SPECT imaging is a useful tool for detecting functional brain injury in acute CO poisoning. Basal ganglia is predominant anatomical site involved, followed by the temporal lobe, parietal lobe, frontal lobe, occipital lobe, and thalamus [22].

A good correlation seems to exist between the findings of brain SPECT and the outcome of delayed CO sequelae, and brain perfusion scan may be a useful test for evaluating the clinical outcome of delayed neurologic sequelae after CO poisoning. After the acute phase of CO poisoning, brain SPECT in patients suffering from neurologic sequel showed diffuse patchy hypoperfusion throughout the cerebral cortex, which in the following SPECT study, showed increased cerebral perfusion, concomitant with clinical improvement (Figure 12) [23].

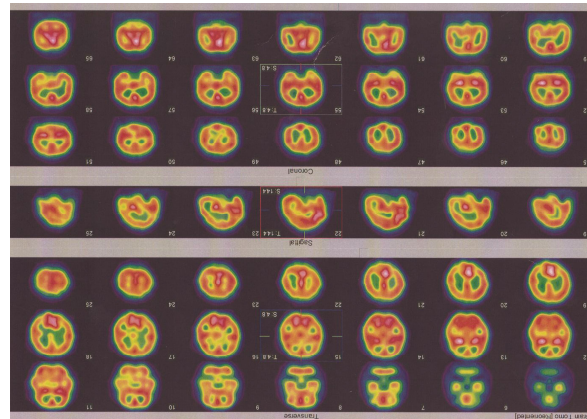


Fig 11. Brain perfusion ^{99m}Tc -ECD SPECT image of a 23-year-old woman with major depression disorder demonstrated bilateral frontal hypoperfusion.

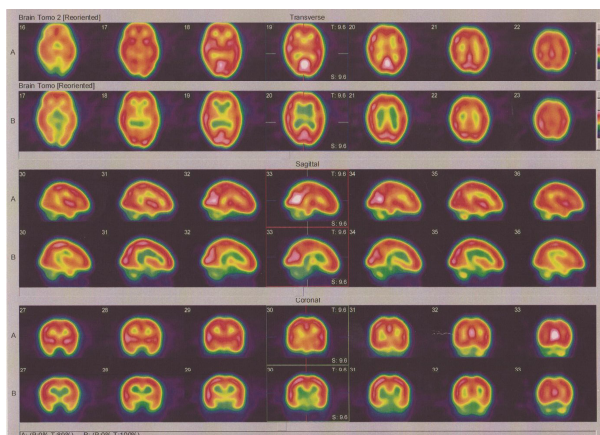


Fig 12. Brain perfusion ^{99m}Tc -ECD SPECT image of a 3-year-old boy with CO poisoning showed bilateral occipital hypoperfusion in the acute phase of CO exposure; follow-up scan showed normal perfusion after three months.

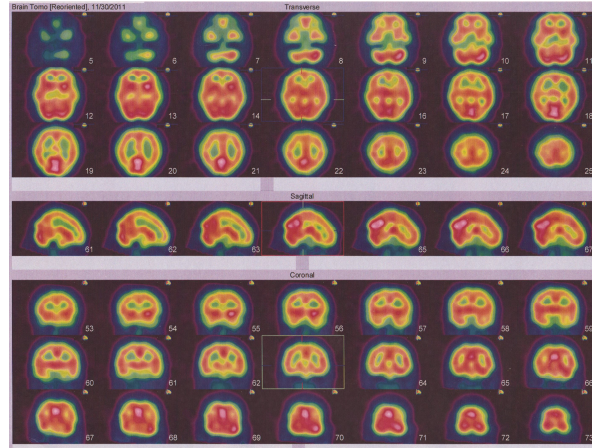


Fig 13. Brain perfusion ^{99m}Tc -ECD SPECT image of a 26-year-old man with acute confusion following cocaine inhalation demonstrated diffusely decreased cerebral blood flow of frontal lobes bilaterally.

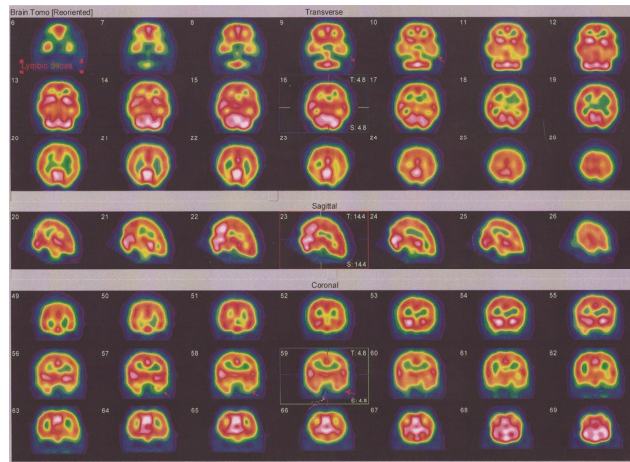


Fig 14. Brain perfusion ^{99m}Tc -ECD SPECT image of a 54-year-old man with a known case of PTSD following blast injury showed hyperperfusion in the left inferior temporal region.

Cocaine addiction

Brain SPECT, similar to positron emission tomography (PET), has shown disseminated CBF defects in abusers of cocaine, crack, and alcohol. The disappearance or improvement of the lesions after a period of abstinence has been described, suggesting that arterial spasms may cause the defects [1].

Adinoff et al. in 2003 showed decreased CBF in the left dorsolateral prefrontal cortex in the cocaine-dependent subjects compared to the comparison subjects [24].

Holman et al. reported that 16 of 18 patients with cocaine-dependent and poly-drug addiction had abnormal perfusion characterized primarily as small focal defects involving the inferoparietal, temporal,

and anterofrontal cortices and basal ganglia (Figure 13) [25].

Posttraumatic stress disorder (PTSD)

Peskind et al. evaluated 12 Iraq war veterans, who suffered from blast head injury and met the American College of Rehabilitation Medicine criteria for mild traumatic brain injury (mTBI) and post-concussion syndrome (PCS), and 12 cognitively normal community volunteers. They were evaluated via brain fluorodeoxyglucose positron emission tomography (FDG-PET), and compared to the controls, the veterans with mTBI (with or without PTSD) showed consistent regional hypometabolism in the infratentorial (cerebellum, vermis, and pons) and medial temporal brain regions (Figure 14) [26].

Cerebral palsy (CP)

Denays et al. studied brain SPECT in children with cerebral palsy and reported normal findings in the children with mild diplegic CP; bilateral hypoperfusion of the superior motor cortex in children with moderately severe diplegia or tetraplegia; and bilateral reduction of the perfusion of the superior motor, inferior motor, prefrontal, and parietal cortices in children with moderately severe diplegia or tetraplegia. They used the cerebellum as a

reference structure (Figure 15) [27]. Decreased cerebral perfusion in different types of CP patients was also seen in our prior study [28].

Herpes encephalitis

Rieck et al. showed increased uptake of ^{99m}Tc -HMPAO in the affected temporal lobes and adjacent paramedian structures in patients with acute herpes encephalitis (Figure 16) [29, 30].

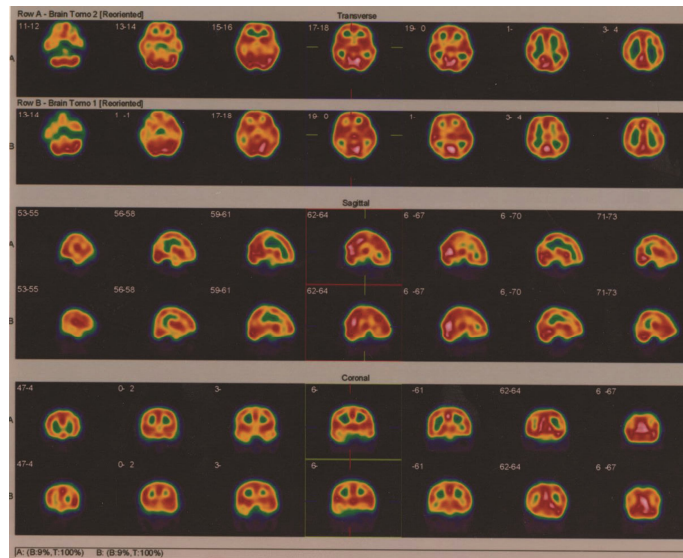


Fig 15. Brain perfusion ^{99m}Tc -ECD SPECT image of a 27-year-old man with a mild spastic quadriplegia type of cerebral palsy following perinatal asphyxia demonstrated moderate decrease perfusion of the right visual cortex with extension to the subcortical structure and moderate bilateral subcortical hypoperfusion.

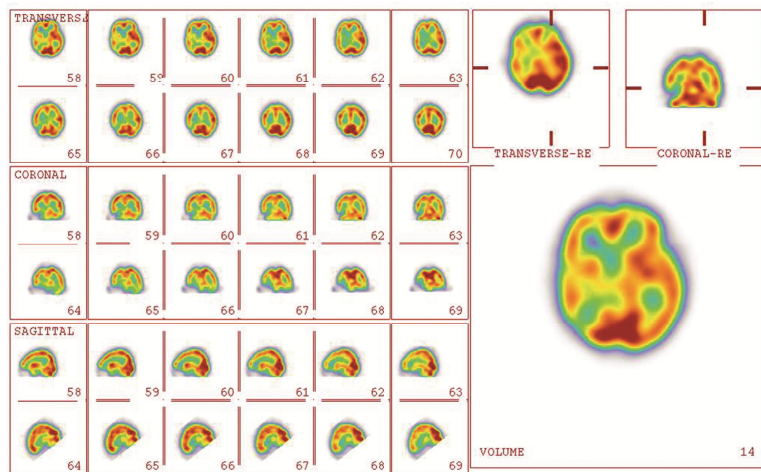


Fig 16. Brain perfusion ^{99m}Tc -ECD SPECT image of an 8-year-old boy with behavioral disorder following herpes encephalitis of the right temporal lobe demonstrated severe decrease right temporal lobe perfusion with extension to the visual cortex, parietal, and putamen.

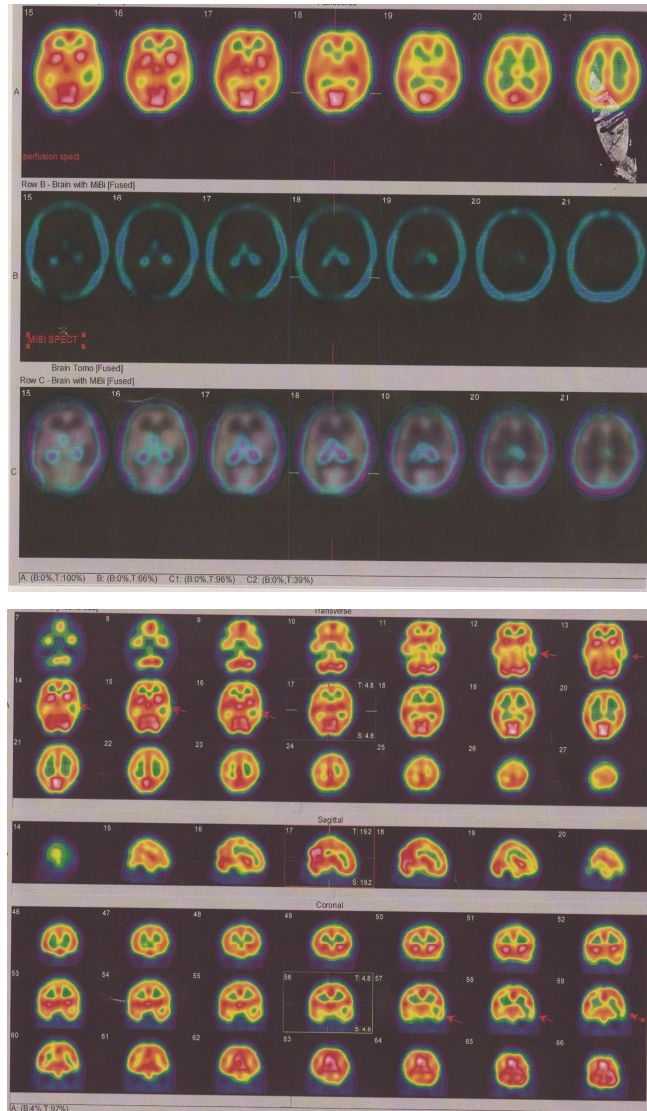


Fig 17. Brain perfusion ^{99m}Tc -ECD SPECT image of a 48-year-old man with brain tumor showed moderately hypoperfusion in the left temporal lobe without any evidence of ^{99m}Tc -MIBI uptake. Mild hypoperfusion in the right cerebellum is suggestive of crossed cerebellar diaschisis (CCD). The upper row indicates ^{99m}Tc -ECD, the middle row indicates ^{99m}Tc -MIBI, and the lower row is a fusion of both of the above agents.

Brain tumor

Brain SPECT is useful in the differentiation of tumor recurrence from radiation necrosis, in the non-invasive assessment of glioma and meningioma aggressiveness, in differentiating neoplastic from non-neoplastic intracerebral hemorrhage, in monitoring therapy response, and in the evaluation of other types of brain tumors [31].

^{201}Tl l, ^{99m}Tc -sestamibi, and ^{99m}Tc -tetrofosmin are the radiopharmaceuticals used for the functional imaging of brain tumors with a gamma camera [32].

Functional imaging methods can differentiate glioma tissue from brain tissue based on the higher metabolic

activity of glioma cells. Radiopharmaceutical technetium-99m-methoxyisobutylisonitrile (^{99m}Tc -MIBI) passively diffuses through the cell membrane, and its highest proportion is found in mitochondria. Brain SPECT was shown to be effective in differentiating viable glioma tissue from radiation necrosis and the surrounding edema. Moreover, higher tracer uptake on a SPECT scan was shown to be associated with higher-grade gliomas, decreased survival, and worse response to chemotherapy. The comparison of perfusion study using ^{99m}Tc -HMPAO or ^{99m}Tc -ECD with ^{99m}Tc -MIBI uptake is helpful in brain tumor assessment (Figure 17) [33].

Trauma

Brain damage inflicted by head trauma may not be visible on CT or MRI. This is true not only for mild head trauma but also for moderate and severe head trauma. Perfusion imaging with SPECT has proved to be more sensitive than either CT or MRI in detecting brain abnormalities in patients with head trauma [34].

Additionally, cerebral perfusion abnormalities can persist even in the chronic stages of TBI. On the basis of these results, some investigators suggest that these functional imaging techniques may explain or predict post-injury neuropsychologic and cognitive deficits

that are not explained by anatomic abnormalities detected by MRI or CT. Furthermore, focal lesions demonstrated by SPECT offer objective evidence of organic injury in patients whose neuroimaging studies are otherwise normal (Figure 18) [35-37].

Hypoxic brain damage

SPECT study with perfusion agents appears to be a helpful adjunct for the evaluation and clinical diagnosis of such patients (Figure 19) [38].

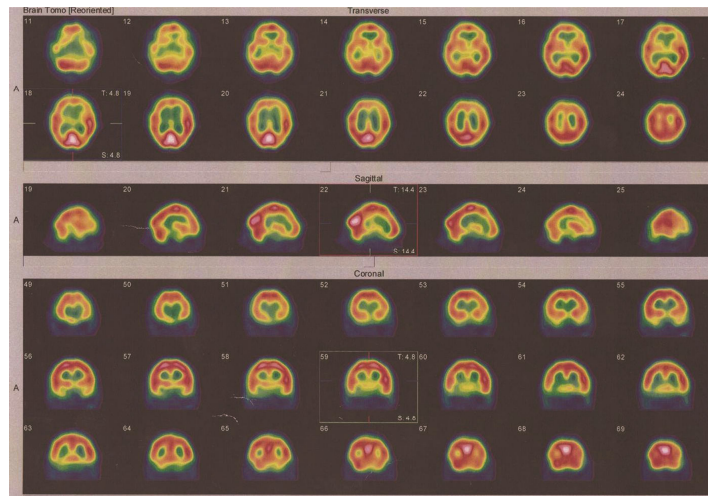


Fig 18. Brain perfusion ^{99m}Tc -ECD SPECT image of a 47-year-old man with head trauma demonstrated diffusely decrease bilateral frontal, parietal, occipital, and temporal cortical and subcortical perfusion.

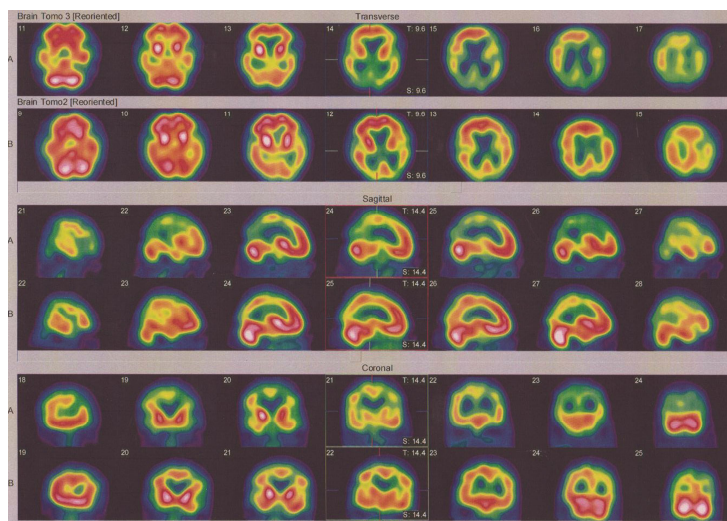


Fig 19. Brain perfusion ^{99m}Tc -ECD SPECT image of a 56-year-old man following cardiac arrest demonstrated hypoperfusion in both hemispheres.

CONCLUSION

Brain perfusion SPECT increased diagnostic yields for diagnosis of various neuro-psychiatric disorders. Challenges such as need for practitioner training, learning curve influenced by a specific patient-subset, relatively long procedure (60-90 min) and post-processing time, logistics of sharing SPECT images with MRI, poor initial acceptance by Colleagues in neuropsychiatry and neurosurgery, and also financial issues especially in resource-limited, developing nation environments are evidently exist. It is necessary to encourage programs in which brain SPECT to become an important component of the routine clinical assessment of patients with neurological and psychiatric diseases especially in developing nations should be admired and supported as a distinct discipline.

Ethical standards statement

The study was performed in accordance with the Declaration of Helsinki, and was approved by our institutional ethics committee (Bushehr University of Medical Sciences). Informed consent was obtained from all patients or their caregivers for being included in the study.

Acknowledgments

We sincerely thank the patients and their caregivers in addition to the researchers and their teams who contributed to this investigation.

REFERENCES

- Camargo EE. Brain SPECT in neurology and psychiatry. *J Nucl Med*. 2001 Apr;42(4):611-23.
- Ozgun HT, Kent Walsh T, Masaryk A, Seeger JF, Williams W, Krupinski E, Melgar M, Labadie E. Correlation of cerebrovascular reserve as measured by acetazolamide-challenged SPECT with angiographic flow patterns and intra- or extracranial arterial stenosis. *AJNR Am J Neuroradiol*. 2001 May;22(5):928-36.
- Tomura N, Otani T, Koga M, Ishiyama K. Correlation between severity of carotid stenosis and vascular reserve measured by acetazolamide brain perfusion single photon emission computed tomography. *J Stroke Cerebrovasc Dis*. 2013 Feb;22(2):166-70.
- Goffin K, Dedeurwaerdere S, Van Laere K, Van Paesschen W. Neuronuclear assessment of patients with epilepsy. *Semin Nucl Med*. 2008 Jul;38(4):227-39.
- Nemati R, Nabipour I, Javadi H, Chabi N, Assadi M. Regional Cerebral Blood-Flow with 99mTc-ECD Brain Perfusion SPECT in Landau-Kleffner Syndrome: Report of Two Cases. *Case Rep Radiol*. 2014;2014:617343.
- Devous MD Sr. Functional brain imaging in the dementias: role in early detection, differential diagnosis, and longitudinal studies. *Eur J Nucl Med Mol Imaging*. 2002 Dec;29(12):1685-96.
- Brockhuis B, Slawek J, Wieczorek D, Ussorowska D, Derejko M, Romanowicz G, Marks W, Dubaniewicz M. Cerebral blood flow changes in patients with dementia with Lewy bodies (DLB). A study of 6 cases. *Nucl Med Rev Cent East Eur*. 2006;9(2):114-8.
- Gabryelewicz T, Pawłowska-Detko A, Miško J, Cwikła JB, Pfeiffer A, Barczak A, Wasiak B, Łuczynkiewicz E, Królicki L, Walecki J, Barcikowska M. Prediction of deterioration of mild cognitive impairment with CT and SPECT. *Med Sci Monit*. 2007 May;13 Suppl 1:31-7.
- Nobili F, Frisoni GB, Portet F, Verhey F, Rodríguez G, Caroli A, Touchon J, Calvini P, Morbelli S, De Carli F, Guerra UP, Van de Pol LA, Visser PJ. Brain SPECT in subtypes of mild cognitive impairment. Findings from the DESCRIPA multicenter study. *J Neurol*. 2008 Sep;255(9):1344-53.
- Imran MB, Kawashima R, Awata S, Sato K, Kinomura S, Ono S, Sato M, Fukuda H. Tc-99m HMPAO SPECT in the evaluation of Alzheimer's disease: correlation between neuropsychiatric evaluation and CBF images. *J Neurol Neurosurg Psychiatry*. 1999 Feb;66(2):228-32.
- Miller BL, Cummings JL, Villanueva-Meyer J, Boone K, Mehinger CM, Lesser IM, Mena I. Frontal lobe degeneration: clinical, neuropsychological, and SPECT characteristics. *Neurology*. 1991 Sep;41(9):1374-82.
- Shyu WC, Lin JC, Shen CC, Hsu YD, Lee CC, Shiah IS, Tsao WL. Vascular dementia of Binswanger's type: clinical, neuroradiological and 99mTc-HMPAO SPECT study. *Eur J Nucl Med*. 1996 Oct;23(10):1338-44.
- Lycke J, Wikkelsö C, Bergh AC, Jacobsson L, Andersen O. Regional cerebral blood flow in multiple sclerosis measured by single photon emission tomography with technetium-99m hexamethylpropyleneamine oxime. *Eur Neurol*. 1993;33(2):163-7.
- Assadi M, Salimipour H, Seyedabadi M, Saberifard J, Javadi H, Nabipour I, Nemati R. Brain single photon emission computed tomography with Tc-99m MIBI or Tc-99m ECD in comparison to MRI in multiple sclerosis. *Clin Nucl Med*. 2010 Sep;35(9):682-6.
- Taghizadeh Asl M, Nemati R, Chabi N, Salimipour H, Nabipour I, Assadi M. Brain perfusion imaging with voxel-based analysis in secondary progressive multiple sclerosis patients with a moderate to severe stage of disease: a boon for the workforce. *BMC Neurol*. 2016 May 26;16:79.
- Lass P, Koseda M, Lyczak P. Technetium-99m-HMPAO brain SPECT in systemic lupus erythematosus with central nervous system involvement. *J Nucl Med*. 1998 May;39(5):930-1.
- Broich K, Horwich D, Alavi A. HMPAO-SPECT and MRI in acute disseminated encephalomyelitis. *J Nucl Med*. 1991 Oct;32(10):1897-900.
- Langleben DD, Austin G, Krikorian G, Riddlehuber HW, Goris ML, Strauss HW. Interhemispheric asymmetry of regional cerebral blood flow in prepubescent boys with attention deficit hyperactivity disorder. *Nucl Med Commun*. 2001 Dec;22(12):1333-40.
- George MS, Ketter TA, Post RM. SPECT and PET imaging in mood disorders. *J Clin Psychiatry*. 1993 Nov;54 Suppl:6-13.
- Tutus A, Kibar M, Sofuoglu S, Basturk M, Gönül AS. A technetium-99m hexamethylpropylene amine oxime brain single-photon emission tomography study in adolescent

- patients with major depressive disorder. *Eur J Nucl Med.* 1998 Jun;25(6):601-6.
21. Alptekin K, Degirmenci B, Kivircik B, Durak H, Yemez B, Derebek E, Tunca Z. Tc-99m HMPAO brain perfusion SPECT in drug-free obsessive-compulsive patients without depression. *Psychiatry Res.* 2001 Jul 1;107(1):51-6.
 22. Lu YY, Tsai SC, Kao CH, Lin WY. Regional cerebral blood flow in patients with carbon monoxide intoxication. *Ann Nucl Med.* 2012 Dec;26(10):771-6.
 23. Choi IS, Kim SK, Lee SS, Choi YC. Evaluation of outcome of delayed neurologic sequelae after carbon monoxide poisoning by technetium-99m hexamethylpropylene amine oxime brain single photon emission computed tomography. *Eur Neurol.* 1995;35(3):137-42.
 24. Adinoff B, Devous MD, Best SE, Harris TS, Chandler P, Frock SD, Williams MJ. Regional cerebral blood flow in female cocaine-addicted subjects following limbic activation. *Drug Alcohol Depend.* 2003 Sep 10;71(3):255-68.
 25. Holman BL, Carvalho PA, Mendelson J, Teoh SK, Nardin R, Hallgring E, Hebben N, Johnson KA. Brain perfusion is abnormal in cocaine-dependent polydrug users: a study using technetium-99m-HMPAO and ASPECT. *J Nucl Med.* 1991 Jun;32(6):1206-10.
 26. Peskind ER, Petrie EC, Cross DJ, Pagulayan K, McCraw K, Hoff D, Hart K, Yu CE, Raskind MA, Cook DG, Minoshima S. Cerebrocerebellar hypometabolism associated with repetitive blast exposure mild traumatic brain injury in 12 Iraq war Veterans with persistent post-concussive symptoms. *Neuroimage.* 2011 Jan;54 Suppl 1:S76-82.
 27. Denays R, Tondeur M, Toppet V, Ham H, Piepsz A, Spehl M, Rubinstein M, Noel P. Cerebral palsy: initial experience with Tc-99m HMPAO SPECT of the brain. *Radiology.* 1990 Apr;175(1):111-6.
 28. Asl MT, Yousefi F, Nemati R, Assadi M. 99mTc-ECD brain perfusion SPECT imaging for the assessment of brain perfusion in cerebral palsy (CP) patients with evaluation of the effect of hyperbaric oxygen therapy. *Int J Clin Exp Med.* 2015 Jan 15;8(1):1101-7.
 29. Rieck H, Adelwöhrer C, Lungenschmid K, Deisenhammer E. Discordance of technetium-99m-HMPAO and technetium-99m-ECD SPECT in herpes simplex encephalitis. *J Nucl Med.* 1998 Sep;39(9):1508-10.
 30. Launes J, Nikkinen P, Lindroth L, Brownell AL, Liewendahl K, Iivanainen M. Diagnosis of acute herpes simplex encephalitis by brain perfusion single photon emission computed tomography. *Lancet.* 1988 May 28;1(8596):1188-91.
 31. Alexiou G, Tsiouris S, Fotopoulos A. Single-photon emission computed tomography in the evaluation of brain tumors and the diagnosis of relapse vs radiation necrosis. *Hell J Nucl Med.* 2007 Sep-Dec;10(3):205-8.
 32. Birbilis T, Boussios N, Papatheodossiou L, Matis G, Zissimopoulos A. Is there a role for SPECT with (99m)Tc-Tetrofosmin in the diagnostic work up of a brain tumor? *Maedica (Buchar).* 2013 Sep;8(4):347-50.
 33. Shih WJ, Lee JK, Milan P. Discordant technetium-99m-MIBI and technetium-99m-HMPAO uptake of recurrent occipital meningioma on brain SPECT images. *J Nucl Med.* 1996 Jul;37(7):1183-5.
 34. Masdeu JC, Abdel-Dayem H, Van Heertum RL. Head trauma: use of SPECT. *J Neuroimaging.* 1995 Jul;5 Suppl 1:S53-7.
 35. Raji CA, Tarzwell R, Pavel D, Schneider H, Uszler M, Thornton J, van Lierop M, Cohen P, Amen DG, Henderson T. Clinical utility of SPECT neuroimaging in the diagnosis and treatment of traumatic brain injury: a systematic review. *PLoS One.* 2014 Mar 19;9(3):e91088.
 36. Assadi M, Eftekhari M, Gholamrezanezhad A. SPET brain scan with (99m)Tc-ECD and CT, MRI in traumatic brain injury with chronic symptoms. *Hell J Nucl Med.* 2007 Sep-Dec;10(3):183.
 37. Eftekhari M, Assadi M, Kazemi M, Saghari M, Mojtahedi A, Fard-Esfahani A, Sichani BF, Beiki D. Brain perfusion single photon emission computed tomography findings in patients with posttraumatic anosmia and comparison with radiological imaging. *Am J Rhinol.* 2006 Nov-Dec;20(6):577-81.
 38. Rupright J, Woods EA, Singh A. Hypoxic brain injury: evaluation by single photon emission computed tomography. *Arch Phys Med Rehabil.* 1996 Nov;77(11):1205-8.