

DICHOTOMOUS INDIUM-111 LABELED LEUKOCYTE SCAN FINDINGS WHILE EVALUATING OSTEOMYELITIS IN A FAILED MANDIBULAR GRAFT

Jack R McEwan, MD, Simin Dadparvar, MD,
and Walter J Slizofski, MD

Division of Nuclear Medicine, Department of Radiation Oncology & Nuclear Medicine,
Hahnemann University Hospital, Philadelphia, PA, USA

ABSTRACT

Markedly elevated ^{111}In labeled leukocyte activity suggestive of acute osteomyelitis was observed in a region of a composite mandibular allograft that was photon deficient on $^{99\text{m}}\text{Tc}$ MDP bone scintigraphy. This finding was later confirmed by surgical pathology. The patient was treated with intravenous antibiotics and returned two months later with persistent bone infection. The follow-up three phase bone and ^{111}In labeled leukocyte scans were performed. The photopenic region noted in the previous bone scan demonstrated a mild interval increase in activity, while the ^{111}In labeled leukocyte activity was essentially normal. Additional imaging of the composite allograft was then performed using ^{67}Ga -citrate at 24 and 48 hours post injection. These images revealed focal areas of increased Gallium activity in the photopenic region of the graft exhibiting normal ^{111}In leukocyte activity. The tissue culture confirmed underlying chronic osteomyelitis. We conclude that normal uptake on ^{111}In labeled leukocyte and photon deficient regions on $^{99\text{m}}\text{Tc}$ bone scintigraphy do not necessarily exclude the presence of chronic osteomyelitis. In the management of patients who have been on prolonged antibiotic therapy with persistent infection, ^{67}Ga scintigraphy is warranted.

Key words: osteomyelitis; ^{111}In ; $^{99\text{m}}\text{Tc}$ MDP; ^{67}Ga ; mandibular graft

INTRODUCTION

Viable composite mandibular allografts characteristically demonstrate normal or increased activity on $^{99\text{m}}\text{Tc}$ MDP bone scintigraphy during the first postoperative week (1-3). A failed allograft will exhibit decreased uptake of $^{99\text{m}}\text{Tc}$ MDP (2-6). When graft failure is complicated by osteonecrosis and osteomyelitis, additional imaging with ^{111}In labeled leukocytes and possibly ^{67}Ga citrate may be required to accurately assess the patient. This case report discusses the capabilities and limitations of $^{99\text{m}}\text{Tc}$ -MDP, ^{111}In labeled leukocyte, and ^{67}Ga

citrate scintigraphy in the evaluation of mandibular allografts.

CASE REPORT

A 15-year-old girl was the victim of a shotgun blast to the mandible, which avulsed the right and left mandibular bodies and symphysis. Following seven attempts at surgical reconstruction the patient received a cadaveric mandibular transplant with autologous cancellous bone harvested from the posterior iliac crest. A radiograph with an anterior view of

the composite allograft is presented in Fig. 1a. One month later a draining oral cutaneous fistula was noted near the composite allograft. A culture of the drainage grew pseudomonas species.

The patient was administered 8 mCi of ^{99m}Tc -MDP and a three phase bone scan was obtained. Anterior flow images of the mandible were unremarkable. Planar blood pool images revealed a lack of perfusion to the mandibular graft. The delayed bone image presented in Fig. 1b, demonstrates a photon deficient region in the distal portion of the right mandibular body and symphysis suggestive of graft failure. Markedly increased bone activity with associated hyperemia is visualized bilaterally in the distal rami.

Imaging with ^{111}In labeled leukocytes was performed six days later. Delayed planar images were obtained at four and twenty-four hours post injection. The four hour delayed image is presented in Fig. 1c and shows regions of increased leukocyte activity in the symphysis and angle of the right mandible. The activity in the symphysis is consistent with osteomyelitis, and corresponds to the location of the photon deficient region seen on the bone scan.

The patient was then hospitalized to receive intravenous antibiotics for the treatment of the draining fistula. The right mandibular graft was debrided and two teeth were extracted. During this procedure, a fistula approximately 6 millimeters in length, extending from the allograft to the cutaneous aspect of the right submandibular region was explored and irrigated with Neomycin solution. A dehiscence of the right body of the mandible for a distance of 3 centimeters from the location of the first or second molar was noted. A specimen of bone from the right alveolar ridge, visually assessed by the surgeon to be necrotic, was sent to surgical pathology where a region of osteomyelitis was identified. The patient was then treated with intravenous Tobramycin and Primaxin and was discharged home on oral antibiotics for six weeks.

Two months later, the patient returned and on examination persistent bone infection was suspected. The three phase bone and ^{111}In labeled leukocyte scans were repeated. The three phase bone scan demonstrated an area of mild hyperemia in the right mandibular body in the blood pool images. Delayed bone images presented in Fig. 2a, reveal an interval increase in activity in the photon deficient region in the symphysis and distal left and right mandibular

bodies. Regions of mildly increased bone activity were seen bilaterally in the proximal mandibular bodies. The follow-up ^{111}In labeled leukocyte scan is presented in Fig. 2b and shows no abnormalities. These studies were augmented with planar ^{67}Ga citrate images acquired at 24 and 48 hours post injection. The 48 hour ^{67}Ga citrate image is presented in Fig. 2c and shows focal areas of increased gallium activity in the symphysis and interior portion of the right mandible suggestive of chronic osteomyelitis. Cultures of the wound grew pseudomonas, streptococcus, serratia, and enterococcus species. The bone graft was removed and the patient subsequently responded to hyperbaric oxygen therapy and a course of intravenous Primaxin administered on an inpatient and outpatient basis.

DISCUSSION

The viability of mandibular bone graft is frequently assessed with Technetium-99m bone scintigraphy. The predictive value of bone scans in assessing the viability of mandibular bone grafts is greatest when performed within the first postoperative week (1,2,7). Bone grafts that are metabolically active and revascularized demonstrate normal or increased radiotracer uptake throughout the graft (3,7). Increased bone uptake in the first postoperative week has been suggested to result from the opening of vascular channels after surgery. As time progresses, increased bone activity may be related to bony remodeling in the graft. For this reason, the use of bone uptakes as an index of graft viability is optimally performed during the first postoperative week. In contrast, a nonvascularized graft will not concentrate radiotracer resulting in a photon deficient region on the scan.

In this patient, the first three phase bone scan was performed for the diagnosis of osteomyelitis approximately seven weeks after the patient had received her mandibular graft. This scan demonstrated a photopenic region in the symphysis of the mandible in both the blood pool and delayed images. This finding is the result of a severely compromised vascular supply and concomitant graft failure but the diagnosis of osteomyelitis could not be excluded with certainty. Six days after this scan an ^{111}In labeled leukocyte study was performed. In this study, the symphysis exhibited markedly elevated ^{111}In leukocyte activity consistent with osteomyelitis,

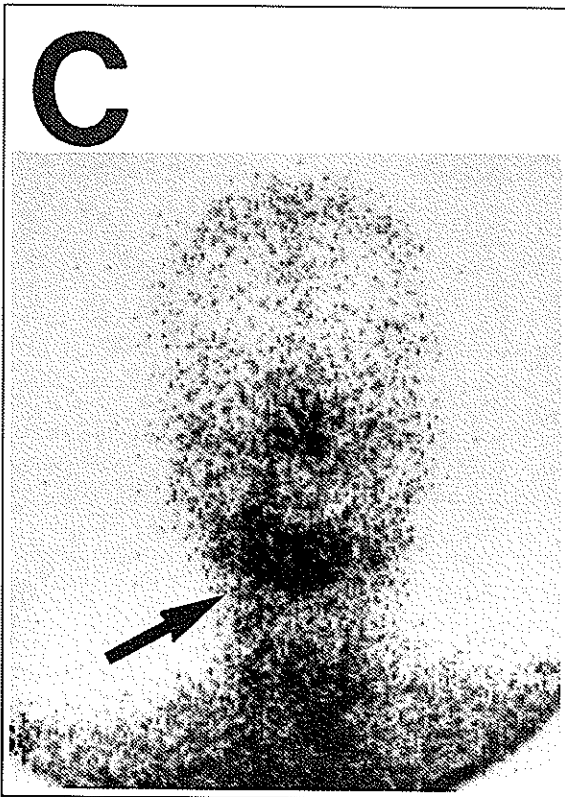
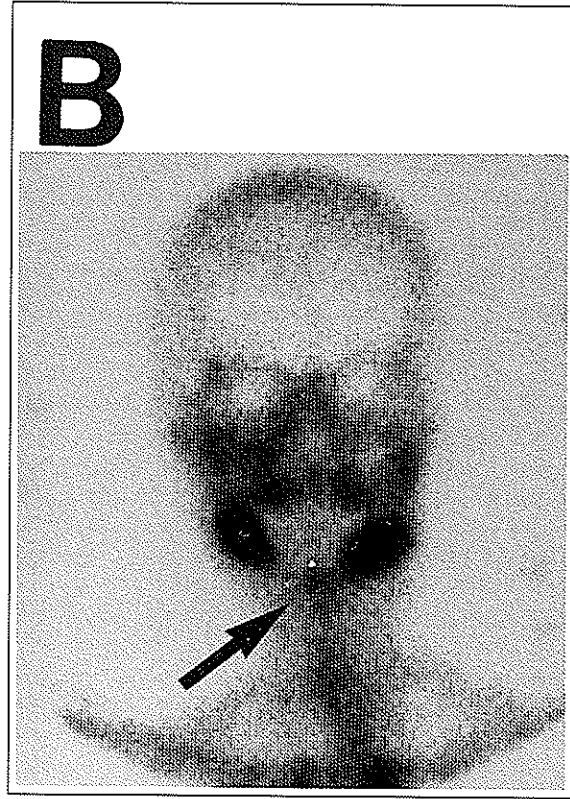
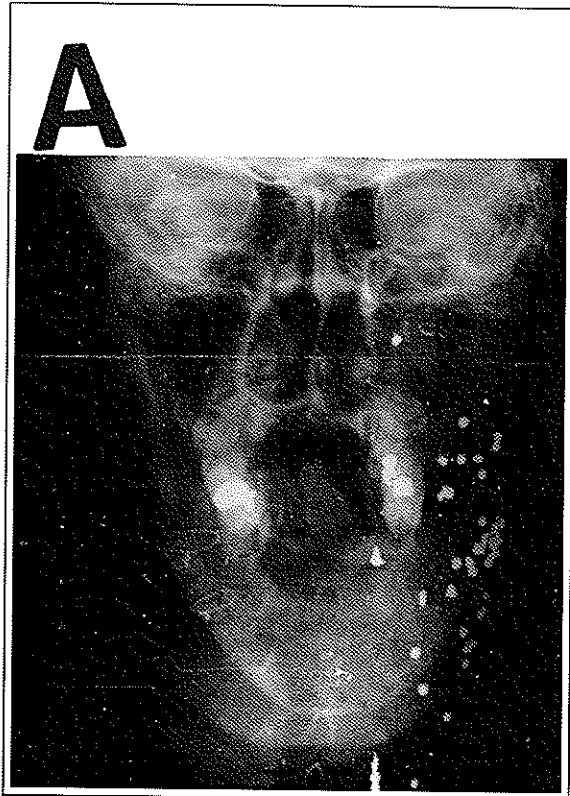


Fig. 1. Initial studies of the mandibular allograft.

1a: Anterior view of the composite mandibular allograft on a plain film radiograph. Numerous metallic artifacts representing shot gun pellets, are present in the soft tissues of the neck.

1b: Initial anterior bone scan of the mandibular allograft. Delayed bone image reveals a photon deficient region in the distal portion of the right mandibular body and symphysis suggestive of graft failure (arrow).

1c: Initial ^{111}In labeled leukocyte scan image acquired at 4 hours post injection which shows regions of markedly elevated leukocyte activity in the symphysis and angle of the right mandible (arrow). This image suggests the presence of osteomyelitis with contiguous soft tissue involvement.

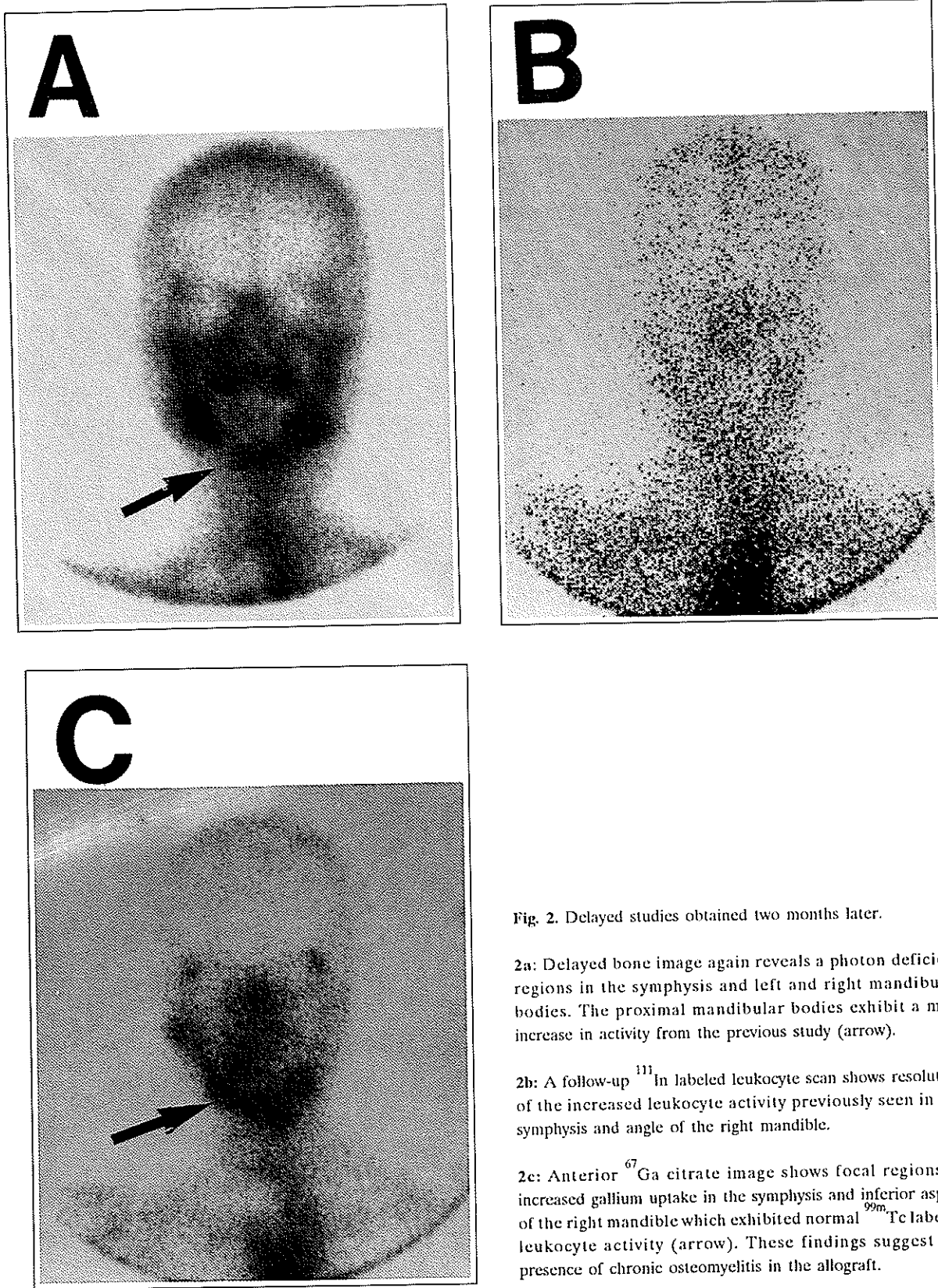


Fig. 2. Delayed studies obtained two months later.

2a: Delayed bone image again reveals a photon deficient regions in the symphysis and left and right mandibular bodies. The proximal mandibular bodies exhibit a mild increase in activity from the previous study (arrow).

2b: A follow-up ^{111}In labeled leukocyte scan shows resolution of the increased leukocyte activity previously seen in the symphysis and angle of the right mandible.

2c: Anterior ^{67}Ga citrate image shows focal regions of increased gallium uptake in the symphysis and inferior aspect of the right mandible which exhibited normal $^{99\text{m}}\text{Tc}$ labeled leukocyte activity (arrow). These findings suggest the presence of chronic osteomyelitis in the allograft.

which was confirmed by biopsy.

These findings represent a dichotomy in that a photon deficient region in the body of the right mandibular graft on a ^{99m}Tc -MDP scan was found to correlate with a region of markedly increased activity on a ^{111}In leukocyte scan. Osteomyelitis was subsequently identified in a histopathologic specimen from the bone graft that was assessed by the surgeon to be necrotic.

D'Ambrosia and coworkers have demonstrated that necrotic native bone appears as a photopenic defect if ^{99m}Tc diphosphonate scintigraphy is performed within weeks of an avascular insult (3). Months later, an area of increased activity will be seen in the previously photopenic region, resulting from the revascularization and reparative processes (8). Considering that the necrotic bone was debrided from a failed, poorly vascularized graft it is not surprising that it appeared as a photon deficient region on ^{99m}Tc -MDP scintigraphy. Photon deficient regions or so called "cold spots" have been seen in early osteomyelitis (9) and may result from the interruption of blood supply to the graft.

The osteomyelitis arising within the bone graft infection extended into the soft tissue and developed a fistula and perhaps dehiscence. This hypothesis is supported by the presence of markedly abnormal ^{111}In leukocyte activity seen at 4 hours post injection bilaterally in the distal bodies and in the symphysis of a poorly or nonvascularized graft. If the infection originated from within the graft one might expect a progressive increase in leukocyte activity over a 24 hour time interval secondary to vascular impairment of leukocyte transport. This situation could manifest as significant difference in the leukocyte activities visualized at 4 and 24 hours post injection. Markedly increased bone activity with associated hyperemia was seen bilaterally in the distal rami where the mandibular graft is attached to native bone. These findings most likely represent postoperative remodeling as this area did not exhibit abnormal activity on the ^{111}In leukocyte scan.

The patient was administered intravenous antibiotics and treated in hyperbaric chamber with oxygen. The three phase bone and ^{111}In labeled leukocyte scans were repeated two months later to evaluate the efficacy of treatment since the patient had clinically demonstrated persistent bone infection. The delayed bone images showed an interval increase in the activity in the photon deficient region previously seen in

the symphysis and bilaterally in the mandibular bodies. Since no focal accumulations of leukocytes were present on the ^{111}In leukocyte scan, additional imaging with ^{67}Ga citrate was performed. The gallium images revealed significantly increased activity in the symphysis and the inferior portion of the right mandible which was proved to be osteomyelitis on bone biopsy.

The false negative ^{111}In leukocyte scan may in part result from the tagging process, producing a radiation induced reduction in the longevity of labeled lymphocytes which participate in the chronic inflammatory process. Both polymorphonuclear leukocytes (PMN's) and lymphocytes are labeled by ^{111}In oxime. However, Thakur has noted that lymphocytes and other mononuclear cells are more susceptible to radiation damage than PMN's and feels that ^{67}Ga citrate is probably more sensitive than labeled leukocytes in chronic bone infections (10-12). This supports similar findings of McDougall and coworkers indicating that the presence of normal ^{111}In labeled leukocyte scan does not exclude chronic osteomyelitis (13).

CONCLUSION

This case readily demonstrates that acute osteomyelitis cannot be excluded in photopenic areas in composite mandibular allografts on Technetium-99m bone scintigraphy. Further evaluation with ^{111}In labeled leukocytes and ^{67}Ga citrate imaging may be necessary to identify the presence of acute and chronic osteomyelitis, respectively. In formulating the clinical decisions in the management of patients with failed mandibular graft the ^{111}In leukocyte uptake confirms the diagnosis of acute osteomyelitis. The ^{67}Ga citrate imaging should be given consideration on patients with suspected chronic osteomyelitis prior to surgical intervention.

Acknowledgments: The authors would like to express their appreciation to Mrs. Hope Young for her excellent secretarial skills and Mr. Edward Yeager for the preparation of the photographs used in this manuscript.

Address correspondence to: Simin Dadparvar, MD, Hahnemann University Hospital, Division of Nuclear Medicine, MS 309, Broad & Vine streets, Philadelphia, PA 19102, USA.

REFERENCES

1. Karcher H, Fuger G, Borbely L.: Bone scintigraphy of vascularized bone transfer in maxillofacial surgery. *Oral Med Oral Pathol* 65: 519-522; 1988.
2. Fig LM, Shulkin BL, Sullivan MJ, et al: Utility of emission tomography in evaluation of mandibular bone grafts. *Arch Otolaryngol Head Neck Surg* 116: 191-196; 1990.
3. D'Ambrosia RD, Shoji H, Riggins RS, et al, Stadalnik RC, DeNardo GL. Scintigraphy in the diagnosis of osteonecrosis. *Clin Orthopaedics Related Research* 130: 139-143; 1978.
4. Lipson RA, Dief H, Greyson ND, et al, Kawano H, Gross AE, Langer F, Halloran PF. Bone scanning in assessing viability of vascularized skeletal tissue transplants. *Clin Orthopaedics Related Research* 160: 279-289; 1981.
5. Berggen A, Weiland AJ, Ostrup LT.: Bone scintigraphy in evaluating the viability of composite bone grafts revascularized by microvascular anastomoses, conventional autogenous bone grafts, and free non-vascularized periosteal grafts. *J Bone Joint Surg* 64-A: 799-809; 1982.
6. Lukash FN, Tenenbaum NS, Moskowitz G.: Long-term fate of the vascularized iliac crest bone graft for mandibular reconstruction. *Am J Surg* 160: 399-401; 1990.
7. Lecklitner ML, Beasley JJ, Finn MC. Bone imaging in the assessment of en bloc osteocutaneous autotransplantation. *Clin Nucl Med* 13: 186-187; 1988.
8. Gregg PJ, Walder DN.: Scintigraphy versus radiography in the early diagnosis of experimental bone necrosis. *J Bone Joint Surg* 62-B: 214-221; 1980.
9. Jones DC, Cady RB.: "Cold" bone scans in acute osteomyelitis. *J Bone Joint Surg* 63B: 376-378; 1981.
10. Thakur ML.: Immunoscintigraphic imaging of inflammatory lesions: Preliminary findings and future possibilities. *Semin in Nucl Med* 20: 92-98; 1990.
11. Thakur ML.: Cell labeling: achievements, challenges, and prospects. *J Nucl Med* 22: 1011-1014; 1981.
12. Coleman RE, Welch DM, Baker WJ, et al: Clinical experience using Indium-111 labeled leukocytes. In Thakur ML, Gottschalk A (eds) ¹¹¹In Labeled Neutrophils, Platelets, and Lymphocytes. New York: Trivium; 1981: 103-118.
13. McDougall IR, Baumert JE.: Evaluation Of ¹¹¹In leukocyte whole body scanning. *Am J Radiol* 133: 819-853; 1979.