

Clinical significance of additional lateral imaging in diagnosis of prosthesis infection by combined Tc-99m labeled leukocyte/bone marrow scintigraphy

Zehra Pınar Koç¹, Pelin Özcan Kara¹, Arzu Kaya², Erhan Yılmaz³, Özlem Üçer⁴

¹Nuclear Medicine Department, Faculty of Medicine, Mersin University, Mersin, Turkey

²Physical Therapy and Rehabilitation Department, Fırat University, Elazığ, Turkey

³Department of Orthopedics, Fırat University, Elazığ, Turkey

⁴Department of Pathology, Fırat University, Elazığ, Turkey

(Received 14 September 2017, Revised 12 February 2018, Accepted 17 February 2018)

ABSTRACT

Introduction: Recently the most accurate diagnostic method in the diagnosis of prosthesis infection is the combination of Tc-99m labeled leukocyte/bone marrow imaging. However the diagnostic efficiency of the test is influenced because of its low spatial resolution. Recently SPECT/CT imaging is implicated in this test with efficient additional diagnostic improvement. In the departments without capability of SPECT/CT lateral imaging may provide important clinical information. The aim of this study was to analyze the additional diagnostic information provided by additional lateral spot images to the diagnostic accuracy of combined Tc-99m labeled leukocyte/bone marrow imaging in diagnosis of prosthesis infection.

Methods: Retrospective evaluation of 11 patients (9 F, 2 M; 61±8,6 years old) with pre-diagnosis of prosthesis infection (4 patients with right knee, 3 left, 2 bilateral, 2 right hip) by two experienced Nuclear Medicine physicians were included into the study. The age of the prosthesis were 7,8±15,3 months by the time of imaging. The imaging was performed from the region of interest at the first, second and fourth hour of injection of approximately 5 mCi (185 MBq) labeled leukocyte imaging and one hour after injection of 5 mCi (185 MBq) Tc-99m nanocolloid in anteroposterior and in additional lateral position. The diagnosis of prosthesis infection was decided in case of increased activity accumulation in leukocyte imaging higher than in bone marrow imaging. The final diagnosis was decided by additional aspiration biopsy (n=1), culture results (n=3), revision arthroplasty (n=1) or according to follow up results (n=6)(sedimentation, CRP) in 3,4±3,4 months follow up.

Results: The labeling efficiency of the patients was in an acceptable range (33-67%) in leukocyte labeling. The diagnosis of prosthesis infection was decided in two patients according to scintigraphy results and these two patients were documented to have prosthesis infection (revision arthroplasty and biopsy results). One patient was decided to have prosthesis infection despite negativity of scintigraphy (false negative) due to persistently high sedimentation, CRP levels in follow up despite proper antibiotic treatment. One patient was diagnosed as negative due to demonstration of anterior cellulites rather than prosthesis infection in the lateral images. The diagnostic sensitivity, specificity, accuracy, negative and positive predictive value of the test were 60%, 87.5%, 81%, 60%, 87.5%, respectively for anteroposterior imaging only with additional lateral imaging the rates were increased to 60%, 100%, 91%, 89% and 89%, respectively.

Conclusion: Lateral imaging increases the diagnostic accuracy of the combined Tc-99m labeled leukocyte/bone marrow scintigraphy compared to anteroposterior imaging only and might be implemented in combined imaging protocol in case of non-availability of SPECT/CT imaging.

Key words: Prosthesis; Infection; Lateral imaging; Tc-99m labeled leukocyte

Iran J Nucl Med 2018;26(2):98-104

Published: July, 2018

<http://irjnm.tums.ac.ir>

Corresponding author: Dr Zehra Pınar Koç, Nuclear Medicine Department, Faculty of Medicine, Mersin University, Mersin, Turkey. E-mail: zehrapinarkoc@gmail.com

INTRODUCTION

The diagnosis of infected lower limb prostheses is a challenge and differential diagnosis of infection is extremely important. Limitations of the morphological imaging methods like CT (Computed tomography) or MRI (Magnetic resonance imaging) are basically related to the artifacts due to prosthetic material or being not able to perform the imaging due to those materials. The most important diagnostic tool for identification of infection is labeled leukocyte imaging (WBC) with reported sensitivity of 60-100% and specificity of 69-92% [1]. Fortunately WBC imaging has diagnostic ability to differentiate inflammation from infection [2]. Additionally WBC imaging has diagnostic power of detecting both acute and chronic infection with similar accuracy [3].

There are additional procedures and imaging applications in WBC imaging in order to improve diagnostic facility. Some of those additional procedures considered as a requirement like additional bone marrow imaging. Due to the violated nature of the bone in the periprosthetic area (operative trauma) it may be impossible to differentiate bone marrow reaction from infection in WBC imaging. Recently, it has been accepted to interpret WBC imaging with bone marrow scintigraphy in routine practice and this methodology has the highest accuracy in prosthesis infection imaging.

The negative predictive value of bone scintigraphy is extremely high in prosthesis infection imaging thus bone scintigraphy might be used as a first line imaging method in order to exclude infection. In a recent study it was observed that angiographic imaging of bone scintigraphy might exclude the patients who do not need WBC imaging in 70% of patients [4].

Previously Ga-67 imaging was performed in suspicion of infection with diagnostic accuracy of 60-80% [5]. Recently there are many studies about the diagnostic capacity of F-18 FDG PET/CT (Fluorodeoxyglucose positron emission tomography/computed tomography) in prosthesis infection which may be high in some series [6]. However comparative studies showed that WBC imaging with bone marrow scintigraphy is superior to F-18 FDG PET/CT in diagnosis of prosthesis infection [7].

The lack of spatial resolution of planar imaging by means of WBC/bone marrow scintigraphy was an important problem. Recently, SPECT/CT (Single photon emission tomography/computed tomography) is introduced as the most sophisticated imaging modality as an adjunct to WBC imaging. In a study planar imaging provided true diagnosis in all infected and non-infected prostheses and additional SPECT/CT provided differentiation of soft tissue and bone infection [8].

Unfortunately SPECT/CT is not available in all Nuclear Medicine Departments thus it is not possible

to perform additional SPECT/CT to planar WBC imaging. In this study we investigated the effect of performing lateral image as an adjunct to WBC imaging in diagnosis of lower extremity prosthesis infection.

METHODS

Patients

11 patients (9 F, 2 M; 61 ± 8.6 years old) with pre-diagnosis of prosthesis infection (4 patients with right knee, 3 left, 2 bilateral, 2 right hip) were subjects of this study. The mean age of the prosthesis of the patients were 7.8 ± 15.3 months by the time of imaging. The patients were evaluated by physical examination, plain radiography and additional cross sectional imaging if considered necessary. The patients with suspicion of prosthesis infection of knee or hip prosthesis were included. All of the patients were informed regarding the imaging procedure and informed consents of the patients were obtained. The study was approved by local ethic committee. The patients with history of additional diagnosis (DM, bone disorders, malign tumors and other conditions that might affect bone metabolism) and pediatric age were excluded from the study. The follow up of the patients was performed by the same methodology. The final diagnosis was decided by additional aspiration biopsy (n=1) (Figure 1), culture results (n=3), revision arthroplasty (n=1) or according to follow up results (n=6) (sedimentation, CRP) in 3.4 ± 3.4 months follow up.

Leukocyte labeling

Labeled leukocyte scintigraphy was performed in all patients. Approximately 50 ml (adjusted according to the body weight) blood was drawn from the venous line in antecubital vein to an injector including 7 ml ACD (adjusted according to the amount of blood) solution (Mediflex; Baxter). After separation of 5 ml of this mixture for cell free plasma separation (centrifuged 10 min in 1000 g; by centrifugation device; Hettich Universal 320R) 6 ml Voluven (Fresenius Kabı) was added and the injector containing the mixture left for gravity sedimentation for an hour in upright position. The supernatant was separated via 18 G cannula and centrifuged at 500 g for 5 minutes; supernatant was separated the left leukocytes were washed with saline by pipette. After centrifugation 5 minutes at 500 g supernatant was removed the leukocytes were incubated with 10 mCi of Tc-99m hexamethylpropyleneamineoxime (^{99m}Tc -HMPAO) (prepared by administration of fresh Tc-99m in the ready kite Brain SPECT; Medi Radiopharma) in approximately 1 ml volume for ten minutes.

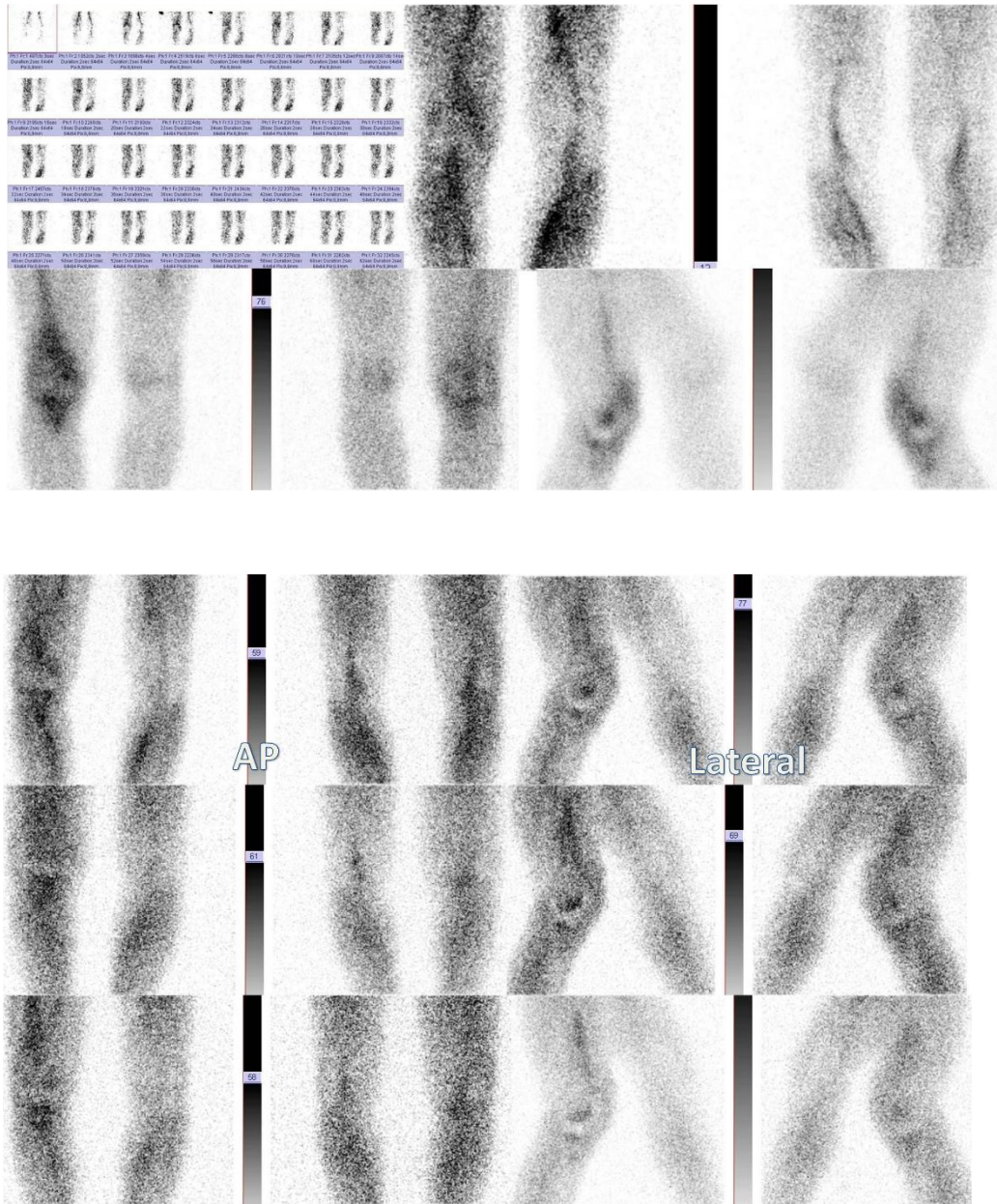
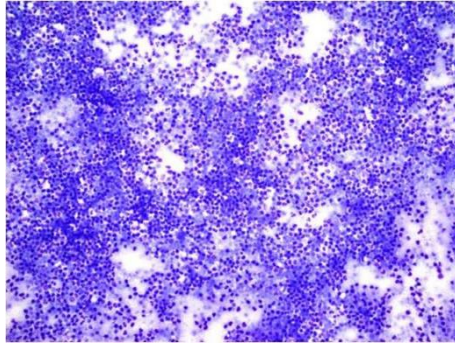


Fig 1. Aspiration biopsy image showing severe polymorphonuclear leukocytes (May-Grunwald Giemsa x200) (above). Bone scintigraphy image of the patient; 74 years old male patient with two years old right knee prosthesis, scintigraphy images showing prosthesis infection; increased vascularity and activity accumulation around the prosthesis in the late phase as well (middle). Three time point labeled leukocyte images of the same patient with activity accumulation around the right prosthesis (below).

After centrifugation of mixture for 5 minutes the supernatant and leukocytes were retrieved and measured for radioactivity in dose calibrator for decision of labeling ratio (Atom Lab 100). All the labeling procedures were performed under laminar flow cabinet (Nuve LN090). Labeling efficiency was calculated according to the formula;

Labeling efficiency = Activity in leukocytes/(Activity in leukocytes + Activity in supernatant)

Scintigraphy

The labeled leukocyte scintigraphy was performed one, two and four hours after injection of leukocytes in planar mode by SPECT gamma camera (GE, Infinia II, Israel) under sedation. The images were compared by visual evaluation and quantification by two experienced nuclear medicine physicians. The rectangular region of interests (ROI) was generated in order to evaluate background region including the least active part of the imaging study and irregular ROI's for the prosthesis covering all components of the prosthetic region (Figure 2).

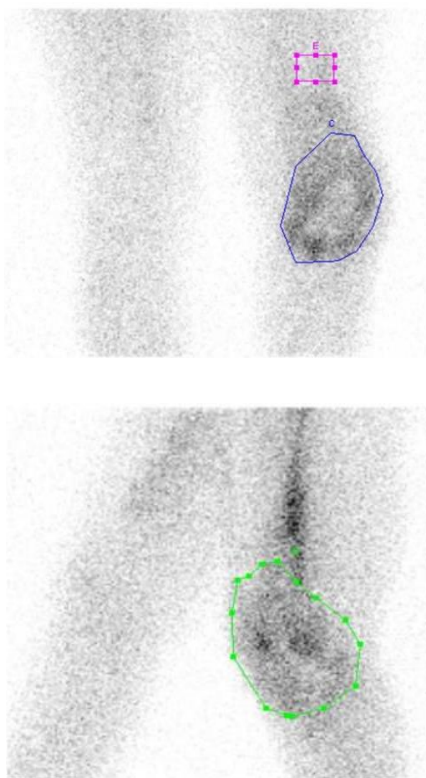


Fig 2. Anteroposterior labeled leukocyte scintigraphy early (1 hour) image of a patient with left knee prosthesis; an example case for demonstration of region of interest including knee region (irregular) and background region (rectangular) (above). Lateral projection bone marrow image of an example patients to demonstrate irregular region of interest covering left knee prosthesis (below).

All the quantifications were performed in the early, late images (first, second and fourth hour) of labeled leukocyte imaging and bone marrow imaging both for anteroposterior and for lateral images with same methodology from two independent observers. The division of average counts corresponding to the previously described ROI's of bone marrow and labeled leukocyte images was obtained with background subtractions in order to generate special index values. The index values of two different observers were compared. The bone marrow imaging was performed by one hour after injection of 5 mCi (185 MBq) Tc-99m nanocolloid in anteroposterior and in additional lateral position. The diagnosis of prosthesis infection was decided in case of increased activity accumulation in leukocyte imaging higher than in bone marrow imaging. Retrospective evaluation of the images of these patients by two experienced Nuclear Medicine Physicians who did not know final diagnosis was performed independently by both visual analysis and quantification.

Statistical analysis

The comparison of the variables were performed by Paired Sample Students T test and $p < 0.05$ considered significant.

RESULTS

The labeling efficiency of the patients was in an acceptable range (33-67%) in leukocyte labeling.

The diagnosis of prosthesis infection was decided in two patients according to scintigraphy results and these two patients were documented to have prosthesis infection (revision arthroplasty and biopsy results). One patient was decided to have prosthesis infection despite negativity of scintigraphy (false negative) due to persistently high sedimentation, CRP levels in follow up despite proper antibiotic treatment. One patient was diagnosed as negative due to demonstration of anterior cellulites rather than prosthesis infection in the lateral images.

According to these findings the diagnostic sensitivity, specificity, accuracy, negative and positive predictive value of the test were 60%, 87.5%, 81%, 60%, 87.5% respectively for anteroposterior imaging only with additional lateral imaging the rates were increased to 60%, 100%, 91%, 89% and 89%, respectively.

In the comparison of two different observers results there were no statistical difference between the index values obtained from the analysis of two observers with the same methodology and additionally strong correlation between the results of two observers was obtained ($p > 0.05$) (Figure 3).

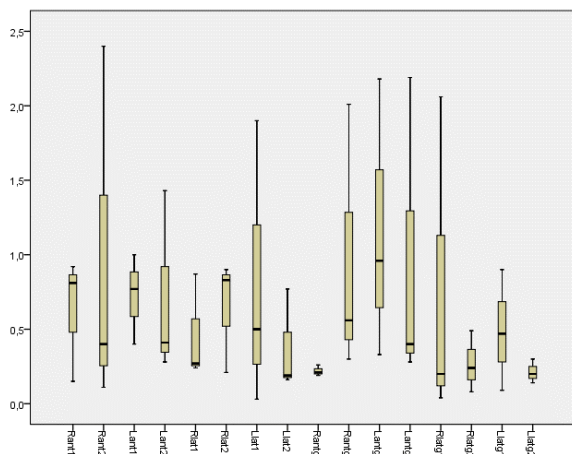


Fig 3. Box plot demonstration of the index values in comparison including the values of both observers for all prosthesis.

Visual analysis results of these observes were also correlated with each other.

DISCUSSION

Labeled leukocyte imaging is the most accurate method for evaluation of prosthetic infections [1]. In this study we also obtained high diagnostic accuracy of the test in combination with bone marrow scintigraphy. The diagnostic accuracy of the method increased significantly (81% vs 91%) with additional lateral imaging especially specificity and positive predictive value of the test was excellent (100 % and 89% respectively). The sensitivity of the test was low however this may be attributed to the patient with false negative result who had anamnesis of antibiotic treatment before and during the test. Patient selection for the test may prevent this kind of problems.

Diagnostic accuracy of F-18 FDG PET/CT is slightly higher for hip prosthesis infection than knee prosthesis infection according to previous literature [9]. Most of the patients in this study had knee prosthesis which is more appropriate for WBC imaging. In contrast there are series that found really insufficient sensitivity (64%) and specificity (67%) ratios for F-18 FDG PET/CT in diagnosing prosthesis infection [10].

Love et al. investigated different criteria for image interpretation and concluded that bone prosthesis interface activity compared to background ratio greater than 3.6 for hip and 3.1 for knee prosthesis might provide accuracy of 95% [11]. We performed the quantification by additive bone marrow imaging and background subtractions. The WBC imaging with additional bone marrow imaging is the most accurate method in imaging of lower extremity prosthesis infection [12].

The treatment of infected prosthesis requires removal of infected prosthesis, long term antibiotic treatment with eventual operative replacement of new prosthesis

[13]. Joint aspirations are specific for infection however not sensitive thus is not reliable [14]. Thus nuclear medicine imaging modalities are the last step to determine the operation and therapeutic approach for management of the patients. Bone scintigraphy might provide diagnosis of loosening accurately however cannot differentiate aseptic loosening from septic loosening [15]. Although it was suggested to consider focal periprosthetic uptake for aseptic and diffuse uptake as septic loosening, this methodology is not specific [16]. Some researchers advised serial imaging with bone scintigraphy [17]. Palestro et al. investigated imaging by combined WBC and bone scintigraphy but could not provide high diagnostic accuracy for knee prosthesis [18].

In a comparative study in 88 patients FDG PET was suggested as a favorable method compared to combination of In-111 labeled leukocyte/Tc-99m sulphur colloid bone marrow imaging [19]. FDG PET imaging has advantages of lower radiation exposure and higher spatial resolution besides it has similar sensitivity for acute and chronic infections and is not affected by antibiotic treatment. Contradictory results were achieved by Love et al. [20] and Stumpe et al. [21] that FDG PET cannot replace WBC imaging. Unfortunately there is no well-established criterion for positivity of FDG PET; some authors suggest bone prosthesis interface activity around proximal femur and acetabulum while others accept diffuse increased uptake around the prosthesis. However all the researchers agree that the intensity of the uptake (SUV) is not correlated with infection [22].

Tc-99m HMPAO leukocyte imaging combined with SPECT/CT revealed similar results with sensitivity, specificity and accuracy of 93% compared to dual modality (WBC/bone marrow imaging) in a recent study [23]. Other previous investigations point out the same results that SPECT/CT can accurately differentiate adjacent soft tissue infection from bone infection in both osteomyelitis and prosthesis infection thus may change surgical approach which may be extremely different [24-27]. The results of this study demonstrated the importance of lateral imaging additional to anteroposterior imaging in the diagnosis of prosthesis infection by radionuclide imaging. We emphasize the fact that SPECT/CT is surely a superior modality than planar imaging however it is not available in all departments. Lateral imaging additional to anteroposterior imaging might obviate the need of additional SPECT/CT. Comparative large prospective studies may provide more robust information regarding this issue.

Dual time point imaging in WBC scintigraphy has been evaluated in a previous multicenter study; authors suggested that dual time point imaging may obviate the need for additional bone marrow imaging [28]. There is physiological uptake in bone scan

around prosthesis for a long time after surgery this duration may be longer in prosthesis without cement (>2 years) [29]. Additionally there is considerable variation between the bone marrow uptakes of the patients as we observed in this study. This is the first study indicating an index value comparing the bone marrow and WBC scan images which shows that this method may be helpful. Previous studies also validated this finding [30]. In fact we did not observe any advantage of late phase imaging despite long term three phase imaging performed using both visual and quantitative analysis. Additionally in this study we obtained similar and well correlated quantitative results of two different observers pointing out good to interobserver variability for the methods. This finding was also not confirmed by the literature previously because most of the previous studies could not show good interobserver agreement including analysis of labeled leukocyte imaging methods [31].

Recently the Tc-99m ubiquicidin (UBI) scintigraphy has been introduced with high diagnostic accuracy (93.7%) in a study in determination of the prosthesis infection [32]. Future comparative studies with WBC scintigraphy are warranted as a gold standard diagnostic method.

Study limitations

The major limitation of this study is the number of cases which is not enough to draw a conclusion however no comparable study has been previously reported. The other limitations of this study may be heterogeneity of the group (including both knee and hip prosthesis). Also lack of histopathology results of negative patients may be considered as another limitation.

CONCLUSION

This study provided the comparative analysis of combined labeled leukocyte and bone marrow scintigraphy in diagnosis of prosthesis infection in planar manner with additional lateral imaging. Lateral imaging might provide important diagnostic information especially in knee prosthesis. However whether it may obviate the need for SPECT/CT needs to be evaluated with large prospective series. Additionally this study showed good interobserver agreement in quantitative analysis contradictory to other previous quantitative labeled leukocyte studies.

REFERENCES

- Lewis SS, Cox GM, Stout JE. Clinical utility of indium 111-labeled white blood cell scintigraphy for evaluation of suspected infection. *Open Forum Infect Dis*. 2014 Sep 17;1(2):ofu089.
- Becker W, Meller J. The role of nuclear medicine in infection and inflammation. *Lancet Infect Dis*. 2001 Dec;1(5):326-33.
- Datz FL, Thorne DA. Effect of chronicity of infection on the sensitivity of the In-111-labeled leukocyte scan. *AJR Am J Roentgenol*. 1986 Oct;147(4):809-12.
- Granados U, Fuster D, Soriano A, García S, Bori G, Martínez JC, Mayoral M, Perlaza P, Tomás X, Pons F. Screening with angiographic images prior to (99m)Tc-HMPAO labeled leukocyte scintigraphy in the diagnosis of periprosthetic infection. *Rev Esp Med Nucl Imagen Mol*. 2015 Jul-Aug;34(4):219-24.
- Palestro CJ. Radionuclide imaging of osteomyelitis. *Semin Nucl Med*. 2015 Jan;45(1):32-46.
- Chacko TK, Zhuang H, Nakhoda KZ, Moussavian B, Alavi A. Applications of fluorodeoxyglucose positron emission tomography in the diagnosis of infection. *Nucl Med Commun*. 2003 Jun;24(6):615-24.
- Van Acker F, Nuyts J, Maes A, Vanquickenborne B, Stuyck J, Bellemans J, Vleugels S, Bormans G, Mortelmans L. FDG-PET, 99mTc-HMPAO white blood cell SPET and bone scintigraphy in the evaluation of painful total knee arthroplasties. *Eur J Nucl Med*. 2001 Oct;28(10):1496-504.
- Filippi L, Schillaci O. Usefulness of hybrid SPECT/CT in 99mTc-HMPAO-labeled leukocyte scintigraphy for bone and joint infections. *J Nucl Med*. 2006 Dec;47(12):1908-13.
- Zhuang H, Duarte PS, Pourdehnad M, Maes A, Van Acker F, Shnier D, Garino JP, Fitzgerald RH, Alavi A. The promising role of 18F-FDG PET in detecting infected lower limb prosthesis implants. *J Nucl Med*. 2001 Jan;42(1):44-8.
- García-Barrecheguren E, Rodríguez Fraile M, Toledo Santana G, Valentí Nín JR, Richter Echevarría JA. FDG-PET: a new diagnostic approach in hip prosthetic replacement. *Rev Esp Med Nucl*. 2007 Jul-Aug;26(4):208-20.
- Love C, Marwin SE, Tomas MB, Krauss ES, Tronco GG, Bhargava KK, Nichols KJ, Palestro CJ. Diagnosing infection in the failed joint replacement: a comparison of coincidence detection 18F-FDG and 111In-labeled leukocyte/99mTc-sulfur colloid marrow imaging. *J Nucl Med*. 2004 Nov;45(11):1864-71.
- Palestro CJ. Nuclear medicine and the failed joint replacement: Past, present, and future. *World J Radiol*. 2014 Jul 28;6(7):446-58.
- Palestro CJ, Love C, Miller TT. Infection and musculoskeletal conditions: Imaging of musculoskeletal infections. *Best Pract Res Clin Rheumatol*. 2006 Dec;20(6):1197-218.
- Tomas X, Bori G, Garcia S, Garcia-Diez AI, Pomes J, Soriano A, Ríos J, Almela M, Mensa J, Gallart X, Martinez JC, Riba J. Accuracy of CT-guided joint aspiration in patients with suspected infection status post-total hip arthroplasty. *Skeletal Radiol*. 2011 Jan;40(1):57-64.
- McInerney DP, Hyde ID. Technetium 99m pyrophosphate scanning in the assessment of the painful hip prosthesis. *Clin Radiol*. 1978 Sep;29(5):513-7.
- Williams F, McCall IW, Park WM, O'Connor BT, Morris V. Gallium-67 scanning in the painful total hip replacement. *Clin Radiol*. 1981 Jul;32(4):431-9.
- Hofmann AA, Wyatt RW, Daniels AU, Armstrong L, Alazraki N, Taylor A Jr. Bone scans after total knee

- arthroplasty in asymptomatic patients. Cemented versus cementless. *Clin Orthop Relat Res.* 1990 Feb;(251):183-8.
18. Palestro CJ, Swyer AJ, Kim CK, Goldsmith SJ. Infected knee prosthesis: diagnosis with In-111 leukocyte, Tc-99m sulfur colloid, and Tc-99m MDP imaging. *Radiology.* 1991 Jun;179(3):645-8.
 19. Basu S, Kwee TC, Saboury B, Garino JP, Nelson CL, Zhuang H, Parsons M, Chen W, Kumar R, Salavati A, Werner TJ, Alavi A. FDG PET for diagnosing infection in hip and knee prostheses: prospective study in 221 prostheses and subgroup comparison with combined (111)In-labeled leukocyte/(99m)Tc-sulfur colloid bone marrow imaging in 88 prostheses. *Clin Nucl Med.* 2014 Jul;39(7):609-15.
 20. Love C, Marwin SE, Tomas MB, Krauss ES, Tronco GG, Bhargava KK, Nichols KJ, Palestro CJ. Diagnosing infection in the failed joint replacement: a comparison of coincidence detection 18F-FDG and 111In-labeled leukocyte/99mTc-sulfur colloid marrow imaging. *J Nucl Med.* 2004 Nov;45(11):1864-71.
 21. Stumpe KD, Nötzli HP, Zanetti M, Kamel EM, Hany TF, Görres GW, von Schulthess GK, Hodler J. FDG PET for differentiation of infection and aseptic loosening in total hip replacements: comparison with conventional radiography and three-phase bone scintigraphy. *Radiology.* 2004 May;231(2):333-41.
 22. van der Bruggen W, Bleeker-Rovers CP, Boerman OC, Gotthardt M, Oyen WJ. PET and SPECT in osteomyelitis and prosthetic bone and joint infections: a systematic review. *Semin Nucl Med.* 2010 Jan;40(1):3-15.
 23. Kim HO, Na SJ, Oh SJ, Jung BS, Lee SH, Chang JS, Bin SI, Ryu JS. Usefulness of adding SPECT/CT to 99mTc-hexamethylpropylene amine oxime (HMPAO)-labeled leukocyte imaging for diagnosing prosthetic joint infections. *J Comput Assist Tomogr.* 2014 Mar-Apr;38(2):313-9.
 24. Filippi L, Schillaci O. Usefulness of hybrid SPECT/CT in 99mTc-HMPAO-labeled leukocyte scintigraphy for bone and joint infections. *J Nucl Med.* 2006 Dec;47(12):1908-13.
 25. Bar-Shalom R, Yefremov N, Guralnik L, Keidar Z, Engel A, Nitecki S, Israel O. SPECT/CT using 67Ga and 111In-labeled leukocyte scintigraphy for diagnosis of infection. *J Nucl Med.* 2006 Apr;47(4):587-94.
 26. Graute V, Feist M, Lehner S, Haug A, Müller PE, Bartenstein P, Hacker M. Detection of low-grade prosthetic joint infections using 99mTc-antigranulocyte SPECT/CT: initial clinical results. *Eur J Nucl Med Mol Imaging.* 2010 Aug;37(9):1751-9.
 27. Fink B. Revision of late periprosthetic infections of total hip endoprostheses: pros and cons of different concepts. *Int J Med Sci.* 2009 Sep 4;6(5):287-95.
 28. Erba PA, Glaudemans AW, Veltman NC, Sollini M, Pacilio M, Galli F, Dierckx RA, Signore A. Image acquisition and interpretation criteria for 99mTc-HMPAO-labelled white blood cell scintigraphy: results of a multicentre study. *Eur J Nucl Med Mol Imaging.* 2014 Apr;41(4):615-23.
 29. Pelosi E, Baiocco C, Pennone M, Migliaretti G, Varetto T, Maiello A, Bellò M, Bisi G. 99mTc-HMPAO-leukocyte scintigraphy in patients with symptomatic total hip or knee arthroplasty: improved diagnostic accuracy by means of semiquantitative evaluation. *J Nucl Med.* 2004 Mar;45(3):438-44.
 30. Van Dyke D, Price D, Shkurkin C, Yano Y, Anger HO. Differences in distribution of erythropoietic and reticuloendothelial marrow in hematologic disease. *Blood.* 1967 Sep;30(3):364-74.
 31. Kanegaye JT, Vance CW, Parisi M, Miller JH, Mahour GH, Chan LS, Schonfeld N. Failure of technetium-99m hexamethylpropylene amine oxime leukocyte scintigraphy in the evaluation of children with suspected appendicitis. *Pediatr Emerg Care.* 1995 Oct;11(5):285-90.
 32. Ostovar A, Assadi M, Vahdat K, Nabipour I, Javadi H, Eftekhari M, Assadi M. A pooled analysis of diagnostic value of (99m)Tc-ubiquicidin (UBI) scintigraphy in detection of an infectious process. *Clin Nucl Med.* 2013 Jun;38(6):413-6.