

## A rare case of primary malignant melanoma of cervix with metastasis to inguinal lymph node detected on $^{18}\text{F}$ -FDG PET-CT scan

Madan Gopal Vishnoi<sup>1</sup>, Amit Sharma<sup>1</sup>, Richa Ranjan<sup>1</sup>, Anurag Jain<sup>2</sup>, Neeraj Kumar<sup>1</sup>

<sup>1</sup>Department of Nuclear Medicine, Eastern Command Hospital, Kolkata, India

<sup>2</sup>Department of Nuclear Medicine, Southern Command Hospital, Pune, India

(Received 6 December 2020, Revised 22 February 2021, Accepted 27 February 2021)

### ABSTRACT

Primary malignant melanoma of uterine cervix is extremely rare malignancy with very few case published reports. This neoplasm is having poor prognosis, so early diagnosis, staging and treatment is of extreme importance.  $^{18}\text{F}$ -FDG PET-CT ( $^{18}\text{F}$ -labeled fluoro-2-deoxyglucose positron emission computed tomography) scan is an established modality to determine exact extent of disease in malignant melanoma thus determining the treatment protocol. In this reported case, PET-CT is showing primary lesion in uterine cervix with extension in to the vagina and involvement of left inguinal lymph nodes. No other abnormal  $^{18}\text{F}$ -FDG avid lesion or distant metastases noted in the scanned region of the body.

**Key words:** Metastatic malignant melanoma; Cervix,  $^{18}\text{F}$ -FDG; PET-CT

**Iran J Nucl Med 2021;29(2):111-113**

Published: July, 2021

<http://irjnm.tums.ac.ir>

**Corresponding author:** Anurag Jain, Department of Nuclear Medicine, Southern Command Hospital, Pune, India.  
E-mail: [triplea.jain@gmail.com](mailto:triplea.jain@gmail.com)

## INTRODUCTION

Malignant melanoma is a common neoplasm, usually affecting the sites like skin and mucous membranes. Female genital tract is very uncommon site for malignant melanoma (<2%) and here it usually involves vagina & vulva [1, 2]. Although cervix is an extremely rare site [3]. Here we report a case of malignant melanoma of uterine cervix with involvement of lower 1/3<sup>rd</sup> of vagina and metastases to left inguinal lymph node detected on <sup>18</sup>F-FDG PET-CT (<sup>18</sup>F-labeled fluoro-2-deoxyglucose positron emission computed tomography). Prognosis of multiple myeloma of female genital tract and especially uterine cervix is extremely poor. PET-CT used for staging, restaging, response assessment which further influence the treatment protocol.

## CASE PRESENTATION

An 85 years old lady reported to obstetrics and gynecology outpatient department with history of bleeding per vagina on and off since last six months, local examination of cervix was difficult due to vaginal stenosis. MRI of pelvis reveals polypoidal lesion involving anteroinferiorly wall of cervix and extending to involve vagina and likely infiltrating the urethra anteroinferiorly. Inferiorly lesion is protruding into the introits and superiorly it is reaching up to uterus, lateral pelvic walls are free from lesion; MRI also revealed a heterogeneously enhancing left

inguinal lymph node. Cervical biopsy is suggestive of cervical malignant melanoma which is immunopositive for Vimentin, HMB45, Melan-A and S-100 (Figure 1).

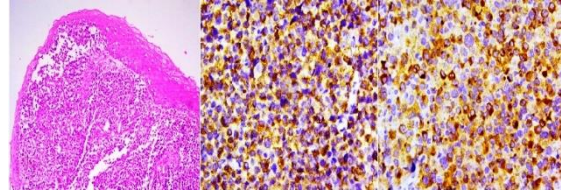


Fig 1. Cervical biopsy.

Biopsy is negative for CK, LCA, Desmin, Myogenin and CD-56. Patient underwent PET-CT scan which reveals metabolically active soft tissue lesion involving cervix with extension into the lower third of vagina, <sup>18</sup>F-FDG avid left inguinal lymph node and <sup>18</sup>F-FDG avid lesion in right lobe of thyroid gland (Figure 2).

Fine needle aspiration cytology (FNAC) done from lesion of right lobe of thyroid gland, reveals atypia of unknown significance (AUS) on Bethesda cytology system. It is an incidental finding and not a metastasis from cervical malignant melanoma.

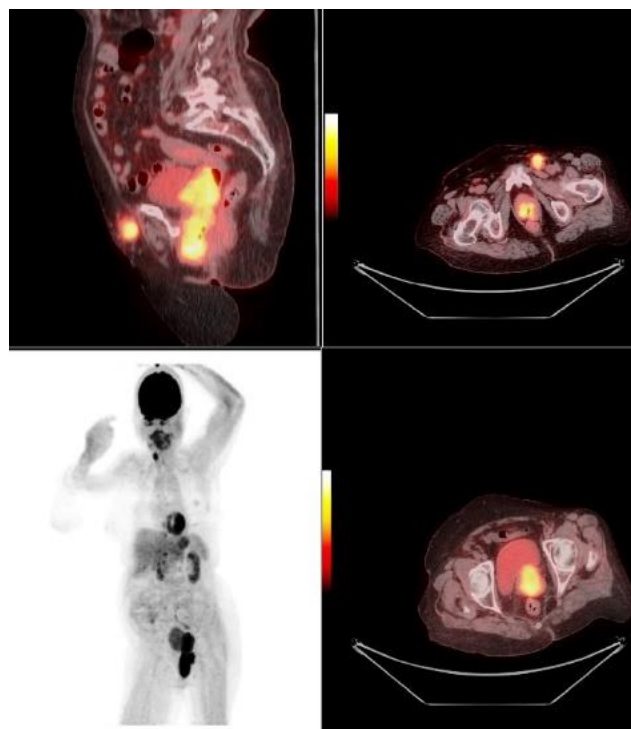


Fig 2. <sup>18</sup>F-FDG PET-CT scan.

## DISCUSSION

Malignant melanoma is a neoplasm of melanocytes or their cell lines, reported in age bracket of 19 to 83 years with peak incidence in age bracket of 60 to 70 years. It is generally involves areas of skin exposed to sun light exposed however few non exposed sites like esophagus, vulva and vagina also gets affected. The incidence of genital tract melanoma is predominantly in vulva (76.7%) and vagina (19.8%) and involvement of cervix is extremely rare [4, 5].

The common clinical symptoms are per vaginal discharge, bleeding and dyspareunia [6-8]. Usual findings during gynecological examination with colposcopy is apolypoidal exophytic mass. The mass lesion is grey, brown or black in melenetic melanoma and colorless in amelenotic melanoma. Occurrence of melenotic and amelenotic melanomas are generally equal (50- 50 %) within the cervix [9]. Cervical cervical smear shows round to spindle cells with melanin pigments in melenotic melanomas. However, in amelenotic melanomas it's difficult to differentiate the histology from rhabdomyosarcoma, leiomyosarcoma, mixed Mullerian tumor, adenocarcinoma and poorly differentiated epithelial cell carcinoma. For further accurate diagnosis immune staining is employed. Protein S100 is sensitive and HMB45 is restricted indicator of MM [10].

Very few literatures are available that mention use of PET-CT in staging of non-cutaneous melanoma [11]. PET-CT is well known modality in cutaneous melanoma employed for staging restaging and response assessment and in detection of lymph nodes well as visceral and non-visceral metastases. PET-CT staging is way better than clinical diagnostic imaging in stage III and stage IV melanomas [12]. Rarity of disease for non-cutaneous melanomas of female genital tract is probably a contributory factor for less reports on usage of PET-CT [11].

## CONCLUSION

Reported case is primary melanoma of cervix with extension within the vagina and nodal metastasis to left inguinal lymph gland due to vaginal involvement. No other visceral or non-visceral metastases were detected on <sup>18</sup>F-FDG PET-CT. Primary malignant melanoma of the cervix is a rare neoplasm but still it should be included in the differential diagnosis of cervical malignancies because of its very poor prognosis. Special consideration should be given in advanced age. Special staining and immune-histochemistry is standard diagnostic tool. One reason for its poor prognosis is diagnosis at advanced age. Hence, early diagnosis and accurate staging of cervical melanoma is essential. For accurate staging, restaging and response assessment and to know distant metastases PET has become a cornerstone over the

past decade. Data for use of PET-CT in non-cutaneous malignant melanoma are very limited because of rarity of disease and very few case reports only are available. PET-CT scan being a whole body imaging modality distant metastasis can be exactly diagnosed by it. Further studies with more number of patients are needed to determine whether PET should be used as an adjunct or in place of conventional imaging in non-cutaneous malignant melanomas.

## REFERENCES

1. Patrick RJ, Fenske NA, Messina JL. Primary mucosal melanoma. *J Am Acad Dermatol*. 2007 May;56(5):828-34.
2. Yücesoy G, Kus E, Cakiroglu Y, Muezzinoglu B, Yildiz K, Yucesoy I. Primary malignant melanoma of the cervix: report of a case. *Arch Gynecol Obstet*. 2009 Apr;279(4):573-5.
3. Pusceddu S, Bajetta E, Carcangiu ML, Formisano B, Ducceschi M, Buzzoni R. A literature overview of primary cervical malignant melanoma: an exceedingly rare cancer. *Crit Rev Oncol Hematol*. 2012 Feb;81(2):185-95.
4. McLaughlin CC, Wu XC, Jemal A, Martin HJ, Roche LM, Chen VW. Incidence of noncutaneous melanomas in the U.S. *Cancer*. 2005 Mar 1;103(5):1000-7.
5. Benson RJ, Tan LT. Radiation-induced malignant melanoma of the cervix *Clin Oncol (R Coll Radiol)*. 2000;12(4):234-7.
6. Pusceddu S, Bajetta E, Carcangiu ML, Formisano B, Ducceschi M., Buzzoni R, A literature overview of primary cervical malignant melanoma: an exceedingly rare cancer. *Crit Rev Oncol Hematol*. 2012 Feb;81(2):185-95.
7. Clark KC, Butz WR, Hapke MR. Primary malignant melanoma of the uterine cervix: case report with world literature review. *Int J Gynecol Pathol*. 1999 Jul;18(3):265-73.
8. Mordel N, Mor-Yosef S, Ben-Baruch N, Anteby SO. Malignant melanoma of the uterine cervix: case report and review of the literature. *Gynecol Oncol*. 1989 Mar;32(3):375-80.
9. Hinde EF, Amal B, Hannane S, Cherhazade B, Abdelaziz B, Nawfel M, Omar M. Unusual primary location of the malignant melanoma, the cervico-vaginal region: 3 cases and literature review. *Open J Obstet Gynecol*. 2012;2(3):279-282.
10. Deshpande AH, Munshi MM. Primary malignant melanoma of the uterine cervix: report of a case diagnosed by cervical scrape cytology and review of the literature. *Diagn Cytopathol*. 2001 Aug;25(2):108-11.
11. Oudoux A, Rousseau T, Bridji B, Reschel, Rousseau C. Interest of F-18 fluorodeoxyglucose positron emission tomography in the evaluation of vaginal malignant melanoma. *Gynecol Oncol*. 2004 Dec;95(3):765-8
12. Reinhardt MJ, Joe AY, Jaeger U, Huber A, Matthies A, Bucerius J, Roedel R, Strunk H, Bieber T, Biersack H, Tütting T. Diagnostic performance of whole body dual modality <sup>18</sup>F-FDG PET/CT imaging for N- and M-staging of malignant melanoma: experience with 250 consecutive patients. *J Clin Oncol*. 2006 Mar 1;24(7):1178-87.