

Bone Scan with Incidental Visualization of the Entire Colon

Mohammad Eftekhari, Armaghan Fard-Esfahani,
Mahdi Haghghatafshar, Arash Keivan, Davood Beiki,
Farahnaz Aghahosseini, Alireza Emami-Ardekani, Mohsen Saghari

Research Institute for Nuclear Medicine, Tehran University of Medical Sciences,
Tehran, Iran

(Received 9 February 2010, Revised 26 February 2010, Accepted 2 March 2010)

ABSTRACT

A 57-year-old male with history of prostatectomy, cystectomy, cecal urinary diversion for invasive prostate cancer and with a recent rise in PSA level, was referred for bone scintigraphy to rule out osseous metastatic disease. An interesting finding was abnormal tracer accumulation throughout the large bowel, which was proved to be due to urinary diversion.

Keywords: Bone scan, Visualization of colon, Soft tissue uptake, Tc-99m MDP

Iran J Nucl Med 2010;18(2):56-59

Corresponding author: Dr Mahdi Haghghatafshar, Research Institute for Nuclear Medicine, Tehran University of Medical Sciences, Shariati Hospital North Kargar Ave. 1411713135, Tehran, Iran.
E-mail: haghghatafshar@razi.tums.ac.ir

CASE REPORT

A 57-year-old male with prior prostatectomy, cystectomy and cecal urinary diversion for invasive prostate cancer, was referred to nuclear medicine department for bone scintigraphy to rule out osseous metastatic disease. He had a rising PSA level in his follow-up assessments. No focal bony lesion was observed; however since the bone scan pattern was suggestive of the superscan, further work-up for metastases was suggested.

An interesting finding was observation of abnormal radiopharmaceutical accumulation throughout the large bowel, which was proved to be due to urinary diversion (Figure 1).

DISCUSSION

A bone scintigraphy is an essential imaging modality to evaluate skeletal diseases. Uptake of bone seeking tracers normally is

seen in the osseous structures and to some degree in the kidneys and bladder. However, there are some reports about extra skeletal uptake in soft tissue structures on bone scans (1). The pathogenesis of this finding is not always apparent. Uptake of bone seeking agents in soft tissue is believed to be due to chemisorption of Tc-99m methylene diphosphonate (Tc-99m MDP) on the surface of calcium salts, including hydroxyapatite crystals (1, 2). Probable mechanisms of increased soft tissue calcium deposition (1, 3) are as follows:

1. Increased ectopic osteoblastic activity.
2. Metastatic calcification (lung, stomach, kidney).
3. Metastases from osteoid forming primary tumors (e.g. osteogenic sarcoma).
4. Increase in calcium binding tissue cations (e.g. iron, magnesium).
5. Dystrophic calcification (e.g. necrosis, hypoxia, tumor, amyloid).

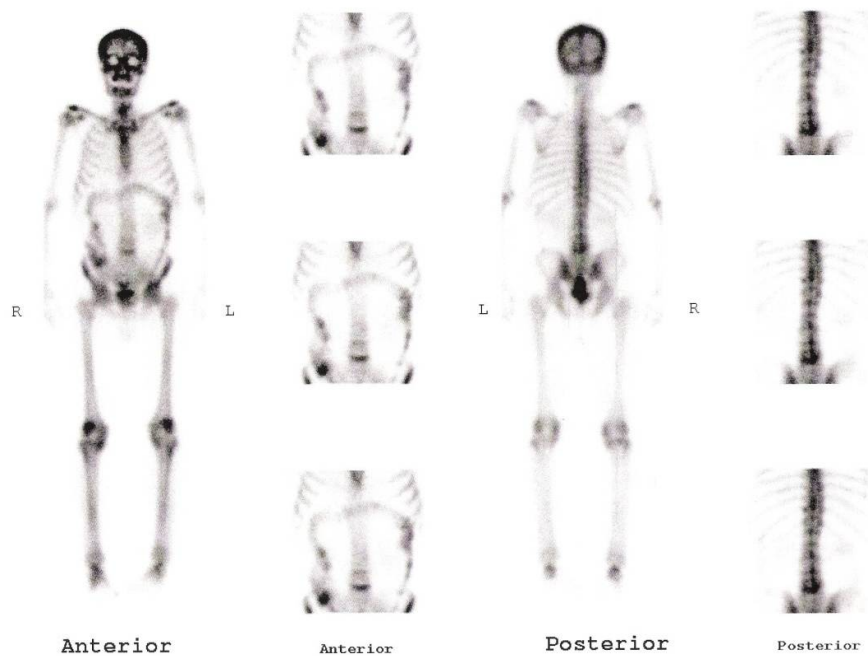


Figure. 1 Superscan indicative of extensive skeletal metastases in a patient with prostatic carcinoma and colon visualization due to cecal urinary diversion

It is important to recognize the specific conditions causing extra skeletal accumulation of bone seeking tracers, because it greatly enhances the diagnostic value of the study. One of the unusual extra skeletal uptake in bone scan is intestinal accumulation of bone seeking tracer (1, 4). Chang et al. (5) have reported a patient with acute colonic diverticulitis who demonstrated abnormal colonic accumulation of tracer in skeletal scintigraphy. These areas of increased activity were attributed to the inflammation of the colonic wall and pericolonic soft tissue. They proposed that Tc-99m MDP may offer an alternative, noninvasive method for the assessment of extent and activity of inflamed colon. McCarthy and Heyman (6) have reported intestinal activity in two neuroblastoma patients. They could not explain the exact mechanism of the intestinal Tc-99m MDP uptake, but proposed that microscopic involvement at the site of the activity or local tumor invasion causing extravasations into the nearby bowel and subsequent transit of the isotope through the bowel might be the reason. Another rare reason of this unusual uptake pattern is oral radioactive urine intake reported in a few cases (7, 8). In these reports, the radioactivity has been described to be depicted in the stomach and gastrointestinal tract. In some countries, drink of infant or one's own urine is thought to be a useful "folk remedy" to improve health and treat some diseases (7). Urinary surgical diversion procedures (9) as in this case, enterovesical fistula (10), gastrointestinal bleeding (11), intestinal infarction (12), previous administration of other imaging agents with normal excretion into the GI tract (e.g. Tc-99m sestamibi) (13) neonatal necrotizing enterocolitis (14), normal intestine in children (15) adenocarcinoma of the colon (16) systemic amyloidosis (17) protein losing enteropathy (18) metastatic calcification (19) primary

intestinal lymphangiectasia (20) minor defect in the quality of the Tc-99m generator (21) chilaiditi's syndrome (a variant of rotation of the colon resulting in interposition of the colon between diaphragm and the liver, with an estimated incidence of less than 3% of the general population) (1, 22) and unknown reasons (1) are reported causes of intestinal accumulation of bone seeking tracers. Ergün et al. (1) has shown that idiopathic Tc-99m MDP uptake can be observed in the intestines in about 1% of bone scans with a prominent localization in the ascending colon. The mechanism of intestinal uptake still could not be fully explained in some of the patients. In our case, the intestinal uptake was prominent only on the anterior projections and cleared or changed in pattern on delayed images indicating that the intestinal Tc-99m MDP accumulation on bone scintigraphy might be an intermittent process and should be included among other well known causes of soft tissue uptake.

REFERENCES

1. Ergün EL, Kiratli PO, Günay EC, Erbaş B. A report on the incidence of intestinal ^{99m}Tc-methylene diphosphonate uptake of bone scans and a review of the literature. *Nucl Med Commun.* 2006;27(11):877-885.
2. Freed JH, Hahn H, Menter R, Dillon T. The use of the three-phase bone scan in the early diagnosis of heterotopic ossification (HO) and in the evaluation of Didronel therapy. *Paraplegia.* 1982;20(4):208-216.
3. Gentili A, Miron SD, Bellon EM. Nonosseous accumulation of bone-seeking radiopharmaceuticals. *Radiographics.* 1990;10(5):871-881.
4. Loutfi I, Collier BD, Mohammed AM. Nonosseous abnormalities on bone scans. *J Nucl Med Technol.* 2003;31(3):149-153; quiz 154-156.
5. Chang WK, Shih WJ, Milan P. Diffusely increased radioactivity in the left abdomen on bone scan of patient with acute colonic CT. *Clin Nucl Med.* 2004;29(9):564-566.

6. McCarthy KE, Heyman S. Diphosphonate intestinal activity seen on two bone images in neuroblastoma. *Clin Nucl Med.* 1986;11(7):501-502.
7. Tsai SC, Kao CH, Lin WY, Wang SJ. Intestinal accumulation of Tc 99m MDP on bone scan. *Semin Nucl Med.* 1999;29(1):80-81.
8. Kosuda S, Katagiri S, Ka WJ, Tominaga S, Kusano S. Demonstration of the ascending colon on Tc-99m MDP skeletal imaging: pitfall in bone scanning by a faith cure of drinking urine. *Clin Nucl Med.* 2000;25(12):1040-1041.
9. Mariani G, Levorato D, Tuoni M, Giannotti P. Incidental imaging of the large bowel in patients with uretero-sigmoidostomy during bone scintigraphy with ^{99m}Tc-pyrophosphate. *J Nucl Med Allied Sci.* 1978;22(3):153-157.
10. Suga K, Ohono Y, Yoneshiro S, Fujita T, Nakanishi T, Utsumi H et al. A case of squamous cell carcinoma of urinary bladder with an ileo-vesical fistula detected on bone scintigraphy. *Kaku Igaku.* 1992;29(1):105-110.
11. Lee VW, Leiter BE, Weitzman F, Shapiro JH. Occult gastric bleeding demonstrated by bone scan and Tc-99m-DTPA renal scan. *Clin Nucl Med.* 1981;6(10):470-473.
12. Barth KH, Alderson PO, Strandberg JD, Strauss HW, White RI Jr. ^{99m}Tc-pyrophosphate imaging in experimental mesenteric infarction: relationship of tracer uptake to the degree of ischemic injury. *Radiology.* 1978;129(2):491-495.
13. Quinn M, Mintun M. Diagnosis: GU-GI fistula; Nuclear medicine cases by study type and diagnosis. <http://gamma.wustl.edu/bs089te183.html> (Accessed 10 January, 2010).
14. Safakianakis G, Ortiz VN, Haase GM. ^{99m}Tc-diphosphonate abdominal imaging in necrotizing enterocolitis: a prospective study. *J Nucl Med* 1978;19:691-692.
15. Conway JJ, Weiss SC, Khentigan J. Gall bladder and bowel localization of bone imaging radiopharmaceuticals [Abstract]. *J Nucl Med* 1979;20:622.
16. Dowe DA, Johnston TA, Showers TL, Kasper JF, Salzman AJ. Tc-99m MDP uptake in stage D adenocarcinoma of the colon. *Clin Nucl Med.* 1998;23(9):620.
17. Janssen S, van Rijswijk MH, Piers DA, de Jong GM. Soft-tissue uptake of ^{99m}Tc-diphosphonate in systemic AL amyloidosis. *Eur J Nucl Med.* 1984;9(12):538-541.
18. Roach PJ, Itrato D, Treves ST. Bowel visualization on bone scan because of protein losing enteropathy. *Clin Nucl Med.* 1994;19(12):1114-1116.
19. Stabler J. Case report: Case report: ossifying metastases from carcinoma of the large bowel demonstrated by bone scintigraphy. *Clin Radiol.* 1995;50(10):730-731.
20. Lee KH, Chung JK, Lee DS, Lee MC, Song IS, Koh CS. Intestinal leakage of technetium-99m-MDP in primary intestinal lymphangiectasia. *J Nucl Med.* 1996;37(4):639-641.
21. Sherkow L, Ryo UY, Fabich D, Patel GC, Pinsky SM. Visualization of the liver, gallbladder, and intestine on bone scintigraphy. *Clin Nucl Med.* 1984;9(8):440-443.
22. Campana L. What is your roentgen diagnosis? Hepatodiaphragmatic interposition of the right colonic flexure, Chilaiditi syndrome in dolichocolon. *Schweiz Rundsch Med Prax.* 1992;81(25):813-814.