



Case Report

Detection of osseous metastasis by [⁶⁸Ga]Ga-FAPI PET/CT in a thyroid cancer patient with elevated thyroglobulin and negative radioiodine scintigraphy

Atena Aghaee¹, Somayeh Barashki¹, Amir Hossein Jafarian², Seyed Rasoul Zakavi¹, Hassan Kamali³, Nasim Norouzbeigi⁴, Kamran Aryana¹

¹Nuclear Medicine Research Center, Mashhad University of Medical Sciences, Mashhad, Iran

²Department of Pathology, Ghaem Hospital, Mashhad University of Medical Sciences, Mashhad, Iran

³Chemistry Department, Kharazmi University, Tehran, Iran

⁴Nuclear Medicine Department, Razavi Hospital, Mashhad, Iran

ARTICLE INFO

Article History:

Received: 14 June 2022

Revised: 06 November 2022

Accepted: 08 November 2022

Published Online: 28 November 2022

Keyword:

[⁶⁸Ga]Ga-FAPI PET/CT

TENIS syndrome

[¹⁸F]FDG PET/CT

Differentiated thyroid cancer

ABSTRACT

Thyroglobulin elevated-negative iodine scintigraphy (TENIS) differentiated thyroid cancer (DTC) patients are a subgroup of DTC patients with almost rapid disease progression and reduced overall survival and them usually do not have an effective treatment modality. Surgery and metastatectomy is the best option for recurrent disease in cases of solitary or oligometastasis. Detection of the metastatic sites is of utmost importance in these patients. We present a patient with TENIS syndrome and negative [¹⁸F]FDG PET/CT and [⁶⁸Ga]Ga-DOTATATE whole body PET/CT scan in whom just [⁶⁸Ga]Ga-FAPI PET/CT helped in localizing the metastatic lesion to the iliac bone and subsequently the bone metastasis was resected and the pathology report confirmed the diagnosis.

*Corresponding Author:

Kamran Aryana, MD


Address: Nuclear Medicine Research Center, Mashhad University of Medical Sciences, Mashhad, Iran

Email: aryanak@mums.ac.ir

Use your device to scan and read the article online



How to cite this article: Aghaee A, Barashki S, Jafarian AH, Zakavi SR, Kamali H, Norouzbeigi N, Aryana K. Detection of osseous metastasis by [⁶⁸Ga]Ga-FAPI PET/CT in a thyroid cancer patient with elevated thyroglobulin and negative radioiodine scintigraphy. Iran J Nucl Med. 2023;31(1):109-111.

 <https://doi.org/10.22034/IRJNM.2022.40051>

CASE PRESENTATION

A 46-year-old patient with history of multifocal differentiated thyroid cancer (DTC) underwent total thyroidectomy 4 years ago (T1bN0M0) and thyroid remnant ablation was performed with ^{131}I activity of 1.11GBq (30 mCi). During follow-up, the patient's thyroglobulin reached 499 ng/ml with doubling time of 4.4 months, despite no remarkable symptoms. Her tumoral cells has lost iodine avidity after two high

doses (5.55 GBq) of ^{131}I therapy which was confirmed by negative post ablation scan (Figure 1A). Her chest HRCT showed nothing other than a small (4 mm) benign looking pulmonary nodule. So, she was a candidate for $[^{18}\text{F}]\text{FDG}$ PET/CT scan according to the present guidelines and the scan showed unremarkable findings (Figure 1B). $[^{68}\text{Ga}]\text{Ga-DOTATATE}$ whole body PET/CT scan was also performed which had unremarkable results, too (Figure 1C).

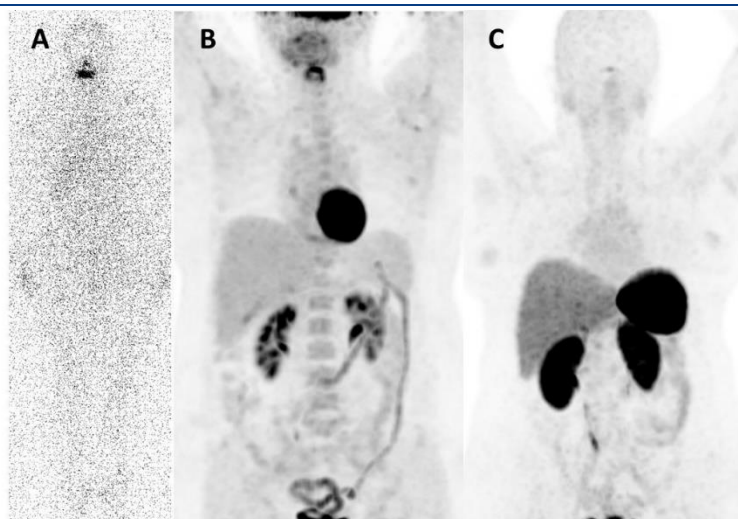


Fig 1. Whole body radio-iodine scan (A), $[^{18}\text{F}]\text{FDG}$ PET/CT scan (B) and whole body $[^{68}\text{Ga}]\text{Ga-DOTATATE}$ scan (C) of the patient

This patient was our first thyroglobulin elevated-negative iodine scan (TENIS) DTC case who underwent $[^{68}\text{Ga}]\text{Ga-FAPI}$ PET/CT and revealed a lesion in the right iliac bone with mild activity (SUVmax=2.9), associated with corresponding lytic lesion on CT slices (blue arrows) (Figures 2A-2D). Subsequent pelvic MRI confirmed a metastatic lesion in the right iliac bone adjacent to the right

sacroiliac joint (blue arrow) (Figures 2E-2G). Surgery was done and Hematoxylin and Eosin (H&E) slides of the resected lesion show osseous tissue involved by metastatic carcinoma composed cuboid cells with trabecular and glands and follicles contain colloid. This appearance confirms metastatic lesion from thyroid origin (Figures 2H-2J).

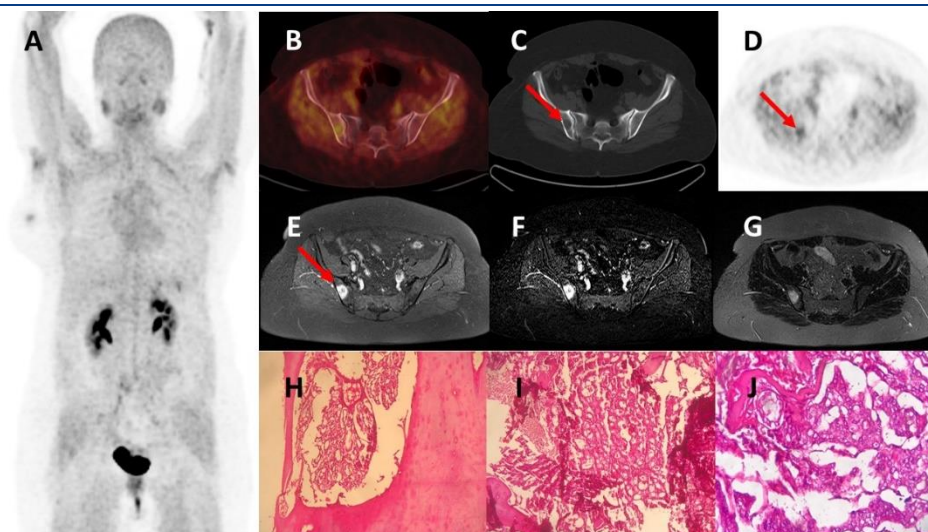


Fig 2. Whole body $[^{68}\text{Ga}]\text{Ga-FAPI}$ PET/CT scan (A), transaxial PET/CT (B), CT (C) and PET only (D) images from a metastatic lesion (blue arrows) in the right sacroiliac region. E, F and G images are MRI sequences of the same region. H, I and J images show the histopathology of the resected metastasis

DISCUSSION

FAP (fibroblast activating protein) is usually overexpressed in cancer-associated fibroblasts of a variety of tumors. Recent development of agents targeting these cytoplasmic proteins like FAPI (fibroblast activating protein inhibitor) has attracted nuclear physicians to introduce a novel theragnostic agent [1, 2]. TENIS DTC patients are a subgroup of DTC patients with almost rapid disease progression and reduced overall survival and they usually do not have an effective treatment modality [3, 4]. If FAPI avidity be documented in this group of patients, it would be a suitable treatment modality to administer [¹⁷⁷Lu]Lu-FAPI, with probably less toxicity than other therapeutic modalities remained, like tyrosine kinase inhibitors (TKIs) [5-8].

CONCLUSION

We present a patient with TENIS syndrome and negative [¹⁸F]FDG PET/CT and [⁶⁸Ga]Ga-DOTATATE whole body PET/CT scan in whom just [⁶⁸Ga]Ga-FAPI PET/CT helped in localizing the metastatic lesion to the iliac bone and subsequently the bone metastasis was resected and the pathology report confirmed the diagnosis.

REFERENCES

1. Kratochwil C, Flechsig P, Lindner T, Abderrahim L, Altmann A, Mier W, Adeberg S, Rathke H, Röhrich M, Winter H, Plinkert PK. ⁶⁸Ga-FAPI PET/CT: tracer uptake in 28 different kinds of cancer. *J Nucl Med.* 2019 Jun 1;60(6):801-5.
2. Treglia G, Muoio B, Roustaei H, Kiamanesh Z, Aryana K, Sadeghi R. Head-to-Head Comparison of Fibroblast Activation Protein Inhibitors (FAPI) Radiotracers versus [¹⁸F] F-FDG in Oncology: A Systematic Review. *Int J Mol Sci.* 2021 Oct 17;22(20):11192.
3. Silberstein EB. The problem of the patient with thyroglobulin elevation but negative iodine scintigraphy: the TENIS syndrome. *Semin Nucl Med.* 2011 Mar 1;41(2):113-20
4. Sfar R, Kamoun T, Noura M, Regaieg H, Ammar N, Charfi H, Bahloul A, Fredj MB, Chatti K, Guezguez M, Essabbah H. Differentiated thyroid cancer with thyroglobulin elevation and negative iodine scintigraphy (TENIS syndrome). *Int J Otorhinolaryngol Head Neck Surg.* 2014 Jun 27;3: 149-53
5. Fu H, Fu J, Huang J, Pang Y, Chen H. ⁶⁸Ga-FAPI PET/CT versus ¹⁸F-FDG PET/CT for detecting metastatic lesions in a case of radioiodine-refractory differentiated thyroid cancer. *Clin Nucl Med.* 2021 Nov 1;46(11):940-2.
6. Fu H, Fu J, Huang J, Su X, Chen H. ⁶⁸Ga-FAPI PET/CT in thyroid cancer with thyroglobulin elevation and negative iodine scintigraphy. *Clin Nucl Med.* 2021 May 1;46(5):427-30.
7. Jois B, Asopa R, Basu S. Somatostatin receptor imaging in non-¹³¹I-avid metastatic differentiated thyroid carcinoma for determining the feasibility of peptide receptor radionuclide therapy with ¹⁷⁷Lu-DOTATATE: low fraction of patients suitable for peptide receptor radionuclide therapy and evidence of Chromogranin a level-positive neuroendocrine differentiation. *Clin Nucl Med.* 2014 Jun 1;39(6):505-10.
8. Laursen R, Wehland M, Kopp S, Pietsch J, Infanger M, Grosse J, Grimm D. Effects and role of multikinase inhibitors in thyroid cancer. *Curr Pharm Des.* 2016 Nov 1;22(39):5915-26.