

The Value of Myocardial Perfusion Imaging with Tc-99m MIBI for the Prediction of Perfusion Improvement after Percutaneous Transluminal Coronary Angioplasty

Armaghan Fard-Esfahani¹, Babak Fallahi¹, Abbas Mohagheghi², Majid Assadi¹, Davood Beiki¹, Mohammad Eftekhari¹, Mohsen Saghari¹, Abbas Takavar¹

¹Research Institute for Nuclear Medicine, Tehran University of Medical Sciences
²Department of Cardiology, Shariati Hospital, Tehran University of Medical Sciences, Tehran, Iran.

(Received 13 September 2009, Revised 11 November 2009, Accepted 21 November 2009)

ABSTRACT

Introduction: Percutaneous transluminal coronary angioplasty (PTCA) is an effective method for revascularizing of stenotic coronary vessels. Lack of response to this treatment, either in symptomatic or asymptomatic patients, is usually due to incomplete revascularization, restenosis, and/or irreversibility of myocardial perfusion. Introduction of a noninvasive method with high predictive value for diagnosis of reversibility in ischemic myocardium is of high importance to determine the patients who will benefit from PTCA.

Methods: Sixty patients with one or two vessel disease, who were candidates for PTCA and had a successful PTCA (proved by post- revascularization angiography), enrolled the study. For all patients myocardial perfusion imaging (MPI) was performed before PTCA in stress and rest phases. MPI was repeated in stress and rest phases within 6 months after PTCA. The predictive values of pre-PTCA scan for the diagnosis of reversibility and prediction of perfusion improvement after PTCA were evaluated.

Results: Perfusion improvement after PTCA was noted in 52 of 60 patients (86.7%). The positive predictive value of pre-intervention MPI for diagnosis of reversibility was 94.3% and the corresponding negative predictive value was 71.4%.

Conclusion: Myocardial perfusion imaging may play an important role for accurate prediction of perfusion improvement after percutaneous transluminal coronary angioplasty.

Keywords: Angioplasty, PTCA, Myocardial perfusion imaging, Restenosis, Viability

Iran J Nucl Med 2010;18(1):7-13

Corresponding author: Dr Babak Fallahi, Research Institute for Nuclear Medicine, Shariati Hospital, North Kargar Ave., Tehran, Iran.
E-mail: bfallahi@sina.tums.ac.ir

INTRODUCTION

Percutaneous transluminal coronary angioplasty (PTCA) is an evolving procedure undertaken for therapeutic purposes in coronary artery disease. The most common indication for cardiac catheterization today consists of a patient with an acute coronary ischemic syndrome (unstable angina or acute MI) in whom an invasive therapeutic intervention is contemplated. The goal of cardiac catheterization in such patients is to identify culprit lesions and then to restore vessel patency via PTCA (1).

Because 40-60% of angiographically detected stenotic lesions are of uncertain significance, myocardial perfusion scintigraphy (MPI) can stratify risk and assess which patients require revascularization. Those patients with no ischemia have low risk for cardiac events, even with left main or three-vessel disease on angiography. In ischemic patients, successful intervention results in the elimination of transient defects caused by stress induced ischemia. After PTCA symptoms status and exercise ECG are unreliable indicators of restenosis. Of patients with recurrent chest pain within a month of intervention, 30% have restenosis. Because ischemia (painful or silent) worsens prognosis, a noninvasive test with a high predictive value such as MPI is needed to reduce the need for unnecessary coronary interventions (2).

Controversy exists regarding the diagnostic accuracy, optimal technique, and timing of noninvasive stress testing after percutaneous transluminal coronary angioplasty (PTCA). Studies have shown that the sensitivity and specificity of stress testing varies depending on the amount of time elapsed since the procedure. Soon after a successful PTCA, perfusion defects on nuclear imaging following exercise or pharmacologic stress may be detected in asymptomatic patients without angiographic restenosis. In many

patients, abnormal stress myocardial perfusion scans will normalize spontaneously, and thus stress testing with nuclear imaging within 4 to 6 weeks of PTCA lacks specificity for detecting restenosis (3). However in another study, from the total number of 53 patients, 36 patients (61%) showed an improvement in myocardial perfusion immediately (1-6 days) after PTCA (4). Miller has suggested that 2 to 4 weeks after procedurally successful coronary angioplasty is an appropriate time for myocardial perfusion imaging and can document improved cardiac functional capacity and reduced ECG and imaging evidence of myocardial ischemia (5). Also MPI can be used for diagnosis of late restenosis (3-9 months after PTCA). By using myocardial perfusion scintigraphy the sensitivity will improve from 76% to 94% and specificity will improve from 46% to 84% (6).

Comparing exercise electrocardiography with MPI in detecting restenosis after successful PTCA, the approximated accuracy of the exercise electrocardiography was less than MPI (62% versus 82%) (7).

This study was performed to evaluate myocardial perfusion imaging for prediction of perfusion improvement after PTCA. Also results of different time intervals after PTCA were compared.

METHODS

Study population

We studied 60 patients (50 men and 10 women; age range, 34-75; median, 54 yrs) who were candidates for PTCA, and performed MPI before (pre-PTCA) and after angioplasty (post-PTCA). This study was approved by ethics committee of Tehran University of Medical Sciences, and all subjects signed an informed consent form based on the guidelines of this committee before participation in the study.

Patients were included in the study if they had coronary artery stenosis confirmed by angiography, had undergone successful PTCA confirmed by immediate post angioplasty angiography, and had undergone a third angiography within 6 months after PTCA to evaluate the outcome of this procedure.

Angioplasty was considered successful if more than 50% dilatation of the lumen diameter was achieved and no major complication (acute obstruction of dilated vessels or myocardial infarction) was present.

Myocardial scintigraphy

A two day stress/rest MPI protocol was performed on all patients, using weight – adjusted doses of 10 MBq/kg (at least 700 MBq of Tc-99m methoxyisobutylisonitrile) at peak pharmacologic stress and the same amount at rest on the following day. Pharmacologic stress was obtained by intravenous infusion of 0.56 mg per kilogram of body weight of dipyridamole in 20 ml normal saline over 5 minutes under electrocardiographic monitoring, and Tc-99m MIBI was administered 4 minutes later. Imaging was done 30 minutes later. Rest study was performed on the following day by the same protocol, but imaging was performed 45 minutes following radiopharmaceutical injection after having a light fat meal.

SPECT protocol

Images were obtained over a 180° orbit from right anterior oblique 45° to left posterior oblique 45° using a single-head γ -camera (Argus, ADAC, USA) equipped with high-resolution collimator. Acquisition was performed in 32 steps at 30 seconds per step using the step- acquisition mode. For image acquisition, a 20% acceptance window around the 140 keV photopeak was used. A 64x64 matrix was used for all studies. All raw data were reanalyzed for the study. The

projection datasets were prefiltered using a Butterworth filter and reconstructed using filtered backprojection. The raw data were reconstructed for all studies by a technologist experienced in nuclear cardiology.

Scan interpretation

The scans were interpreted on the basis of 17 segment model (Figure 1). Images were interpreted visually by 2 experienced observers, who reached a consensus on the findings. The observers were unaware of angiography.

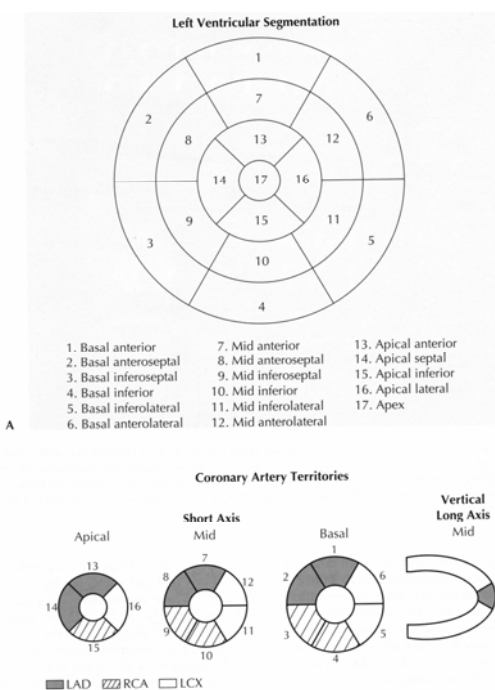


Figure 1. 17 segment model of myocardium corresponding to coronary arteries territory for interpretation of myocardial perfusion images.

Ischemia or reversible perfusion defect was defined as two or more segmental perfusion defects in the pre-PTCA stress phase scan, which shows filling-in (more uptake) in the rest phase study. Scar tissue or irreversible perfusion defect is defined as two or more

segments with perfusion defect in the pre-PTCA stress phase scan which shows no change in size or amount of uptake (perfusion score) in the rest phase scan.

Perfusion improvement after PTCA is defined as the status in which extent or severity of a perfusion defect in a specific segment in the pre-PTCA stress phase scan is reduced in the post-PTCA stress phase scan. No perfusion improvement is the status in which the extent or severity of a perfusion defect in a specific segment in the pre-PTCA stress phase scan either shows no change or even increases in the stress phase post-PTCA scan.

To correlate MPI results with angiography, perfusion defects were allocated to coronary arteries according to the coronary perfusion pattern. Defects in the anterior wall and septal region were allocated to the left anterior descending artery (LAD); defects in the lateral wall, to the left circumflex coronary artery (LCX); and inferior defects, to the right coronary artery (RCA). Apical defects were considered to be in the LAD region, unless the defect extended to the lateral (LCX) or inferior (RCA) wall. In the watershed regions the extension of a defect to the anterior, lateral or inferior wall was decisive for the allocation of a coronary artery to the vascular bed. Furthermore, distinct defects affecting both the LAD region and the LCX region were rated as left main artery (LM) disease.

Angiographic evaluation

Coronary angiography was performed according to standard criteria. The coronary angiographic findings were analyzed visually by cardiologists who were unaware of MPI results. Coronary artery disease was defined as $\geq 50\%$ increase in lumen diameter.

Statistical analysis

Statistical analysis was performed using SPSS ver.13. True positive (TP) of

reversibility in pre-PTCA scan is defined as having reported at least two segments as ischemic (reversible perfusion defect) showing perfusion improvement in terms of severity or extent (perfusion score) in post-PTCA scan. False positive (FP) of reversibility is defined as having reported at least two segments with reversible perfusion defect in the pre-PTCA scan revealing no improvement after PTCA. True negative (TN) is denoted as no reversible defects in the pre-PTCA scan and no change in the number of defective segments in post-PTCA scan. False negative (FN) test result is applied for those cases without reversible defects in the pre-PTCA scan, but at least two segments with perfusion improvement in post-PTCA scan.

To compare the change of the number of segments with ischemia (reversible), fixed (irreversible) and normal pattern, before and after PTCA, Wilcoxon signed rank test was used. The results were considered significant with $p < 0.05$.

RESULTS

Interpreting the scans by 17 segment model, all the pre-PTCA scans showed segments with myocardial perfusion defects. Evaluation of perfusion pattern in the territory of dilated vessels by angioplasty showed a mean of 1.33 segments with fixed lesion, 2.30 segments with ischemic lesion and 2.30 segments with normal pattern in each patient. Post-PTCA myocardial perfusion scintigraphy showed complete normalization of scan pattern in 11 (18.3%) and reduction of segmental perfusion defects in 41 patients (68.3%). The number of normal segments before and after PTCA was analyzed by Wilcoxon signed rank test, which showed statistically significant difference ($p < 0.0001$). Also the number of both reversible and fixed segments showed decrease in post-PTCA scans compared to pre-PTCA ones ($p < 0.0001$).

From 16 patients in whom the second scan was performed 6-10 days after PTCA, 12 (75%) showed improvement in myocardial perfusion. Using pre-PTCA scan as a test for the prediction of perfusion reversibility after PTCA, the number of cases with TP, TN, FP and FN test results were 50, 5, 3 and 2, respectively.

Only 2 from 7 cases (28.6%) with irreversible defects on pre-PTCA scan showed an improvement in myocardial perfusion after PTCA while the rate of perfusion improvement in patients with reversible defect on pre-PTCA scan was 94.3% (50 from 53).

DISCUSSION

In this study, myocardial flow was assessed before and after PTCA by myocardial perfusion scan. In all patients, myocardial perfusion defects had been noted in the territory of dilated vessels. MPI is highly accurate in diagnosis of coronary artery disease (2) and it is shown that in cases with coronary artery stenosis of more than 70%, scintigraphic image shows perfusion defects with high accuracy (8).

PTCA is a well-known effective interventional method in treatment of coronary artery disease. A retrospective analysis on 421 patients, revealed patients with extensive lesions who underwent this interventional treatment, showed significant improvement in myocardial perfusion (9). However, there are evidences that in early first weeks after PTCA, false remaining defects might be seen, so repeat of a scan in first weeks after interfering treatment may result in inaccurate estimation of ischemia and an abnormal myocardial perfusion scan soon after PTCA does not necessarily reflect residual coronary stenosis or recurrence (4,10,11,12,13). However, the optimal time for imaging after PTCA is not well determined. Depuoy suggests that studies performed 6 weeks or more after angioplasty accurately detect early

restenosis and may identify those individuals likely to become symptomatic and eventually develop restenosis in the future (10).

In our study, 16 patients in whom the second scan was performed 6-10 days after PTCA, showed 75% improvement in myocardial perfusion. In another study immediately after PTCA (6-10 days), an improvement in myocardial perfusion was noted in 36 patients (61%) (4). On the other hand on Stuckey et al study, only 9% positive scans for silent ischemia 2 weeks after PTCA was observed (14). According to the data of another report, no significant difference in the rate perfusion improvement was noted between the groups of patients scanned 6-10 days, 1-3 months and 3-6 months after PTCA (15).

The main objective of this study was to assess the scan capability in the prediction of perfusion improvement after treatment. The noteworthy point is that in some cases the pre-PTCA scan shows an irreversible fixed perfusion defect, but after treatment this shows improvement. These cases can lead to incorrect overestimation of irreversible area in patients with coronary artery stenosis. The rate of patients with incorrect diagnosis of perfusion irreversibility on pre-PTCA scan was 28.6% in our study. De Puey et al have reported a probable reversible hibernation status induced by chronic ischemia (10). This phenomenon can appear as a fixed or irreversible defect in the pretreatment scan, although the myocardial muscle in this area is in fact viable and is potentially improvable after treatment. Also the same finding is reported by Eichorn et al (16). Fioretti et al also have presented decrease in fixed segments after bypass surgery (17), which backs up our finding.

On the other hand sometimes there is such a severe metabolic involvement in the area of reversible ischemia that even after revascularization of the region, perfusion is not completely restored. Hence, it seems

that determination of diagnostic value of myocardial perfusion scan in the prediction of reversibility and perfusion improvement is of particular importance for cardiologists. Quantitative studies are used to evaluate scintigraphy statistically in this regard.

PTCA is currently performed by dilatation and stenting on the culprit vessel. However, whether stenosis in other vessels is of importance or not, and does revascularization of these vessels results in myocardial perfusion improvement, are still questions to be answered.

White et al compared coronary angiography data with physiologic measuring of coronary blood flow in stenotic area and showed except for severe stenosis (>90%), or very mild stenosis (<10%), estimation of stenosis severity by angiography is not properly accurate (18). So a diagnostic method which can show the significance of stenosis and determines potential for reversibility of myocardium after PTCA before intervention seems to be necessary. On the basis of present study, myocardial perfusion scan with Tc-99m MIBI has a very high predictive value in the prediction of perfusion reversibility after PTCA, but sestamibi scintigraphy is not so appropriate in accurate prediction of perfusion irreversibility after intervention.

CONCLUSION

Myocardial perfusion imaging not only has an important role for determining the significance of coronary stenosis, but also may play an important role for accurate prediction of perfusion improvement after PTCA.

ACKNOWLEDGEMENT

This research has been supported by Tehran University of Medical Sciences, grant no 2090.

REFERENCES

1. Baim DS. Grossman's Cardiac Catheterization, Angiography, and Intervention. 7th ed, Philadelphia, PA: Lippincott, Williams & Wilkins; 2006:5.
2. Ziessman HA, O'Malley JP, Thrall JH. Nuclear Medicine: The Requisites. 3rd ed. Philadelphia, PA: Mosby, 2006;450-507.
3. Rosanio S, Tocchi M, Stouffer GA. Use of stress testing to evaluate patients with recurrent chest pain after percutaneous coronary revascularization. *Am J Med Sci.* 1998;316(1):46-52.
4. Kostkiewicz M, Jarosz W, Tracz W, Przewlocki T, Pieniazek P, Podolec P et al. Thallium-201 myocardial perfusion imaging in patients before and after successful percutaneous transluminal coronary angioplasty. *Int J Cardiol.* 1996;53(3):299-304.
5. Miller DD, Verani MS. Current status of myocardial perfusion imaging after percutaneous transluminal coronary angioplasty. *J Am Coll Cardiol.* 1994;24(1):260-266.
6. DePuey EG, Roubin GS, Cloniger KG, King SB, Garcia EV, Robbins WL et al. Correlation of transluminal coronary angioplasty parameters and quantitative thallium-201 tomography. *J invasive cardiol.* 1998;1:40-50.
7. Dori G, Denekamp Y, Fishman S, Bitterman H. Exercise stress testing, myocardial perfusion imaging and stress echocardiography for detecting restenosis after successful percutaneous transluminal coronary angioplasty: a review of performance. *J Intern Med.* 2003;253(3):253-262.
8. Fioretti PM, Pozzoli MMA, Ilmer B, Salustri A, Cornel JH, Roelandt JRTC et al: Exercise echocardiography versus thallium-201-SPECT for assessing patients before and after. PTCA. *Eur Heart J* 1992;13:213-219.
9. Berman DS, Kang X, Schisterman EF, Gerlach J, Kavanagh PB, Areeda JS et al. Serial changes on quantitative myocardial perfusion SPECT in patients undergoing revascularization or conservative therapy. *J Nucl Cardiol.* 2001;8(4):428-437.
10. DePuey EG. Myocardial perfusion imaging with thallium-201 to evaluate patients before and after percutaneous transluminal coronary angioplasty. *Circulation.* 1991;84(3 Suppl):I59-65.

11. Rosanio S, Tocchi M, Stouffer GA. Use of stress testing to evaluate patients with recurrent chest pain after percutaneous coronary revascularization. *Am J Med Sci.* 1998;316(1):46-52.
12. Manyari DE, Knudtson M, Kloiber R, Roth D. Sequential thallium-201 myocardial perfusion studies after successful percutaneous transluminal coronary artery angioplasty: delayed resolution of exercise-induced scintigraphic abnormalities. *Circulation.* 1988;77(1):86-95.
13. Breisblatt WM, Weiland FL, Spaccavento LJ. Stress thallium-201 imaging after coronary angioplasty predicts restenosis and recurrent symptoms. *J Am Coll Cardiol.* 1988;12(5):1199-1204.
14. Stuckey TD, Burwell LR, Nygaard TW, Gibson RS, Watson DD, Beller GA. Quantitative exercise thallium-201 scintigraphy for predicting angina recurrence after percutaneous transluminal coronary angioplasty. *Am J Cardiol.* 1989;63(9):517-521.
15. Fard-Esfahani A, Assadi M, Saghari M, Mohagheghie A, Fallahi B, Eftekhari M, Beiki D et al. The role of myocardial perfusion imaging in the evaluation of patients undergoing percutaneous transluminal coronary angioplasty. *Hellenic J Cardiol.* 2009;50(5):396-401.
16. Eichhorn EJ, Konstam MA, Salem DN, Isner JM, Deckelbaum L, Stransky NB. Dipyridamole thallium-201 imaging pre- and post-coronary angioplasty for assessment of regional myocardial ischemia in humans. *Am Heart J.* 1989;117(6):1203-1209.
17. Fioretti P, Reijs AE, Neumann D, Taams M, Kooij PP, Bos E et al. Improvement in transient and 'persistent' perfusion defects on early and late post-exercise thallium-201 tomograms after coronary artery bypass grafting. *Eur Heart J.* 1988;9(12):1332-1338.
18. White CW, Wright CB, Doty DB, Hiratza LF, Eastham CL, Harrison DG et al. Does visual interpretation of the coronary arteriogram predict the physiologic importance of a coronary stenosis? *N Engl J Med.* 1984;310(13):819-824.