

Rare case of squamous cell carcinoma of buccal mucosa metastasizing to interventricular septum in a young adult detected by ¹⁸F-FDG PET-CT

GS Shagos, S Padma, P Shanmuga Sundaram, Anshu Tewari

Department of Nuclear Medicine & PET/CT, Amrita Institute of Medical Sciences,
Cochin, Kerala, India

Case Report

(Received 6 August 2013, Revised 12 December 2013, Accepted 14 December 2013)

ABSTRACT

Metastatic tumors to the heart unlike primary cardiac tumors are not rare. Despite its frequency, cardiac metastasis is commonly detected only during autopsy as the symptoms of disseminated metastasis prevail over symptoms caused by cardiac metastasis and hence is overlooked most of the time. Tumors more commonly found metastasizing to the heart are malignancies of lung, breast, esophagus, lymphoma, leukemia, and malignant melanoma. Head and neck malignancies have a lower incidence of distant metastasis when compared to other malignancies and it rarely causes cardiac metastasis. Here we report the case of a 32 year old Indian male with squamous cell carcinoma of buccal mucosa who underwent surgery followed by chemoradiation. Follow up, FDG PET-CT showed extensive lymphnodal, pulmonary & skeletal metastasis apart from local recurrence in the tongue and floor of mouth. Another discrete foci of increased FDG uptake was noted in the region of heart which corresponded to a hypodense foci in the interventricular septum in contrast enhanced CT raising the possibility of cardiac metastasis. Subsequently, 2D echocardiogram with parasternal long axis view showed hyperdense anterior septum with speckled appearance with a hyperechoic structure attached to the septum towards the right ventricular side confirming metastatic deposit to the heart.

Key words: ¹⁸F-FDG PET-CT; Buccal mucosa; Cardiac metastasis; Interventricular septum

Iran J Nucl Med 2014;22(2):94-97

Published: June, 2014

<http://irjnm.tums.ac.ir>

Corresponding author: Dr Shagos GS, Department of Nuclear Medicine & PET/CT, Amrita Institute of Medical Sciences, Cochin-6802041, Kerala, India. E-mail: shagosgs@aims.amrita.edu

INTRODUCTION

Cardiac tumors can be primary or secondary. Primary tumors of the heart are rare, the frequency being approximately 0.02% in pooled autopsy series [1]. Metastatic tumors to the heart are at least 100 times higher in frequency than primary tumors [2] and is detected at autopsy in about 10-12 % of all patients with malignancies [3, 4]. Majority of the primary cardiac tumors are intracavitary whereas metastatic tumors of the heart are seldom intracavitary and hence most of them go unrecognized unless the patient presents with overt clinical signs and symptoms of cardiac arrhythmia, outflow tract obstruction or heart failure. Although any malignant neoplasm can metastasize to heart, the tumors that are more prone to cause metastasis to the heart are carcinomas of the lung, breast, esophagus, lymphoma, leukemia, and malignant melanoma [5]. The postulated mechanisms by which cardiac metastasis occur are [1] by direct extension, [2] through the blood stream, [3] through lymphatic system [4] and by intracavitary diffusion either through inferior vena cava or the pulmonary veins [6]. Metastasis to the heart can involve epicardium, myocardium or endocardium, though the commonest site to be affected is epicardium.

CASE REPORT

Here we present the case of a 32 year old Indian male, a diagnosed case of squamous cell carcinoma of buccal mucosa, who had undergone wide local excision of the primary tumor along with partial maxillectomy, segmental mandibulectomy, neck dissection with radial forearm free flap reconstruction. Surgery was followed by chemoradiation. An FDG PET scan was requested to know the extent of the disease as cervical lymphnodal recurrence was suspected. Whole body FDG-PET CT scan showed extensive metastasis in the form of multiple lymphnodal, pulmonary & skeletal metastasis apart from local recurrence in the tongue and floor of mouth (Figure 1). Transaxial PET images (Figure 2a) at the cardiac level showed discrete foci of abnormal increased FDG uptake in the region of heart (SUV Max 6.7). Abnormal foci of increased FDG uptake can also be noted in bilateral lung fields. Interestingly, the overall uptake in rest of the myocardium is seen to be on the lower side. Corresponding contrast enhanced CT images (Figure 2b) showed a hypodense foci in the interventricular septum. Patchy and nodular areas of consolidation can also be seen in the right lower lobe and in left lower lobe. Fused PET-CT images (Figure 2c) confirmed that the discrete intense FDG uptake in the heart (SUV Max 6.4) corresponded to the CT

detected hypodense foci in the interventricular septum.

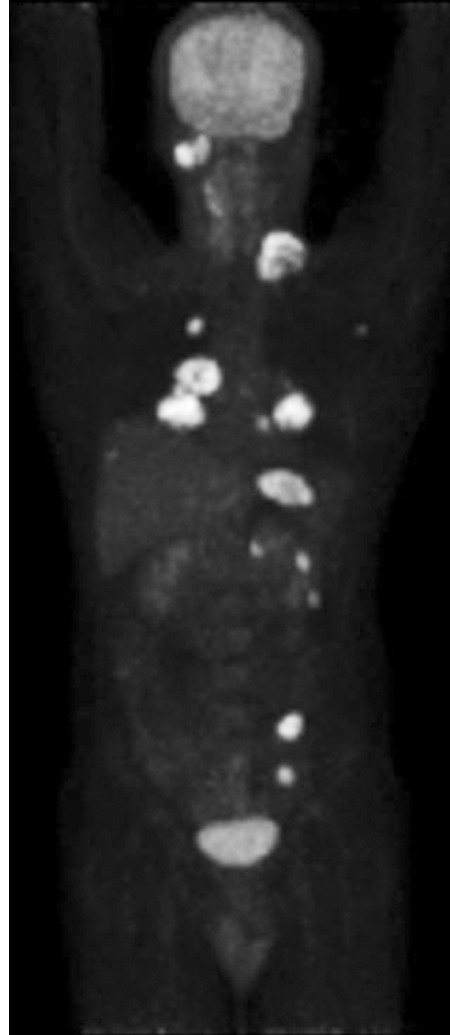

Fig 1. whole-body maximum-intensity projection images showing extensive metastasis in the form of multiple lymphnodal & bilateral pulmonary metastasis.

A 2D echocardiogram of the heart was done subsequently. Parasternal long axis view in 2D echo showed hyperdense anterior septum with speckled appearance. A hyperechoic structure was seen attached to the septum towards the right ventricular side (Figure 3).

DISCUSSION

Cardiac metastasis is an incidental finding in majority of the patients and is picked up during a radiological investigation following chemotherapy or radiotherapy.

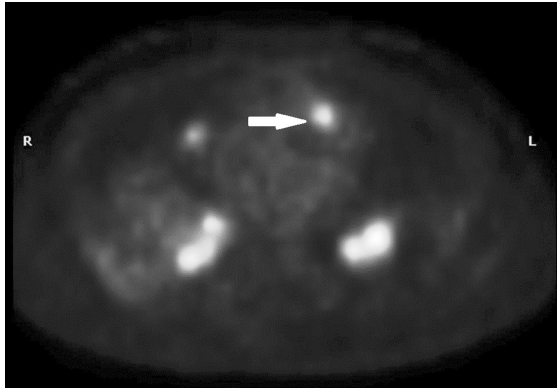


Fig 2a. Transaxial PET images at the cardiac level showing a discrete foci of increased FDG uptake (SUV Max 6.4) in the region of heart. Multiple foci of abnormally increased FDG uptake can also be noted in bilateral lung fields. Overall myocardial FDG uptake is seen to be on the lower side.

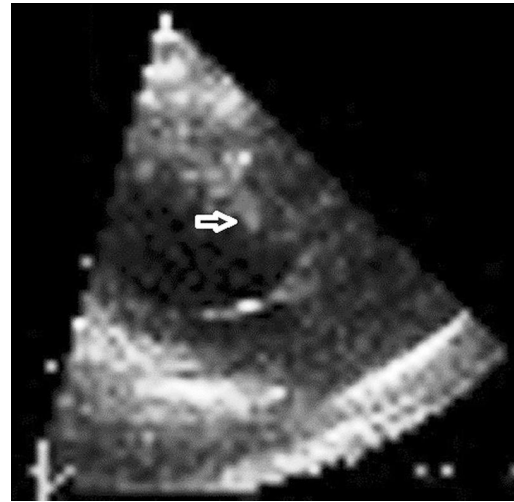


Fig 3. Parasternal long axis view in 2D echo showed hyperdense anterior septum with speckled appearance. A hyperechoic structure was seen attached to the septum towards the right ventricular side.

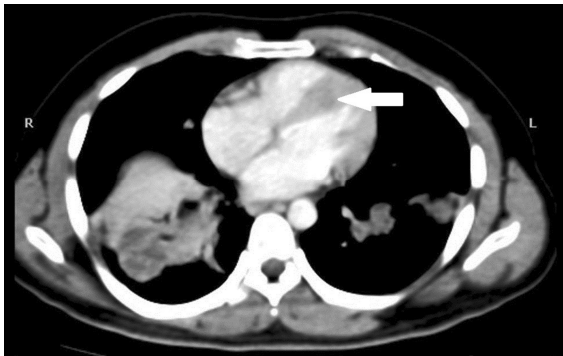

Fig 2b. Transaxial CECT images at the cardiac level showing a discrete hypodense foci in the interventricular septum. Patchy and nodular areas of consolidation can also be seen in the right lower lobe and in left lower lobe.

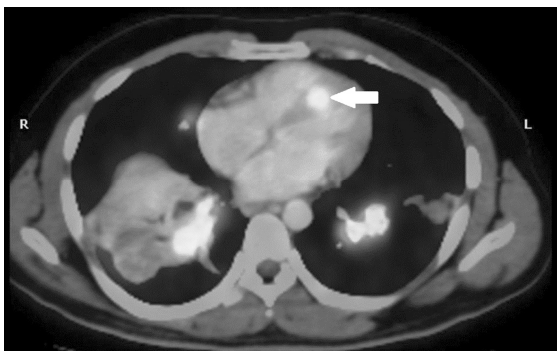


Fig 2c. Fused PET-CT transaxial images showing discrete foci of increased FDG uptake to be corresponding to the hypodense foci in the interventricular septum.

By the time metastasis to the heart has occurred, the disease would most often have progressed extensively to involve other organs and the management is most often a palliative one. Overall, the symptomatology in such patients are predominantly those related to other organ involvement rather than related to cardiac involvement. Diagnosis of intracardiac metastasis is usually made during post mortem examination unless the patient presents clinically with obvious clinical signs of arrhythmias, heart failure, right ventricular outflow tract obstruction or pericardial effusion. Complete atrioventricular block, an uncommon manifestation of metastatic cardiac tumor has been reported previously where autopsy had revealed metastatic involvement of the heart limited to interventricular septum. Transthoracic ultrasound due to its easy availability is the most common imaging method used to detect cardiac metastasis. Contrast MRI, based on varying signal intensities in T1 and T2 weighted images has been proved by many studies as a very effective tool in differentiating between a cardiac thrombus and a cardiac tumor. 2D echocardiography with its easy availability and cost effectiveness has high sensitivity for evaluation of cardiac masses and has made detection of cardiac metastasis much simpler.

Review of the literature shows that cardiac metastasis predominantly occurs during the sixth and seventh decade of life following the overall age distribution of malignant diseases [1]. Nowadays with the widespread availability of FDG-PET imaging facilities in most of the countries, many cases of cardiac metastasis are being picked up during whole body PET imaging. Rare case of an FDG-PET scan helping to pick up a tumor in the right ventricle and

septum in a patient presenting with cardiac arrhythmia has been reported in the literature [7]. Even though any malignant tumor can metastasize to the heart, reports of head and neck malignancies metastasizing to the heart are rare. Aggressive management of local malignancies with chemotherapy and radiotherapy and with availability of better imaging modalities, more and more cases of metastatic deposits to heart are being picked up antemortem nowadays. Our patient, a 32 year old male was initially treated with aggressive local surgery followed by chemoradiation and was evaluated with an FDG-PET CT scan 07 months later due to suspected local recurrence in the cervical lymph node. Hypermetabolic foci was detected corresponding to the clinically palpable cervical lymph nodes. Whole body PET scan also revealed multiple supra and infradiaphragmatic lymphnodal and bilateral lung metastasis. Overall myocardial uptake was lesser than the normal, but discrete foci of increased FDG uptake was noted corresponding to the interventricular septum in fused PET-CT images. Subsequent 2D echocardiography revealed a hyperechoic structure attached to the interventricular septum which on clinical correlation with FDG-PET CT images, was diagnostic of a metastatic foci in the septum. Patient was quite asymptomatic with regards to his cardiac status. Due to extensive distant metastatic disease, relatives were not willing for any aggressive management and he was referred for palliative chemotherapy. So even though reported literature speaks of cardiac metastasis as more common in elderly age groups and that too as very rare occurrence in head and neck malignancies [8], our patient, a young male in his 4th decade is a diagnosed case of squamous cell carcinoma of buccal mucosa which had metastasized to the heart 07 months after his initial diagnosis.

REFERENCES

1. Reynen K. Frequency of primary tumors of the heart. *Am J Cardiol.* 1996 Jan 1;77(1):107.
2. Burke A, Virmani R. Tumors of the cardiovascular system. In: *Atlas of tumor pathology, 3rd Series, Fascicle 16.* Washington, DC: Armed Forces Institute of Pathology; 1996.
3. Abraham KP, Reddy V, Gattuso P. Neoplasms metastatic to the heart: review of 3314 consecutive autopsies. *Am J Cardiovasc Pathol.* 1990;3(3):195-8.
4. Klatt EC, Heitz DR. Cardiac metastases. *Cancer.* 1990 Mar 15;65(6):1456-9.
5. Bisel HF, Wroblewski F, Ladue JS. Incidence and clinical manifestations of cardiac metastases. *J Am Med Assoc.* 1953 Oct 24;153(8):712-5.
6. Bussani R, De-Giorgio F, Abbate A, Silvestri F. Cardiac metastases. *J Clin Pathol.* 2007 Jan;60(1):27-34.
7. Shimotsu Y, Ishida Y, Fukuchi K, Hayashida K, Toba M, Hamada S, Takamiya M, Satoh T, Nakanishi N, Nishimura T. Fluorine-18-fluorodeoxyglucose PET identification of cardiac metastasis arising from uterine cervical carcinoma. *J Nucl Med.* 1998 Dec;39(12):2084-7.
8. Kavanagh MM, Janjanin S, Prgomet D. Cardiac metastases and a sudden death as a complication of advanced stage of head and neck squamous cell carcinoma. *Coll Antropol.* 2012 Nov;36 Suppl 2:19-21.