

## Bone scan in alcohol induced multifocal avascular osteonecrosis: A diagnostic quandary

Maseeh uz Zaman<sup>1</sup>, Nosheen Fatima<sup>2</sup>, Unaiza Zaman<sup>3</sup>, Areeba Zaman<sup>3</sup>

<sup>1</sup>Department of Radiology, Aga Khan University Hospital (AKUH), Karachi, Pakistan

<sup>2</sup>Department of Nuclear Medicine, Dr Ziauddin Medical University, Karachi, Pakistan

<sup>3</sup>Dow University of Health Sciences (DUHS), Karachi, Pakistan

(Received 19 February 2014, Revised 14 May 2014, Accepted 18 May 2014)

### ABSTRACT

Multifocal avascular osteonecrosis is an uncommon entity having a predominant association with steroids and less commonly with alcohol abuse. In literature only few cases of alcohol induced multifocal avascular osteonecrosis involving both hips and shoulder are reported. To the best of our understanding this is the first case report or contribution from nuclear medicine court and it would help the nuclear physicians to mull about this entity in alcoholics presented with assumed “polyarthritis”.

**Key words:** Avascular osteonecrosis; Multifocal; Alcohol; Bone scan; Polyarthritis

**Iran J Nucl Med 2015;23(1):56-58**

Published: December, 2014

<http://irjnm.tums.ac.ir>

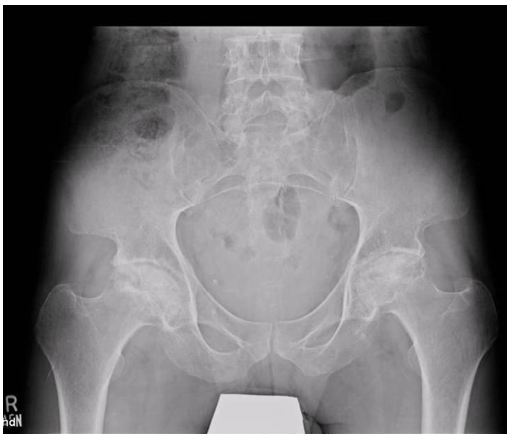**Corresponding author:** Dr. Maseeh uz Zaman, Department of Radiology, The Aga Khan University Hospital, Karachi, Pakistan. E-mail: [maseeh.uzzaman@aku.edu](mailto:maseeh.uzzaman@aku.edu)

## CASE REPORT

Avascular osteonecrosis is a well known morbidity and majority of cases being idiopathic or attributed to steroid or alcohol intake [1, 2]. When process involves three or more joints, it is called multifocal avascular osteonecrosis [3].

Alcohol induced avascular osteonecrosis frequently involves femoral head but only few cases of multifocal osteonecrosis have been reported in literature [4, 5]. We are presenting a case of multifocal avascular osteonecrosis involving both hips and shoulders in a male with history of chronic alcoholism.

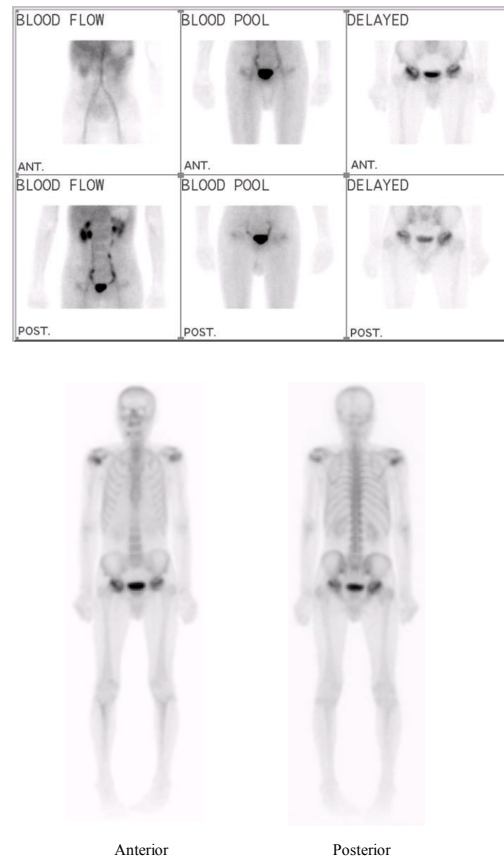
A 46 years old Afghan male presented with 1 year history of pain and restricted movements over both hips and both shoulders. He was non-diabetic, normotensive with a longstanding history of alcoholism (about 5-6 years with an average intake of 300-400 ml/3-5 days/week). He had no history of oral or intravenous steroid intake. His haematological and basic biochemical investigations were unremarkable. His serum vitamin B12 and folic acid levels were also within desired limits. His pelvic X-ray revealed subchondral sclerosis with areas of lucencies in both femoral heads with mild flattening of left femoral head as well, suggestive of avascular necroses (Figure 1).



**Fig 1.** Pelvic X-ray AP view showing deformity with subchondral sclerosis involving both femoral heads with narrowing of joint spaces. Flattening of left femoral head is also appreciable.

He was referred to Nuclear Medicine Section for a bone scan. A three phase bone scan was performed with 800 MBq of  $^{99m}\text{Tc}$ - Methylene Diphosphonate ( $^{99m}\text{Tc}$ -MDP) using dual head gamma camera (Ecam, Siemens, Germany) with high resolution collimators. Dynamic and blood pool images revealed increased blood flow over both hips with central photolucencies. Delayed images showed increased tracer deposition with central cold areas over both

hips and left shoulder highly suggestive of avascular osteonecrosis. Right shoulder also revealed increased tracer uptake more over the distal part suggestive of secondary degenerative changes with avascular necrosis (Figure 2).

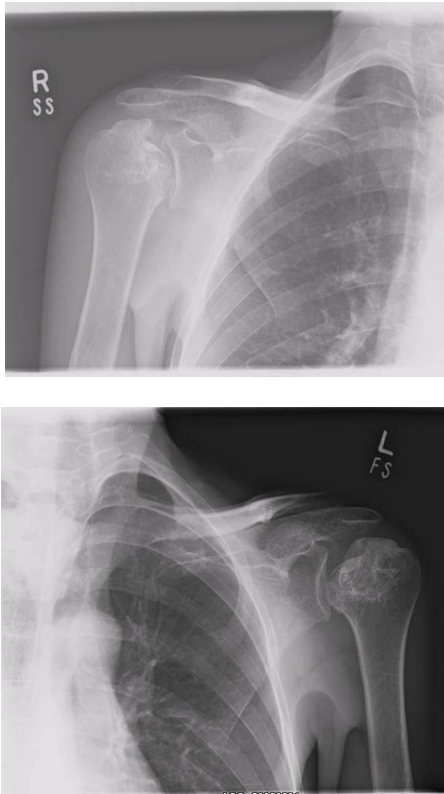


**Fig 2.** Three phase bone scan anterior and posterior images showing increased blood flow and delayed tracer uptake with central photon deficiency involving both hip joints (above). Whole body images show doughnut lesions over both hip and left shoulder joints suggestive of avascular osteonecrosis. Abnormal uptake is also appreciated over right shoulder more marked distally (below).

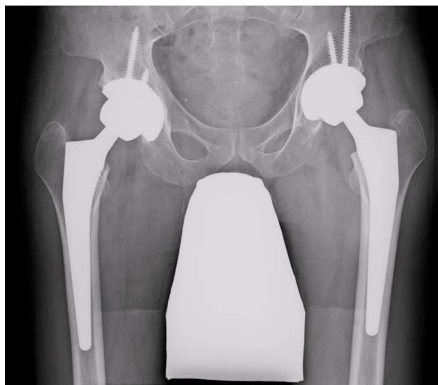On the basis of bone scan findings, he was advised shoulders X-ray demonstrating deformed heads of both humerus with early secondary degenerative changes in right glenohumeral joint (Figure 3). A final diagnosis of multifocal avascular osteonecrosis involving both femoral and humeral heads was made. Subsequently patient has had bilateral total hip replacement (Figure 4) and surgeon decided no intervention for shoulders as these are non-weight bearing joints.

## DISCUSSION

Multifocal avascular osteonecrosis is a well established clinical condition which occurs due to disruption of blood supply.



**Fig 3.** Both shoulders X-ray showing deformity of heads of both humeri with arthritic change over right glenohumeral joint.



**Fig 4.** Pelvic X-ray AP view showing bilateral total hip replacement with shielding of genitalia.

Steroid is the primary cause in 91% [6] and 5.3% of alcoholics were found to have avascular osteonecrosis and out of these only 6.1% alcoholics had multifocal avascular osteonecrosis [7]. Pathogenesis of osteonecrosis is not clearly understood. However, strong evidence is in support of increased adipogenesis as a major underlying mechanism which causes venous sinusoidal compression leading to venous congestion, intraosseous hypertension, impaired arterial inflow,

and ultimately, infarction [8]. There is no established threshold volume of alcohol intake for avascular osteonecrosis, although Japanese Orthopaedic Association suggested a 400ml of 100% alcohol per week [9]. Our patient's intake is well beyond this threshold but we are not sure about the strength of used alcohol. In this case radionuclide bone scan revealed significant abnormality over both shoulders as well which paved the path for radiological examination of shoulders and helped in reaching the diagnosis of multifocal avascular osteonecrosis.

## CONCLUSION

To the best of our understanding this is the first case report or contribution from nuclear medicine court about alcohol induced multifocal avascular osteonecrosis involving both femoral and humeral heads. This report will be an important addition to the data base having only few reported cases of alcohol induced multifocal avascular osteonecrosis in literature. It would also assist the nuclear physicians to mull about this entity in alcoholics presented with assumed "polyarthrititis".

## REFERENCES

1. Gold EW, Cangemi PJ. Incidence and pathogenesis of alcohol-induced osteonecrosis of the femoral head. *Clin Orthop Relat Res.* 1979 Sep;(143):222-6.
2. Koch CA, Tsigos C, Patronas NJ, Papanicolaou DA. Cushing's disease presenting with avascular necrosis of the hip: an orthopedic emergency. *J Clin Endocrinol Metab.* 1999 Sep;84(9):3010-2.
3. Taylor LJ. Multifocal avascular necrosis after short-term high-dose steroid therapy. A report of three cases. *J Bone Joint Surg Br.* 1984 May;66(3):431-3.
4. Moon JG, Shetty GM, Biswal S, Shyam AK, Shon WY. Alcohol-induced multifocal osteonecrosis: a case report with 14-year follow-up. *Arch Orthop Trauma Surg.* 2008 Oct;128(10):1149-52.
5. Valizade N, Fattahzadeh A. Multifocal avascular necrosis in an alcoholic male with antiphospholipid syndrome and megaloblastic anemia. *Shiraz E-Med J.* 2012;13(1): e20493.
6. Collaborative Osteonecrosis Group. Symptomatic multifocal osteonecrosis. A multicenter study. *Clin Orthop Relat Res.* 1999 Dec;(369):312-26.
7. Orlić D, Jovanović S, Anticević D, Zecević J. Frequency of idiopathic aseptic necrosis in medically treated alcoholics. *Int Orthop.* 1990;14(4):383-6.
8. Laroche M. Intraosseous circulation from physiology to disease. *Joint Bone Spine.* 2002 May;69(3):262-9.
9. Matsuo K, Hirohata T, Sugioka Y, Ikeda M, Fukuda A. Influence of alcohol intake, cigarette smoking, and occupational status on idiopathic osteonecrosis of the femoral head. *Clin Orthop Relat Res.* 1988 Sep;(234):115-23.