

False positive ^{18}F -FDG PET/CT due to active varicella zoster infection in a Hodgkin's lymphoma patient

Zakie Nasiri¹, Zahra Kiamanesh¹, Farnaz Banezhad¹, Farshad Emami², Ramin Sadeghi¹

¹Nuclear Medicine Research Center, Mashhad University of Medical Sciences, Mashhad, Iran

²Nuclear Medicine and Molecular Imaging Department, Imam Reza International University, Mashhad, Iran

(Received 8 December 2018, Revised 25 February 2019, Accepted 3 March 2019)

ABSTRACT

We report a case of Hodgkin lymphoma (classic type) referred for response assessment after two cycles of chemotherapy with ABVD regimen. The F-18 fluorodeoxyglucose positron emission tomography (F-18 FDG PET/CT) showed hypermetabolic cutaneous and subcutaneous lesions with a linear pattern in the left arm with significant F-18 fluorodeoxyglucose positron accumulation in associate with left axillary hypermetabolic lymph nodes. She presented with left arm pruritic rash accomplished by pain from two weeks ago. On clinical examination, painful papulovesicular rash with palpable enlarged axillary lymph node were noted. These findings were compatible with cutaneous herpes zoster infection of the left arm along with axillary reactive lymphadenopathy.

Key words: Active herpes infection; Hodgkin's lymphoma; Clinical examination; Nuclear medicine

Iran J Nucl Med 2019;27(2):146-148

Published: July, 2019

<http://irjnm.tums.ac.ir>

Corresponding author: Dr. Ramin Sadeghi, Nuclear Medicine Research Center, Mashhad University of Medical Sciences, Mashhad, Iran. E-mail: Sadeghir@mums.ac.ir

INTRODUCTION

Potential diagnostic errors due to active herpes infection and its associated adenopathy have been reported [1-3]. Herein we report a case of herpes zoster and underlining the possibility of an active viral infection in an immunocompromised patient which may mimic recurrent disease. The importance of awareness of opportunistic infections and precise attention to the patient history and clinical assessment is emphasized (Figure 1).

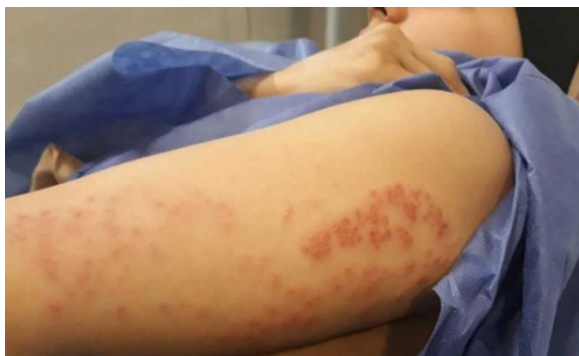

Fig 1. Varicella-zoster reactivation affected the left cervical nerve branches in the present immunocompromised case.

CASE PRESENTATION

A 31 years old lady with a history of classic type Hodgkin's lymphoma without unfavorable feature, diagnosed with a prevascular anterior mediastinal mass since seven months, was referred to our department for response assessment. She has received two cycles of ABVD regimen without mediastinal

radiotherapy, four weeks after the last course of ABVD mid-treatment ¹⁸F-FDG PET/CT was done. ¹⁸F-FDG PET/CT scan revealed hypermetabolic axillary nodes with fatty hilum as well as a subtle linear hypermetabolic cutaneous uptake in the upper left arm in MIP images with no other pathologic ¹⁸F-FDG avid lesion throughout the body. Clinically, erythematous vesicles in the left cervical innervation pathognomonic of herpes zoster infection with enlarged axillary lymph nodes were detected. Hypermetabolic axillary lymph nodes were considered due to a reactive response to viral infection. (Figure 2) Complete response to therapy was reported. Upon clinical examination, the reason of axillary lymphadenopathy and hypermetabolism was obviously due to varicella zoster infection and tissue biopsy was not done. Subsequently, sixth months following antiviral treatment, axillary lymphadenopathy disappeared upon sonographic correlation with no cutaneous lesions. After completion of chemotherapy, the patient was in disease-free state without any evidence of recurrent disease in long term clinical and conventional imaging follow up.

DISCUSSION

Negative interim metabolic PET/CT scan results, predict complete remission at the end of treatment and even works better than other prognostic model such as NCCN-IPI (international prognostic Score) [4, 5]. Due to high negative predictive value (NPV) in the early stage of Hodgkin's lymphoma, negative findings can lead to decrease courses of radiotherapy especially in the good responder patients [6, 7].

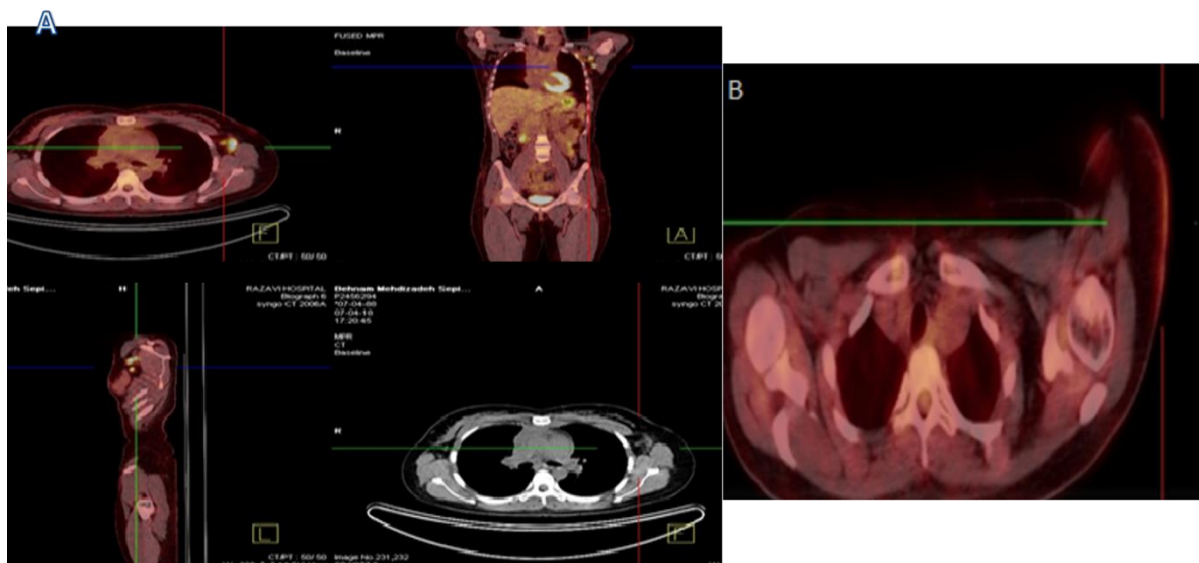


Fig 2. Fused F18-PETCT images of the chest showed enlarged high FDG avid axillary lymph nodes on the left side and linear pattern tracer uptake compatible with cutaneous varicella zoster clinically.

According to the literature, the main explained mechanism for ¹⁸F-FDG uptake related to high glycolytic activity and overexpressing specific membrane glucose transporter compared to the normal cells. Because ¹⁸F-FDG scanning is not a tumor-specific tracer, false positive findings are frequently encountered, atypical physiologic site and benign pathologic lesions such as: infectious, autoimmune process, granulomatous inflammation (tuberculoma, sarcoidosis) [8], recent immunization status [9], post-surgical inflammatory tissue, inflammatory reactions after radiotherapy, nonspecific reactive changes associated with treatment as well as treatment-related change like thymic hyperplasia, Doxil-related condition [10], bleomycin-induced ILD(interstitial lung disease) [11], flare phenomenon, osteonecrosis and insufficiency fracture [12, 13]. Even, technical errors can be a potential cause of misleading interpretation such as suboptimal injection with ¹⁸F-FDG uptake in the regional nodes, misregistration artifact and dense materials that may artefactually increase ¹⁸F-FDG uptake [14]. It is even reported that within the neoplastic masses, 24% of ¹⁸F-FDG uptake was related to the granulation tissue and activated macrophage [15].

To minimize, possible non-tumoral ¹⁸F-FDG avid foci the time interval between chemotherapy and scanning should be the least 3-week window [16], through attention to history, clinical examination and observation should be part of nuclear medicine physicians' responsibilities especially in an immunocompromised patient. Suspected lesions should be further evaluated by delayed images, reviewing non-attenuation correlated images as well as using diagnostic CT or (magnetic resonance imaging) MRI providing anatomical details. Using a consistent guideline for reporting ¹⁸F-FDG-PET can also decrease the false positive results as well as a continuous learning activities of reporting physicians [17].

REFERENCES

- Sharma R, Jaimini A, Mondal A, Tripathi M. Pitfall of ¹⁸F-FDG-PET imaging in oncology: herpes zoster with axillary lymphadenopathy. *Hell J Nucl Med*. 2008 Jan-Apr;11(1):51-2.
- Sheehy N, Israel DA. Acute varicella infection mimics recurrent Hodgkin's disease on F-18 FDG PET/CT. *Clin Nucl Med*. 2007 Oct;32(10):820-1.
- Muzaffar R, Fesler M, Osman MM. Active shingles infection as detected on (18)F-FDG PET/CT. *Front Oncol*. 2013 Apr 24;3:103.
- Gallamini A, Zwarthoed C. Interim FDG-PET Imaging in Lymphoma. *Semin Nucl Med*. 2018 Jan;48(1):17-27.
- Evens AM, Kostakoglu L. The role of FDG-PET in defining prognosis of Hodgkin lymphoma for early-stage disease. *Blood*. 2014;124(23):3356-64.
- Radford J, Illidge T, Counsell N, Hancock B, Pettengell R, Johnson P, Wimperis J, Culligan D, Popova B, Smith P, McMillan A, Brownell A, Kruger A, Lister A, Hoskin P, O'Doherty M, Barrington S. Results of a trial of PET-directed therapy for early-stage Hodgkin's lymphoma. *N Engl J Med*. 2015 Apr 23;372(17):1598-607.
- Barrington SF, Mikhaeel NG. PET Scans for Staging and Restaging in Diffuse Large B-Cell and Follicular Lymphomas. *Curr Hematol Malig Rep*. 2016 Jun;11(3):185-95.
- Kim KS. Primary nasopharyngeal tuberculosis mimicking carcinoma: a potentially false-positive PET/CT finding. *Clin Nucl Med*. 2010 May;35(5):346-8.
- Williams G, Joyce RM, Parker JA. False-positive axillary lymph node on FDG-PET/CT scan resulting from immunization. *Clin Nucl Med*. 2006;31(11):731-732.
- Hornreich G, Schloss C, Hoskins WJ, Muggia FM. Doxil-induced radiation recall: a cause for false-positive PET scan findings. *Gynecol Oncol*. 2001 Mar;80(3):422-3.
- Paschali AN, Gnanasegaran G, Cook GJ. FDG PET-CT: Need for vigilance in patients treated with bleomycin. *Indian J Nucl Med*. 2017 Apr-Jun;32(2):122-124.
- Corrigan AJ, Schleyer PJ, Cook GJ. Pitfalls and artifacts in the use of PET/CT in oncology imaging. *Semin Nucl Med*. 2015 Nov;45(6):481-99.
- Gorospe Sarasua L, Echeveste Aizpurua J, Raman S. Positron-emission tomography/computed tomography: artifacts and pitfalls in cancer patients. *Radiologia*. 2006;48(4):189-204.
- Keon TP. Death on induction of anesthesia for cervical node biopsy. *Anesthesiology*. 1981 Oct;55(4):471-2.
- Kubota R, Kubota K, Yamada S, Tada M, Ido T, Tamahashi N. Active and passive mechanisms of [fluorine-18] fluorodeoxyglucose uptake by proliferating and preneoplastic cancer cells in vivo: a microautoradiographic study. *J Nucl Med*. 1994 Jun;35(6):1067-75.
- Long NM, Smith CS. Causes and imaging features of false positives and false negatives on F-PET/CT in oncologic imaging. *Insights Imaging*. 2011 Dec;2(6):679-698.
- Strauss LG. Fluorine-18 deoxyglucose and false-positive results: a major problem in the diagnostics of oncological patients. *Eur J Nucl Med*. 1996 Oct;23(10):1409-15.