

2-¹⁸F]fluoro-2-deoxy-D-glucose PET-CT in a case of cerebellar ataxia associated thyroid disorder

Anurag Jain¹, Anupam Kumar², Azhar Husain³,
Abhishek Mahato¹, Amit Sharma³, Awadhesh Tiwari¹

¹Department of Nuclear Medicine, Command Hospital, Armed Forces Medical College, Lucknow, India

²Department of Endocrinology, Command Hospital, Armed Forces Medical College, Pune, India

³Department of Nuclear Medicine, Command Hospital, Armed Forces Medical College, Pune, India

(Received 3 July 2021, Revised 11 March 2022, Accepted 13 March 2022)

ABSTRACT

Auto-immune hypothyroidism being the common cause of hypothyroidism with usual clinical features like constipation, fatigue, cold intolerance and weight gain can rarely present with neurologic problems like reversible cerebellar ataxia, dementia, peripheral neuropathy, psychosis and coma. In this manuscript we present a case that was evaluated with a suspicion of paraneoplastic syndrome for cerebellar ataxia. 2-¹⁸F]fluoro-2-deoxy-D-glucose (¹⁸F]FDG) PET-CT scan showed diffuse hypometabolism in both cerebellar lobes and diffusely increased metabolic activity in thyroid gland. Further investigations revealed the hypothyroidism with positive Anti-TPO antibody. Thyroid replacement therapy was started and patient showed significant clinical as well as biochemical improvement after 3 weeks. The main aim of this case report is to highlight the fact that hypothyroidism has to be considered in all patients who present with acute onset of cerebellar ataxia and ¹⁸F]FDG PET-CT scan was helpful as imaging modality in this case.

Key words: Cerebellar ataxia; ¹⁸F]FDG PET-CT; Thyroid disorder

Iran J Nucl Med 2022;30(2):129-131

Published: July, 2022

<http://irjnm.tums.ac.ir>

Corresponding author: Dr. Anurag Jain, Department of Nuclear Medicine, Command Hospital, Armed Forces Medical College, Lucknow, India. E-mail: triplea.jain@gmail.com

CASE PRESENTATION

40-year-old male patient, driver by profession known case of PIVD C5-C6 presented in July 2020 with insidious onset progressive malaise, associated with lethargy and slurring of speech. There was non-fluency in speech, associated paraesthesia in both upper limbs, insomnia, and recent memory impairment. He also had postural giddiness and gait instability for 03-month duration. There was no history suggestive of distal muscle weakness or any sensory symptoms. Negative history for alcohol consumption, diabetes, and hypertension was there. There was no family history of consanguineous marriage, ataxia or other congenital disorder.

On physical examination, Pulse 100/minute, BP 124/84 mm of Hg, BMI: 25.59 Kg/m². No pallor/icterus/clubbing/lymphadenopathy was seen. No thyromegaly and no tremors were there. Fundoscopy was normal. Central nervous system examination showed higher motor function were normal. Dysarthria was present. Hypotonia of left upper and lower limb was seen with muscle power of 4/5 in both upper and lower limbs. Abdomen, cardiovascular and respiratory examination were normal. His clinical evaluation revealed subtle cerebellar signs, more on the left side as compared to right side no pyramidal/extrapyramidal/sensory signs were appreciated. His CBC, biochemistry and electrolytes were within normal limits. Vitamin B12, Serum folate and Vitamin E levels were normal. MRI showed diffuse atrophy of cerebellar hemisphere, pons and middle cerebellar peduncle. [¹⁸F]FDG PET-CT

whole body and brain study showed diffuse hypometabolism in both cerebellar lobes (SUV max-9.67), uniform metabolic activity in corpus striatum however diffusely increased metabolic activity was noted in thyroid gland [Figure 1]. [¹⁸F]FDOPA scan was also done that revealed symmetric distribution of tracer in bilateral caudate lobes and putamen therefore confirming optimal dopaminergic activity in corpus striata.

The thyroid profile of patient revealed TSH =26.1 uIU/ml, free T4 = 0.89 ng/dl, free T3= 2.42 ng/dl). Thyroperoxidase antibody (TPO-Ab) was raised at > 1300 IU/ml. CSF cytology was negative for malignancy and microscopy revealed no organism growth. Autonomic function test was normal, SCA (spinocerebellar ataxia) gene panel was negative, Anti parietal cell antibody was negative.

Patient was diagnosed as a case of autoimmune thyroiditis with primary hypothyroidism, proximal muscle weakness and ataxia. He was evaluated for reversible causes of ataxia, however there was no evidence of nutritional deficiency, malignancy, or spinocerebellar ataxia on genetic testing. Managed with tapering dosage of steroids and replacement therapy of thyroid hormone. On follow up patient shows significant clinical improvement and biochemical recovery of thyroid profile. [¹⁸F]FDG PET-CT shows significantly decreased metabolic activity in both lobes of thyroid (Figure 1).The [¹⁸F]FDG uptake in the cerebellum showed improvement with SUV max-11.16.

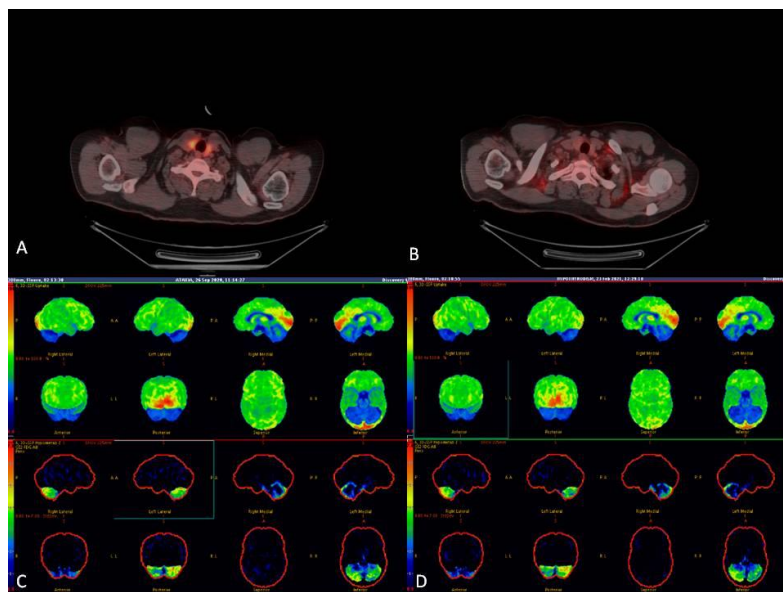


Fig 1. [¹⁸F]FDG PET-CT scan. Axial section showing diffusely increased metabolic activity in both lobes of thyroid that decreased significantly in post thyroid hormone replacement treatment images (A and B). Brain imaging showing Hypometabolism in cerebellar region with partial improvement in post thyroid hormone replacement treatment images (C and D).

DISCUSSION

Acquired cerebellar ataxia has been described with hypothyroidism and is typically reversible by thyroid hormone replacement therapy. The usual clinical features of auto-immune hypothyroidism are constipation, fatigue, cold intolerance and weight gain. Rarely, it can present with neurologic problems like reversible cerebellar ataxia, dementia, peripheral neuropathy, psychosis and coma. The cerebellar dysfunction has been attributed to metabolic and physiological effects of the endocrine disorder. Hypothyroidism should be considered in all cases of cerebellar ataxia as it is a reversible cause of ataxia. In a few patients, however, ataxia has persisted despite thyroid replacement therapy [1, 2].

Cerebellar degeneration in patients with raised antithyroid antibodies may be immune mediated. Some cases of hypothyroidism associated cerebellar ataxia do not reverse with normalization of their thyroid state with thyroid hormone replacement and may be harboring undiagnosed Hashimoto's thyroiditis [3].

Encephalopathy with autoimmune thyroid disease (EAATD) is mostly associated with Hashimoto's thyroiditis and has been uncommonly reported with Grave's disease. This case is aimed to report the association of EAATD with thyroid peroxidase (TPO) and thyroid-stimulating immunoglobulin (TSI) antibodies in Grave's disease [4].

Cerebellar hypometabolism on [¹⁸F]FDG PET has usually been mentioned in several conditions, like chronic alcohol abuse, antiepileptic medication use, multiple system atrophy, and cerebellar infarction [5].

[¹⁸F]FDG PET-CT scan in suspected paraneoplastic cerebellar syndrome shows the degree of cerebellar metabolic abnormalities that is related to cell degeneration or loss of cells secondary to an inflammatory response or immunological reaction [6].

CONCLUSION

Ataxia is an important clinical problem. At different ages the causes can differ; among adults the important causes which merit consideration are cerebellar disorders, alcohol related ataxia, sensory ataxia because of nutritional deficiencies of cyanacobalamine and folic acid and paraneoplastic disorders in the elderly population and posterior circulation defects and strokes. Autoimmune conditions causing ataxia are seldom evaluated in such patients. Besides, metabolic function evaluation in different brain regions hardly forms a part of evaluation even in specialty clinics. Hypometabolism affecting different regions of the brain, as shown in this case could be the result of antibody mediated

dysfunction or a result of reduced regional metabolism primarily by the deficiency of thyroid hormones. Functional studies of brain are useful to establish the cause in cases where complete investigations are equivocal and can also be used to ascertain the improvement in metabolism of brain regions.

REFERENCES

1. Selim M, Drachman DA. Ataxia associated with Hashimoto's disease: progressive non-familial adult onset cerebellar degeneration with autoimmune thyroiditis. *J Neurol Neurosurg Psychiatry*. 2001;71(1):81-87.
2. Pavan MR, Madi D, Achappa B, Gupta A. Doctor I am swaying: An interesting case of ataxia. *J Clin Diagn Res*. 2012; 6(4):702-703.
3. Kotwal SK, Kotwal S, Gupta R, Singh JB, Mahajan A. Cerebellar ataxia as presenting feature of hypothyroidism. *Arch Endocrinol Metab*. 2016 Apr;60(2):183-5.
4. Ayub MT, Shafiq T, Ayub T, Afroz S, Husni H. A steady cause of unsteadiness: A case of thyroid-associated cerebellar ataxia. *Cureus*. 2020 May;12(5):e8080.
5. Nawas MT, Kubal WS, Kuo PH. Decreased cerebellar activity on 2-[¹⁸F]fluoro-2-deoxy-D-glucose PET/CT secondary to diffuse idiopathic cerebellar calcification. *Clin Nucl Med*. 2012;37(9):906-907.
6. López NO, González DP, García JA, Reyna JC, López LF. Paraneoplastic Cerebellar Degeneration as Initial Presentation of Papillary Carcinoma of the Fallopian Tube: Evaluation and Usefulness of 2-[¹⁸F]fluoro-2-deoxy-D-glucosePET-CT. *Case Report and Literature Review. Nucl Med Mol Imaging*. 2013;47(1):55-60.