

Additive clinical value of bone scintigraphy in patients with malignant tumors with absence of localized bone pain: A report on most common sex-related cancers

Babak Fallahi, Davood Beiki, Mohammad Bagher Khodaparast,
Ali Gholamrezanezhad, Armaghan Fard-Esfahani, Mohammad Eftekhari

Research Institute for Nuclear Medicine, Tehran University of Medical Sciences, Tehran, Iran.

(Received 11 April 2011, Revised 21 May 2011, Accepted 1 June 2011)

ABSTRACT

Introduction: Almost all malignant tumors have the potential to eventually produce bone metastasis. The aim of the current study was to report the distribution pattern and imaging characteristics of bone metastases detected by conventional whole body bone scintigraphy in patients with different types of malignancies and to assess their relationship with the complaint of bone pain.

Methods: As a cross-sectional study, 146 consecutive patients with histologically proven cancer who were referred for the assessment of possible bone metastatic involvement were investigated by ^{99m}Tc -Methylene Diphosphonate (MDP) whole body scintigraphy.

Results: A total of 146 patients (79 male and 67 female; mean age: 59.59 ± 11.95) were enrolled, of which 71 (48.6%) patients had prostate cancer, 61 (41.8%) breast cancer, 6 (4.1%) gastric malignancy, and 8 (5.5%) miscellaneous cancers. The most frequent sites of bone metastases (vertebrae, pelvis and sternum) demonstrated more intense radiotracer uptake. Most of patients (58.5%) with bone metastasis due to breast cancer reported no localized bone pain. Also in the subgroup with prostate cancer, no significant association was noted between the site of bone metastases and location of the pain perception in most of the skeletal zones.

Conclusion: Bone scintigraphy (by determining the specific pattern of bone metastases in different tumor types) may help physicians provide better care for patients who suffered from metastatic cancer. On the other hand, in view of the fact that no reliance can be placed on clinical symptoms and the patients' report of bone pain, bone scintigraphic data can be included in the follow-up evaluation of patients suspected to have bone metastasis, even in the absence of bone pain.

Keywords: Bone scintigraphy, Pain, Cancer, Metastasis.

Iran J Nucl Med 2011;19(1):51-58

Corresponding author: Dr. Davood Beiki, Research Institute for Nuclear Medicine, Tehran University of Medical Sciences, Shariati Hospital, North Kargar Ave. 1411713135, Tehran, Iran
E-mail: beikidav@sina.tums.ac.ir

INTRODUCTION

Almost all malignant tumors have the potential that eventually produce bone metastasis and in fact, metastatic bone involvement is responsible for more than 99% of malignant etiologies of bone destruction (1). Patients who suffer from bone metastases are at high risk of skeletal related events, such as pathologic fractures, spinal cord compression, requirement for bone surgical or radiotherapy and, in some cases, life threatening hypercalcemia of malignancy (1). These dramatic skeletal events may cause a rapid deterioration in patients' quality of life, resulting in disability and limitation of function. In addition, chronic treatment of ongoing skeletal morbidity for a relatively long period may increase the emotional distress of patients (2).

Generally, bone is a common site of metastasis for a number of different cancers. At least 65% to 75% of patients who are afflicted by prostate cancer will develop bone metastases in the course of their disease (3). Similarly, it has been estimated that 65% to 75% of patients with breast cancer (4), 30% to 40% of patients who suffer from lung cancer (5), and up to 35% of patients with renal cell carcinoma develop bone metastases during the course of the disease progression (6). Sometimes (about 3%), the primary source of the bone metastasis is unknown and bone metastasis appears the only manifestation of the disease (7).

It is interesting to know the pattern and distribution of bone metastases for different cancers. This information may lead to the knowledge about underlying mechanisms of bone metastases and routes of spread of malignant lesions throughout the skeleton. It may also have possible clinical impact on determining the risk of future adverse effects of bone metastases such as possibility of pathologic bone fracture.

The aim of the current study was to report the distribution pattern and imaging characteristics of bone metastases detected by conventional whole body bone scintigraphy in patients with different types of malignancies and their relationship to patients' complaint of bone pain.

METHODS

As a cross sectional study, 146 consecutive patients with histologically proven cancer who were referred for the assessment of possible metastatic involvement of the bony skeleton were investigated using ^{99m}Tc -Methylene Diphosphonate (MDP) whole body scintigraphy. The scintigraphic studies were done as per request of the referring physician for initial or post-therapeutic staging of the disease with no additional intervention on the subjects. After an attending interview by the patients and obtaining informed consent, the past medical records of the patients were evaluated. Any history of fractures, trauma, osteomyelitis, cellulitis, edema, arthritis, neoplasms, orthopedic or nonorthopedic surgery, metabolic bone disease and limitation of joint movements as well as history of any known anatomic or functional renal abnormalities was recorded. Also the data of previous bone scan or any other recent scintigraphy, computed tomography (CT), magnetic resonance imaging (MRI), X-Ray or relevant laboratory results were collected.

Imaging protocol

A commercial MDP kit (AEOI, Tehran, Iran) was used. The labeling and quality control procedures were performed based on the manufacturer's instructions. A dose of 740 MBq (20 mCi) of ^{99m}Tc -MDP was injected intravenously. All patients were orally hydrated after the injection of radiotracer. Three hours later, patients were advised to void just before the start of image

acquisition. Then technicians ensured proper positioning and comfort of the patients under the gamma camera.

All patients underwent a whole body anterior and posterior planar scanning, using a dual-head gamma camera (Solus, ADAC, Milpitas, CA) equipped with low-energy high-resolution collimators and a 20% energy window centered at 140 keV. The speed of image acquisition was set at 10 cm/min. The scintigrams extended from the patients' skull to the ends of the feet. Additional spot view projections and/or SPECT acquisition were performed based on the supervising physician's opinion.

Following image acquisition, all scintigraphic images were reviewed by two expert nuclear medicine specialists and final diagnosis was reached by consensus. The entire skeleton was divided into 18 predetermined well delimited zones to assess the distribution of the metastatic lesions. The images were visually examined by the observers and the abnormal lesions in each zone, either with increased or decreased radiotracer uptake, were detected. For the semi-quantitative assessment, region of interest (ROI) was specified to any abnormal area in the skeleton and accordingly to the normal contralateral site as the control area of interest. In case of symmetrical contralateral involvement, the adjacent normal bone was considered as the control area. The average count ratio of the lesion to control area (L/C) was calculated using standard ROI analysis software (ADAC Laboratory).

The intensity of uptake in the specified lesions was semi-quantitatively analyzed via a 4-point scale. L/C ratio of less than one was defined as photon-deficient lesion. The ratios >1.0 and <2.0 were considered as mildly increased, ≥ 2.0 and <3.0 were adopted as moderately increased and ≥ 3.0 were signified as severely increased radiotracer uptake.

Statistical analysis

Statistical analysis was done using SPSS software package version 17.0 (SPSS Inc., Chicago, Illinois, USA). Using the Chi-square Test, the proportional frequencies of metastatic lesions in 18 well-delimited skeletal zones were compared between different cancer types. The frequency and the intensity of metastatic lesions between different subgroups of patients were also compared using Mann-Whitney U test. A P value of less than 0.05 was considered statistically significant.

RESULTS

A total of 146 patients (79 male and 67 female; mean age: 59.59 ± 11.95) were subsequently enrolled in the study, of which 71 (48.6%) patients had prostate cancer, 61 (41.8%) breast cancer, 6 (4.1%) gastric cancer, 8 (5.5%) miscellaneous cancers (three cases of lymphoma, one differentiated thyroid cancer, one small cell carcinoma, one laryngeal squamous cell carcinoma, one lung squamous cell carcinoma and one melanoma).

In this study we found that the older the patient, the higher the number of metastatic foci detected in whole body bone scintigraphy. Median number of metastatic foci in all patients older than 50 was 6, while in patients of 50 years old or younger was 3 ($p=0.011$). This was also true for the subgroup of patients with breast cancer (Median of 6 vs. 3 in cases >50 and those with ≤ 50 years, respectively, $p=0.005$), but not for the subgroup of prostate cancer ($p=0.206$). The distribution of metastatic sites in patients with different types of cancers is illustrated in Figure 1. We found no statistically significant difference for the pattern of metastatic distribution between different types of malignancies ($p=0.8$). Generally, vertebrae, pelvis and sternum were the most common sites of bone metastasis, all together account for 64.4% of the metastatic foci.

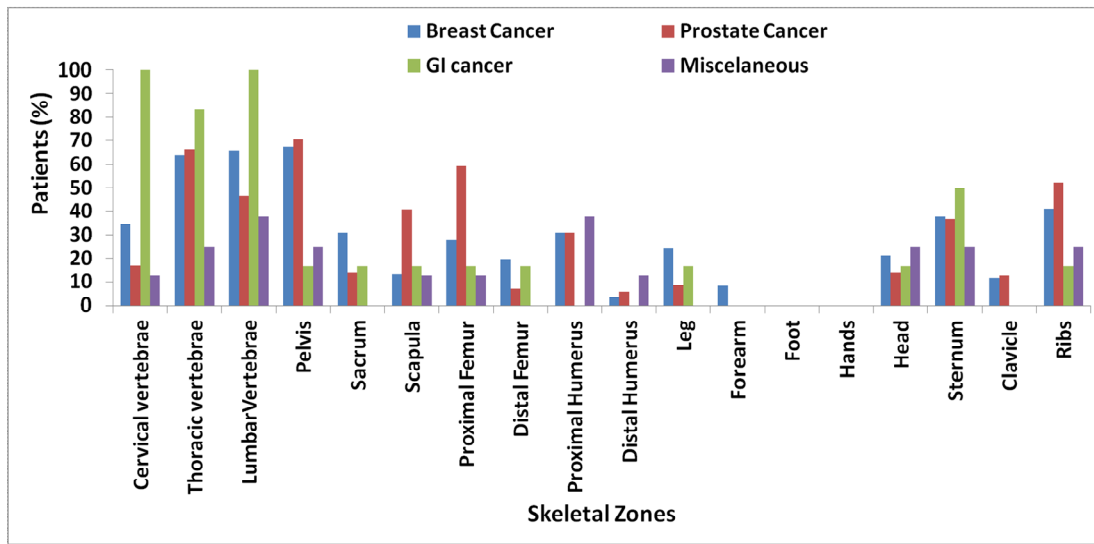


Fig 1. The distribution of patients (%) based on the presence of metastasis in different skeletal zones for diverse types of malignance.

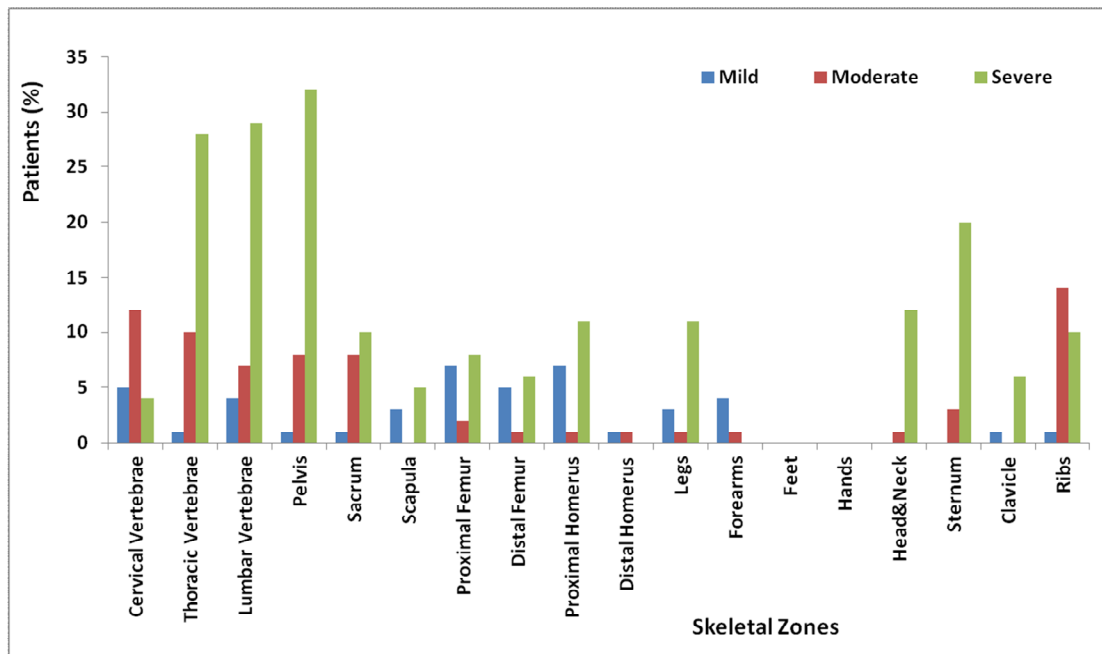


Fig 2. The distribution of patients (%) with breast cancer based on the intensity of radiotracer uptake in the metastatic lesions of different skeletal zones.

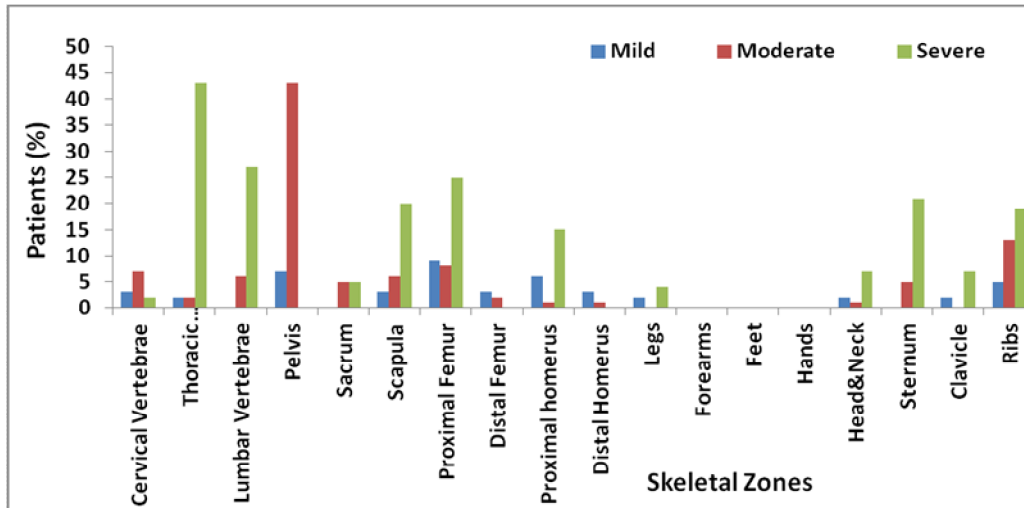


Fig 3. The distribution of patients (%) with prostate cancer based on the intensity of radiotracer uptake in the metastatic lesions of different skeletal zones.

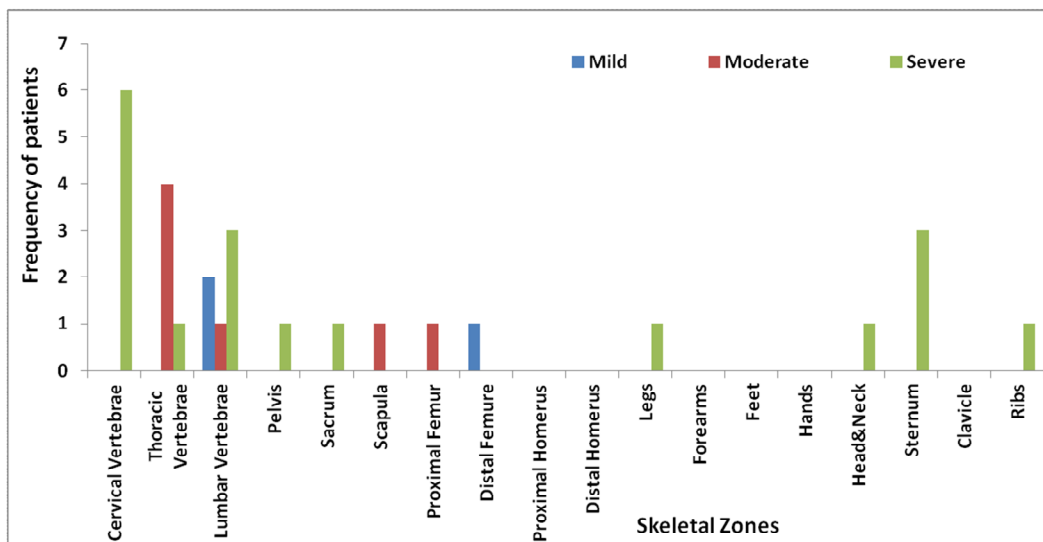


Fig 4. The frequency of patients with gastric cancer based on the intensity of radiotracer uptake in the metastatic lesions of different skeletal zones.

The most frequent sites of bone metastases also demonstrated more intense radiotracer uptake ($p < 0.001$, Figures 2-4). In patients with breast cancer, the site of pain perception was significantly related to the site of bone metastasis in most of the skeletal zones (Table 1). However, 58.5% of

patients with bone metastasis due to breast cancer reported no localized bone pain. In the subgroup with prostate cancer, no significant association was noted between the site of bone metastases and location of the pain perception in most of the skeletal zones (Table 2).

Table 1. Relationship between the site of pain perception and the location of bone metastases in patients with breast cancer.

| | Skeletal Zones | | | | | | | | | | | | | | | |
|---------------------|--------------------|--------------------|------------------|--------|--------|---------|----------------|--------------|------------------|----------------|-------|----------|-------|---------|----------|-------|
| | Cervical Vertebrae | Thoracic Vertebrae | Lumbar Vertebrae | Pelvis | Sacrum | Scapula | Proximal Femur | Distal Femur | Proximal Humerus | Distal Humerus | Legs | Forearms | Head | Sternum | clavicle | Ribs |
| M (+), P (+) | 8 | 16 | 27 | 20 | 6 | 1 | 5 | 5 | 11 | 1 | 5 | 1 | 5 | 6 | 4 | 6 |
| M (+), P (-) | 13 | 23 | 13 | 21 | 13 | 7 | 12 | 7 | 8 | 1 | 10 | 4 | 8 | 17 | 3 | 19 |
| M (-), P (+) | 3 | 1 | 7 | 2 | 6 | 7 | 8 | 6 | 1 | 7 | 4 | 7 | 3 | 6 | 6 | 2 |
| M (-), P (-) | 37 | 21 | 14 | 18 | 36 | 46 | 36 | 43 | 41 | 52 | 42 | 49 | 45 | 32 | 48 | 34 |
| P-Value | 0.003 | 0.002 | 0.010 | 0.003 | 0.160 | 0.900 | 0.480 | 0.030 | <0.000 | 0.110 | 0.020 | 0.630 | 0.002 | 0.340 | 0.002 | 0.040 |

M (+): with metastasis, M (-): without metastasis, P (+): with localized pain, P (-): without localized pain

Table 2. Relationship between the site of pain perception and the location of bone metastases in patients with prostate cancer.

| | Skeletal Zones | | | | | | | | | | | | | | | |
|---------------------|--------------------|--------------------|------------------|--------|--------|---------|----------------|--------------|------------------|----------------|-------|----------|-------|---------|----------|-------|
| | Cervical Vertebrae | Thoracic Vertebrae | Lumbar Vertebrae | Pelvis | Sacrum | Scapula | Proximal Femur | Distal Femur | Proximal Humerus | Distal Humerus | Legs | Forearms | Head | Sternum | clavicle | Ribs |
| M (+), P (+) | 3 | 7 | 21 | 25 | 0 | 9 | 9 | 0 | 1 | 1 | 2 | 0 | 2 | 3 | 1 | 3 |
| M (+), P (-) | 9 | 40 | 12 | 25 | 10 | 20 | 33 | 5 | 21 | 3 | 4 | 0 | 8 | 23 | 8 | 34 |
| M (-), P (+) | 6 | 7 | 17 | 5 | 9 | 3 | 3 | 7 | 6 | 6 | 5 | 7 | 5 | 4 | 6 | 4 |
| M (-), P (-) | 53 | 17 | 21 | 16 | 52 | 39 | 26 | 59 | 43 | 61 | 60 | 64 | 56 | 41 | 56 | 30 |
| P-Value | 0.160 | 0.200 | 0.150 | 0.060 | 0.200 | 0.009 | 0.220 | 0.440 | 0.320 | 0.300 | 0.020 | . | 0.200 | 0.700 | 0.900 | 0.600 |

M (+): with metastasis, M (-): without metastasis, P (+): with localized pain, P (-): without localized pain

The insufficient number of cases from each tumor type in the subgroups of gastric cancers as well as other miscellaneous tumors did not allow us to assess the relationship between the sites of bone pain and the scintigraphic evidence of metastases.

DISCUSSION

In our study the most common sites of skeletal metastases in the different types of cancer were vertebral column, pelvis, sternum and ribs, respectively. Our results were compatible with the report by Rusu et al. who found the higher frequency of

metastases involving the vertebral column, then the pelvis, ribs and sternum (8). These regions contain red pulp and bone marrow activity, which warrants higher perfusion for their function. It seems that their higher perfusion increases their chance of being involved by those cancers showing hematogenous metastases (9). Sudo et al. stated that bone metastatic lesions in patients with gastric cancer are predominantly seen in bones with red pulp, such as lumbar and thoracic vertebrae and ribs (9). Our study is confirmatory for their conclusion, as the most common sites of metastases in the patients with gastric cancer were vertebrae, then sternum and ribs. Also in our patient population, the most common places for metastases in patients who afflicted with breast cancer were vertebral column, pelvis, ribs and sternum, which seem to be in accordance with the findings of Adachi et al. who reported the more frequent sites of bone metastases to be lumbar and thoracic spine, pelvis, rib, extremities and skull (10).

Levren et al. examined the relationship between bone pain complaints of patients and metastases in a group of patients with prostate or breast cancers that had been referred for bone scintigraphy (11). They stated that 47% of patients with prostate cancer suffered from pain at the site of bone metastasis, but pain was not clinically important in 12% of the patients. On the other hand, metastases caused by breast cancer were more common in patients without pain than in patients with pain. They concluded that there is a significant association between pain and skeletal metastases in patients with prostate cancer and a reverse relationship in patients with breast cancer. Although our study found no significant association between the complaint of bone pain and scintigraphic evidences of metastasis in patients with prostate cancer, we observed an inverse relationship between bone pain and scintigraphic evidences of bone metastasis

in patients with breast cancer, at least in some skeletal zones. In fact, although some patients do experience pain in the site of bone metastatic lesions, this association has not clearly been established in all anatomical zones.

Based on our results, to request bone scintigraphy for the evaluation of metastatic involvement, no reliance can be placed on patients' complaint of bone pain alone, and bone scintigraphic data provide additional diagnostic value for the follow up of patients who suffer from malignant tumors.

Our study showed that diverse types of cancers do not have special metastatic tendency to different skeletal zones. Conversely, significant difference between the early bone spread in carcinoma of prostate (absence of skull involvement) and carcinoma of breast (presence of anterior chest wall involvement) was noted in a previous study (12). Their results support the fact that retrograde venous reflux as being an important contributing mode of spread for carcinoma of prostate and local spread as being relevant in the early spread of and breast carcinoma (12).

In our study, the most frequent sites of bone metastases also demonstrated more intense radiotracer uptake. This may indicate that the destructive process of metastatic bone lesion is usually seen in the frequent zones of metastatic involvement as opposed to areas infrequently involve with metastases.

CONCLUSION

In view of the fact that no reliance can be placed on clinical symptoms and the patients' complaint of bone pain, bone scintigraphic data should be included in the follow-up evaluation of patients with breast and prostate cancers suspected to have bone metastasis, even in the absence of bone pain. No special scintigraphic pattern of bone metastasis can be defined for these two common sex-related cancers.

REFERENCES

1. Machado M, Cruz LS, Tannus G, Fonseca M. Efficacy of clodronate, pamidronate, and zoledronate in reducing morbidity and mortality in cancer patients with bone metastasis: a meta-analysis of randomized clinical trials. *Clin Ther.* 2009 May;31(5):962-79.
2. British Association of Surgical Oncology Guidelines. The management of metastatic bone disease in the United Kingdom. The Breast Specialty Group of the British Association of Surgical Oncology. *Eur J Surg Oncol.* 1999 Feb;25(1):3-23.
3. Coleman RE. Skeletal complications of malignancy. *Cancer.* 1997 Oct;80(8 Suppl):1588-94.
4. Greenlee RT, Hill-Harmon MB, Murray T, Thun M. Cancer statistics, 2001. *CA Cancer J Clin.* 2001 Jan-Feb;51(1):15-36.
5. Coleman RE. Metastatic bone disease: clinical features, pathophysiology and treatment strategies. *Cancer Treat Rev.* 2001 Jun;27(3):165-76.
6. Zekri J, Ahmed N, Coleman RE, Hancock BW. The skeletal metastatic complications of renal cell carcinoma. *Int J Oncol.* 2001 Aug;19(2):379-82.
7. Donato J. Tumores ósseos. In: *Metástase de carcinoma.* Rio de Janeiro, Brazil: Rocca; 2001;p. 211-6.
8. Rusu V, Boiculese LV, Ștefănescu C, Hountis D, Costin M. A retrospective study of bone metastases distribution on 420 whole body scans. *Rev Med Chir Soc Med Nat Iasi.* 2004 Jan-Mar;108(1):114-7.
9. Sudo H, Takagi Y, Katayanagi S, Hoshino S, Suda T, Hibi Y et al. Bone metastasis of gastric cancer. *Gan To Kagaku Ryoho.* 2006 Aug;33(8):1058-60.
10. Adachi I, Suzuki M, Tsuchihashi T, Yamaguchi K, Abe K. Bone metastasis in advanced breast cancer. *Gan To Kagaku Ryoho.* 1987 May;14(5 Pt 2):1688-95.
11. Levren G, Sadik M, Gjertsson P, Lomsky M, Michanek A, Edenbrandt L. Relation between pain and skeletal metastasis in patients with prostate or breast cancer. *Clin Physiol Funct Imaging.* 2011 May;31(3):193-5.
12. Styles C. The distribution of bone metastases as shown on isotope scanning: proposed modes of spread. *Australas Radiol.* 1989 Aug;33(3):226-8.