

## Body outlining using Tc-99m filled flood source for lymphoscintigraphy imaging

Mehdi Momennezhad<sup>1</sup>, Hamid Reza Haghghi Kakhki<sup>2</sup>, Ramin Sadeghi<sup>1</sup>

<sup>1</sup>Nuclear Medicine Research Center, Mashhad University of Medical Sciences, Mashhad, Iran

<sup>2</sup>Azad University of Medical Sciences, Mashhad, Iran

(Received 1 June 2011, Revised 6 July 2011, Accepted 14 July 2011)

### ABSTRACT

**Introduction:** In the current study, we evaluated the feasibility of body outlining using Tc-99m filled flood source for lymphoscintigraphy imaging.

**Methods:** 80 patients were included in the study. Sentinel node mapping was done using Tc-99m Antimony sulfide colloid. For outlining the body a Tc-99m filled flood source was used which was placed behind or lateral to the patients for Anterior and lateral images respectively. The flood source was filled with 0.5 mCi, 1 mCi, 2 mCi, and 5 mCi for 10, 47, 10, and 3 patients respectively. The quality of outline images was assessed by two nuclear medicine specialists independently. Radiation exposure to the patients was also evaluated using thermoluminescent dosimeter (TLD-100).

**Results:** The quality of body contour images were good in images taken by 1, 2, and 5 mCi filled flood source. However the quality of images was poor in 8 out of 10 lymphoscintigraphies taken by 0.5 mCi filled flood source. The measured dose rate from the Tc-99m flood source was  $1.07 \pm 0.04 \mu\text{Sv}/\text{MBq}/\text{hr}$  ( $39 \pm 1.5 \mu\text{Sv}/\text{mCi}/\text{hr}$ ) or  $3.25 \mu\text{Sv}$  for 5 min acquisition times.

**Conclusion:** Body outlining is feasible with Tc-99m filled flood source. To assure high quality, at least 1 mCi of Tc-99m pertechnetate should be used for filling the source. This technique can be very useful especially when Co-57 is not available or has decayed. The need to prepare the flood source for each patient and difficulty in handling the source especially for the lateral views are the major limitations.

**Keywords:** Sentinel node, Tc-99m-Antimony sulfide colloid, Lymphoscintigraphy, Body outlining, Flood source

Iran J Nucl Med 2011;19(1):59-63

**Corresponding author:** Dr Ramin Sadeghi, Nuclear Medicine Research Center, Imam Reza Hospital, Mashhad University of Medical Sciences, Ebn Sina Street, Mashhad, Iran.  
E-mail: sadeghir@mums.ac.ir

## INTRODUCTION

Sentinel node biopsy is considered as the standard procedure for regional lymph node staging in many malignancies including breast cancer patients (1). This procedure is usually performed using radiotracers, blue dyes or both (2). It is usually recommended to perform lymphoscintigraphy after injection of the radiotracer in order to have a map for surgery which can help surgeons considerably (3). However, lymphoscintigraphy alone do not show any anatomical detail or location of the sentinel node(s) which are of utmost importance for surgeons. There are several methods to overcome this problem including: skin pen marking (4), IV injection of another tracer (5, 6), manual outlining of the body using point source of the Tc-99m (7), scatterogram using scattered photons of the injected tracer itself (8), and transmission imaging using Co-57 or Gd-153 sources (9, 10). The last method is the most common in daily medical practice.

In Iran, Co-57 or Gd-153 is not easily available and most nuclear medicine departments are not equipped with these sources. In the current study, we evaluated the feasibility of body outlining using Tc-99m filled flood source for lymphoscintigraphy of breast cancer patients.

## METHODS

During the period of Sep 2008 to March 2009, 80 patients with early stage (with no evidence of axillary involvement) breast cancer were sent to our department for lymphoscintigraphy. Tc-99m antimony sulfide colloid was used for sentinel node mapping of these patients.

The technique of the sentinel node mapping has been described elsewhere (1, 3). In brief: 0.5mCi or 1mCi/0.2mL (for 1-day and 2-day protocols respectively) of the tracer was

injected into the peri-areolar area of the index quadrant intradermally.

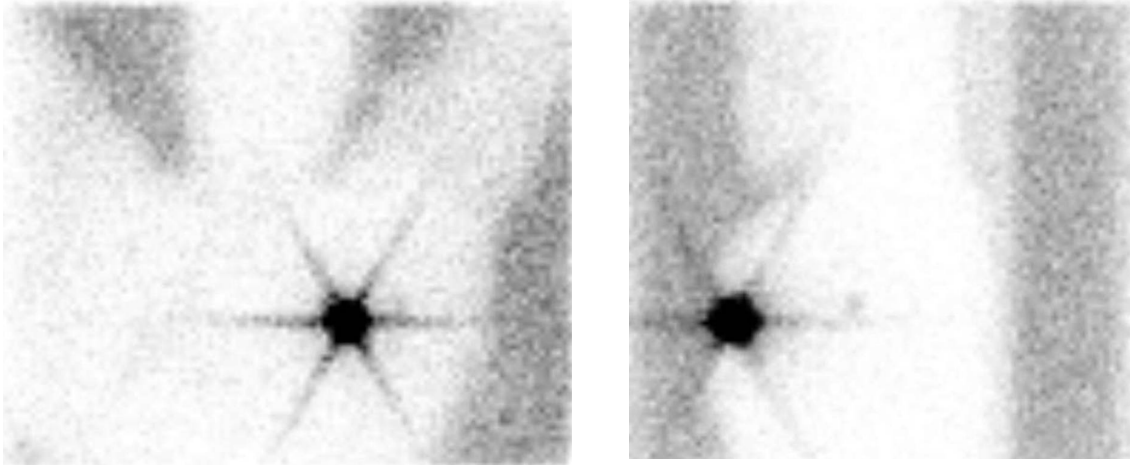
Anterior and lateral spot views were obtained immediately after the injection (5min/image, 128×128 matrix) using a single head gamma camera (SOPHA), equipped with a parallel hole low energy high resolution (LEHR) collimator.

For outlining the body a Tc-99m filled flood source was used which was located behind or lateral to the patients for anterior and lateral images respectively. The flood source was filled with 0.5 mCi, 1 mCi, 2 mCi, and 5 mCi for 10, 47, 10, and 3 patients respectively. The quality of outline images was assessed by two nuclear medicine specialists independently using a semi-quantitative method by the scale of good, intermediate, and poor qualities. Any discrepancy was resolved by consensus opinion of the two specialists.

Two flood phantoms were used to measured patients' dose from the flood source during lymphoscintigraphy. One phantom was considered as a source and other as the simulated patient. The thermoluminescent dosimeter (TLD-100) was used to measure patients' dose. Six TLDs were embedded on the surface of patient phantom. The patient phantom was placed 2 cm away from the source phantom. The three cm equivalent soft tissue was placed on the back of patient phantom to provide full backscatter condition. The activity in the source phantom at the time of acquisition was 370 MBq (10 mCi). The measurement was performed for one hour.

Sentinel node mapping was done using both gamma probe (RMD navigator GPS system) as well as blue dye technique (patent blue V) during surgery.

The decision to perform axillary lymph node dissection was based on the frozen section results of harvested sentinel lymph nodes. For patients with sentinel node detection failure during surgery, axillary lymph node dissection was also performed.



**Fig 1:** ANT and LAT lymphoscintigraphic views of a patients using 1 mCi filled Tc-99m flood source for body outlining.

## RESULTS

Overall 80 patients included in the study. Sentinel node could be detected on the lymphoscintigraphy images in 74 patients. Lymphatic mapping was successful in 78 patients during surgery. The quality of body contour images were good in images taken by 1, 2, and 5 mCi filled flood source (Figure 1). However the quality of images was poor in 8 out of 10 lymphoscintigraphies taken by 0.5 mCi filled flood source.

The measured dose rate from the Tc-99m flood source was  $1.07 \pm 0.04 \mu\text{Sv}/\text{MBq}/\text{hr}$  ( $39 \pm 1.5 \mu\text{Sv}/\text{mCi}/\text{hr}$ ). The estimated dose to the patient from the 37-MBq (1-mCi) Tc-99m flood source was about  $3.25 \mu\text{Sv}$  for 5 min acquisition times.

## DISCUSSION

Providing a body outline to the surgeons during lymphatic mapping can help them for better surgical planning and is recommended by many authors (11). Unfortunately in our country due to inaccessibility of flood sources, this important part of

lymphoscintigraphy imaging is usually omitted which is not clinically justified.

Skin pen marking is also used by many to localize the sentinel node before surgery however this method is not that accurate and can be very difficult due to little space between the patients and gamma camera (4).

As mentioned above, several methods can be used to outline the body during lymphoscintigraphy. All these methods have their benefits as well as drawbacks.

Injection of a small dose of Tc-99m-Pertechnetate was used by some for body outlining however this method imposes additional injection to the patients as well as additional radiation (6). Same as this technique Tatini et al used 24 hour images of bone scintigraphy for body outlining. However not all patients undergo bone scan the day before breast surgery (5).

Manual body outlining can be done with a point source of Tc-99m. However, the images by this method are of very low quality and imposes radiation burden to the personnel as well as patients (7).

Imaging the scattered photons (scatterogram) is also used for body outlining successfully without any

additional radiation to the patient or technologists. However, the images taken by this technique can be of low quality especially the parts of the body far from the injection site (8, 12-13).

The most common method for body outlining during lymphoscintigraphy is imaging with gamma emitting sources such as Co-57 or Gd-153 (9). Gd-153 line sources are basically used for attenuation correction in gamma cameras. They can also be used for body outlining during lymphoscintigraphy (7). Compared to the Co-57 sources, imaging with Gd-153 line sources are much easier especially for lateral views. The additional radiation to the patients is also much lower (7, 9).

However, not all nuclear medicine facilities have the Gd-153 or Co-57 sources. Co-57 sources will eventually decay and remain useless after couple of years and re-obtaining would be very expensive. This is a major financial burden not only in Iran but also in many developed countries (9). To overcome this problem, Krynycky et al. reported an unusual method of "activity background painting" by moving a 10 mL syringe behind the patients parallel to the collimator. This methods needs considerable skill and the images might show some irregularities (9).

In the current study, we evaluated the feasibility of body outlining by Tc-99m filled flood source. The quality of images was acceptable using 1, 2, and 5 mCi flood sources. However filling the flood source with 0.5 mCi was not satisfactory, which shows that the minimum acceptable dose is 1 mCi.

We also evaluated the radiation dose to the patients. The radiation was estimated to be 3.25  $\mu$ Sv for a 5 min imaging from the patients. According to Mar et al for Co-57 source (using 3.41 mCi as recommended by the authors for the best imaging results); radiation exposure would be 8.7  $\mu$ Sv for a unilateral 3 min imaging (14). This means less than a half radiation exposure by Tc-

99m flood source imaging despite longer exposure time.

The problem of imaging lateral views is the same as Co-57 sources. We placed the flood source on a chair lateral to the patient to be able to perform the lateral views as recommended by Krynycky et al for Co-57 sources (9). However, carrying around the heavy flood source is very cumbersome for the personnel (7).

Another important limitation is the short half-life of Tc-99m. Due to this fact, the flood source should be prepared for every patient. This causes additional radiation to the personnel and increases the chance of contamination.

It is worth mentioning that the flood source should not be filled completely for body outlining imaging which is in contrast to the application of flood sources for uniformity assessment of the gamma cameras. Even large air bubbles would not cause any problem during body outlining if the location of air bubble could be adjusted outside the body limits of the patient (which was easily achieved for all patients in our study).

## CONCLUSION

Body outlining is feasible with Tc-99m filled flood source. To assure high quality, at least 1 mCi Tc-99m-pertechnetate should be used for filling the source. This technique can be very useful especially when Co-57 is not available or has decayed. The need to prepare the flood source for each patient and difficulty in handling the source especially for the lateral views are the major limitations of this method.

## Acknowledgments

This study was supported financially by Azad University of Medical Sciences, Mashhad, Iran.

## REFERENCES

1. Sadeghi R, Forghani MN, Memar B, Rajabi Mashhadi MT, Dabbagh Kakhki VR, Abdollahi A et al. How long the lymphoscintigraphy imaging should be continued for sentinel lymph node mapping? *Ann Nucl Med*. 2009 Aug;23(6):507-10.
2. Eftekhari M, Beiki D, Fallahi B, Arabi M, Memari F, Gholamrezanezhad A, et al. Assessment the diagnostic accuracy of sentinel lymph nodes lymphoscintigraphy using Technetium-99m phytate in breast cancer. *DARU*. 2009;17:83-7.
3. Abdollahi A, Jangjoo A, Dabbagh Kakhki VR, Rasoul Zakavi S, Memar B, Naser Forghani M et al. Factors affecting sentinel lymph node detection failure in breast cancer patients using intradermal injection of the tracer. *Rev Esp Med Nucl*. 2010 Mar-Apr;29(2):73-7.
4. Sadeghi R, Forghani MN, Zakavi SR, Jangjoo A, Shabani GA, Dabbagh Kakhki VR. The Need for skin pen marking for sentinel lymph node biopsy:A comparative study. *Iran J Nucl Med*. 2008;16:23-7.
5. Tatini VR, Dworkin HJ. Fusion lymphoscintigraphy with a 24-hour Tc-99m MDP bone scan for sentinel lymph node detection and imaging. *Clin Nucl Med*. 2001 Jan;26(1):53.
6. Klutmann S, Bohuslavizki KH, Höft S, Kröger S, Brenner W, Tinnemeyer S et al. Lymphoscintigraphy with double tracer technique in carcinomas of the head-neck region. *Laryngorhinootologie*. 1997 Dec;76(12):740-4.
7. Clarke E, Notghi A, Harding K. Improved body-outline imaging technique for localization of sentinel lymph nodes in breast surgery. *J Nucl Med*. 2002 Sep;43(9):1181-3.
8. Momennezhad M, Zakavi SR, Dabbagh Kakhki VR, Jangjoo A, Ghavamnasiri MR, Sadeghi R. Scatterogram: A method for outlining the body during lymphoscintigraphy without using external flood source. *Radiol Oncol*. 2011;45(3):184-8.
9. Krynycky BR, Kim CK, Goyenechea M, Machac J. Methods to outline the patient during lymphoscintigraphy. *J Nucl Med*. 2003 Jun;44(6):992.
10. Krynycky BR, Sata S, Zolty I, Kim CK, Knesaurek K. Reducing exposure from <sup>57</sup>Co sources during breast lymphoscintigraphy by optimizing energy windows and other suggested enhancements of acquisition and the display of images. *J Nucl Med Technol*. 2004 Dec;32(4):198-205.
11. Krynycky BR, Shafir MK, Kim SC, Kim DW, Travis A, Moadel RM et al. Lymphoscintigraphy and triangulated body marking for morbidity reduction during sentinel node biopsy in breast cancer. *Int Semin Surg Oncol*. 2005 Nov 8;2:25.
12. Fujii H, Yamashita H, Nakahara T, Ikeda T, Kitagawa Y, Iwasaki R et al. Outlining the body contours with scattered photons in lymphoscintigraphy for sentinel nodes. *Ann Nucl Med*. 2000 Oct;14(5):401-4.
13. Fujii H, Ikeda T, Jinno H, Kitagawa Y, Yamashita H, Seki S et al. Lymphoscintigraphy for the visualization of sentinel lymph nodes and body contour. *Breast Breast Cancer*. 2004;11(3):250-5.
14. Mar MV, Dickinson RL, Erwin WD, Wendt RE 3rd. Optimal (<sup>57</sup>Co) flood source activity and acquisition time for lymphoscintigraphy localization images. *J Nucl Med Technol*. 2008 Jun;36(2):82-7.